

# Modified Mandibular Inferior Border Sagittal Split Osteotomy Reduces Postoperative Risk for Developing Inferior Border Defects



*Jimoh Olubanwo Agbaje, BDS, DMD, MMI, PhD,\* Bert Gemels, MD, DDS,†  
Ahmed S. Salem, BDS, MSc, PhD,‡ Dickson Anumendem, MSc, PhD,§  
Luc Vrielinck, DDS, MD,|| and Constantinus Politis, MD, DDS, MHA, MM, PhD¶*

**Purpose:** The purpose of this study was to evaluate the impact of a modified sagittal split osteotomy (SSO) surgical technique on the incidence of persisting inferior border defects. The secondary aim was to identify risk factors associated with the development of these complications.

**Materials and Methods:** The patient charts and radiographs of 276 consecutive patients who underwent bilateral SSO, performed by a single surgeon in 2 different centers from July 2012 to September 2014, were retrospectively examined. The predictor variable was length of advancement. The outcome variable was the presence or absence of an inferior border defect. Other variables included age and side of the jaw. In all cases the same surgical technique was used. All statistical analyses were performed using SAS software, version 9.4 (SAS Institute, Cary, NC).

**Results:** The analysis included 408 operation sites in 204 patients (132 female and 72 male patients; median age, 22 years; age range, 13 to 66 years). In 5.1% of operation sites an osseous defect at the lower border of the mandible was observed. Age at the time of surgery ( $P < .0001$ ) and length of advancement ( $P = .0111$ ) were identified as risk factors for the development of a persisting osseous defect at the inferior border of the osteotomy gap after SSO.

**Conclusions:** This study confirms the findings previously reported by our research group that the modified inferior border osteotomy technique in SSO results in a substantial lower frequency of persisting inferior border defects. Surgeons are advised to ensure that the lingual cortex of the inferior border is not included in the split during mandibular advancements, and in cases in which the advancement is more than 10 mm and/or the patient is older than 30 years, surgeons might want to consider using a bone graft or a bone graft substitute.

---

\*Postdoctoral Fellow, OMFS-IMPATh Research Group, Department of Imaging and Pathology, Faculty of Medicine, Catholic University of Leuven, Leuven, Belgium.

†Resident Doctor, OMFS-IMPATh Research Group, Department of Imaging and Pathology, Faculty of Medicine, Catholic University of Leuven, Leuven, Belgium.

‡Visiting Researcher, OMFS-IMPATh Research Group, Department of Imaging and Pathology, Faculty of Medicine, Catholic University of Leuven, Leuven, Belgium; and Oral and Maxillofacial Surgery Department, Faculty of Dentistry, Mansoura University, Mansoura, Egypt.

§Statistician, Centre for Educational Effectiveness and Evaluation, Catholic University of Leuven, Leuven, Belgium.

||Head of Oral and Maxillofacial Surgery Department, St John's Hospital, Genk, Belgium.

¶Professor and Head of Department Oral and Maxillofacial Surgery, OMFS-IMPATh Research Group, Department of Imaging and Pathology, Faculty of Medicine, Catholic University of Leuven,

Leuven, Belgium; and Faculty of Medicine, Hasselt University, Diepenbeek, Belgium.

Jimoh Olubanwo Agbaje is a postdoctoral researcher supported by the Fund for Scientific Research (FWO-Vlaanderen).

Address correspondence and reprint requests to Dr Agbaje: OMFS-IMPATh Research Group, Department of Imaging and Pathology, Faculty of Medicine, Catholic University of Leuven, Kapucijnenvoer 33, 3000 Leuven, Belgium; e-mail: [joagbaje@gmail.com](mailto:joagbaje@gmail.com)

Received October 19 2015

Accepted January 4 2016

© 2016 The Authors. Published by Elsevier Inc. on behalf of American Association of Oral and Maxillofacial Surgeons. This is an open access article under the CC BY-NC-ND license (<http://creativecommons.org/licenses/by-nc-nd/4.0/>).

0278-2391/16/00019-7

<http://dx.doi.org/10.1016/j.joms.2016.01.005>

© 2016 The Authors. Published by Elsevier Inc. on behalf of American Association of Oral and Maxillofacial Surgeons. This is an open access article under the CC BY-NC-ND license (<http://creativecommons.org/licenses/by-nc-nd/4.0/>).

*J Oral Maxillofac Surg* 74:1062.e1-1062.e9, 2016

Sagittal split osteotomy (SSO) of the mandible is a successful technique and one of the most commonly used techniques in orthognathic surgery. Since its introduction almost 6 decades ago by Trauner and Obwegeser,<sup>1</sup> several modifications of the original technique have been reported,<sup>2</sup> such as those of Dal Pont,<sup>3</sup> Hunsuck,<sup>4</sup> Epker,<sup>5</sup> and Wolford and Davis.<sup>6</sup> These modifications have reduced the frequency of perioperative and postoperative complications and improved the stability and success of the postsurgical outcome.<sup>7</sup> Nonetheless, various complications are still associated with SSO.<sup>8-15</sup>

The most common and widely reported complications of SSO are postoperative neurosensory disturbances of the inferior alveolar nerve, such as persisting anesthesia, hyperesthesia, or allodynia. Neuropathic pain resulting from nerve damage can be the cause of considerable morbidity in patients.<sup>14,15</sup> Given the elective nature of SSO, utmost care should be taken to minimize the frequency of complications.

Another complication after SSO, which is less debilitating but a cause of dissatisfaction among patients, is a persisting osseous defect at the inferior border of the mandible. A previous report from our group showed that this complication is present in more than one-third of the operation sites if the full mandibular inferior border is included during the inferior border cut.<sup>16</sup> Given the fact that a visible and palpable gap can be a reason for patient dissatisfaction and secondary surgical correction, precautions should be taken to reduce the risk of a postoperative mandibular defect after bilateral SSO.

The main purpose of this study was to evaluate the effect of a modified SSO surgical technique (Trauner-Obwegeser SSO with the Hunsuck-Epker technique and a modification of the inferior border osteotomy) on the incidence of persisting inferior border defects in the mandible after SSO. The secondary aim was to identify the risk factors associated with the development of these complications when the modified SSO technique was used.

## Materials and Methods

### STUDY DESIGN

A retrospective study design was implemented. The study included patients who underwent bilateral SSO at St John's Hospital in Genk, Belgium, from July 2012 to March 2013 and patients who underwent the same procedure at the University Hospital of Leuven (UZ Leuven) in Leuven, Belgium, from January

2013 to September 2014. The inclusion criteria were patients requiring the correction of mandibular retrognathism with correction consisting of symmetrical or asymmetrical mandibular advancements. The study was approved by the ethical committee of the Catholic University of Leuven and UZ Leuven (S55873).

### STUDY VARIABLES

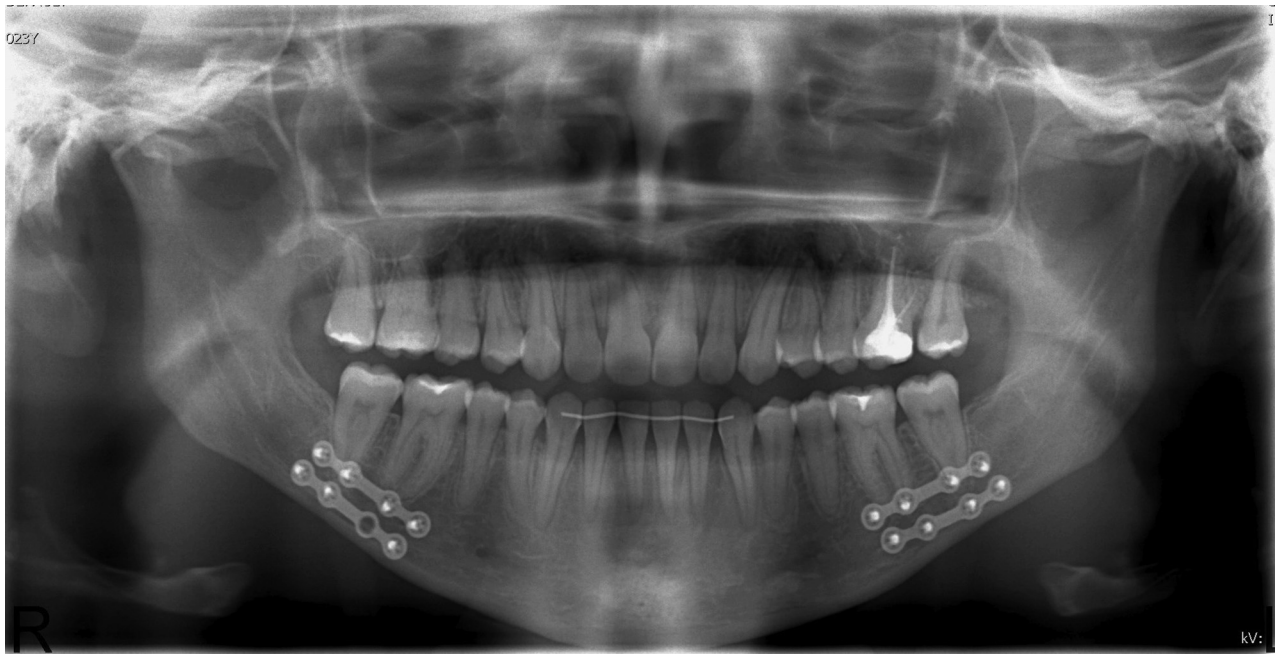To assess the frequency of inferior border defects after SSO surgery and to identify the associated risk factors for these complications, we used a set of predictor variables comparable to those described in the previous study by our group.<sup>16</sup> The radiographic variable was the magnitude of advancement during SSO, measured (in millimeters) on panoramic radiographs taken 1 week after surgery. The other variables were age (in years), gender (female or male), and side of the jaw (left or right). The primary outcome measure was the radiographic absence (Fig 1) or presence (Fig 2) of an inferior border defect. In addition, patient operative charts were studied for any information on the occurrence of an unfavorable split during osteotomy.

### MODIFIED MANDIBULAR INFERIOR BORDER OSTEOTOMY TECHNIQUE

The sagittal osteotomy of the inferior border is executed with a standard Mectron Piezosurgery insert (OT7; Mectron, Carasco, Italy). After completion of the vertical cut through the outer cortex of the mandible at the level somewhere between the first and second molar, a bevel is made—with a round drill—medial to the vertical cut at the inferior border of the mandible to allow the placement of the Piezosurgery insert as parallel to the inferior border as possible. The Piezosurgery insert is placed against the bevel and is gently driven into the inferior border with the purpose to divide the inferior border into a lingual side and a buccal side. Care needs to be taken not to drive the tip too lingually. The tip is inserted until the first black dot disappears in the bone, which is at a depth of about 7 to 10 mm. This allows the initiation of an inferior border split in which the lingual border at the gap remains in the tooth-bearing fragment, whereas the buccal side of the inferior border remains part of the buccal fragment (proximal segment), avoiding the emergence of an unfavorable split.

### DATA COLLECTION

During the preoperative examination and postoperative follow-up appointments (1 week, 6 weeks,

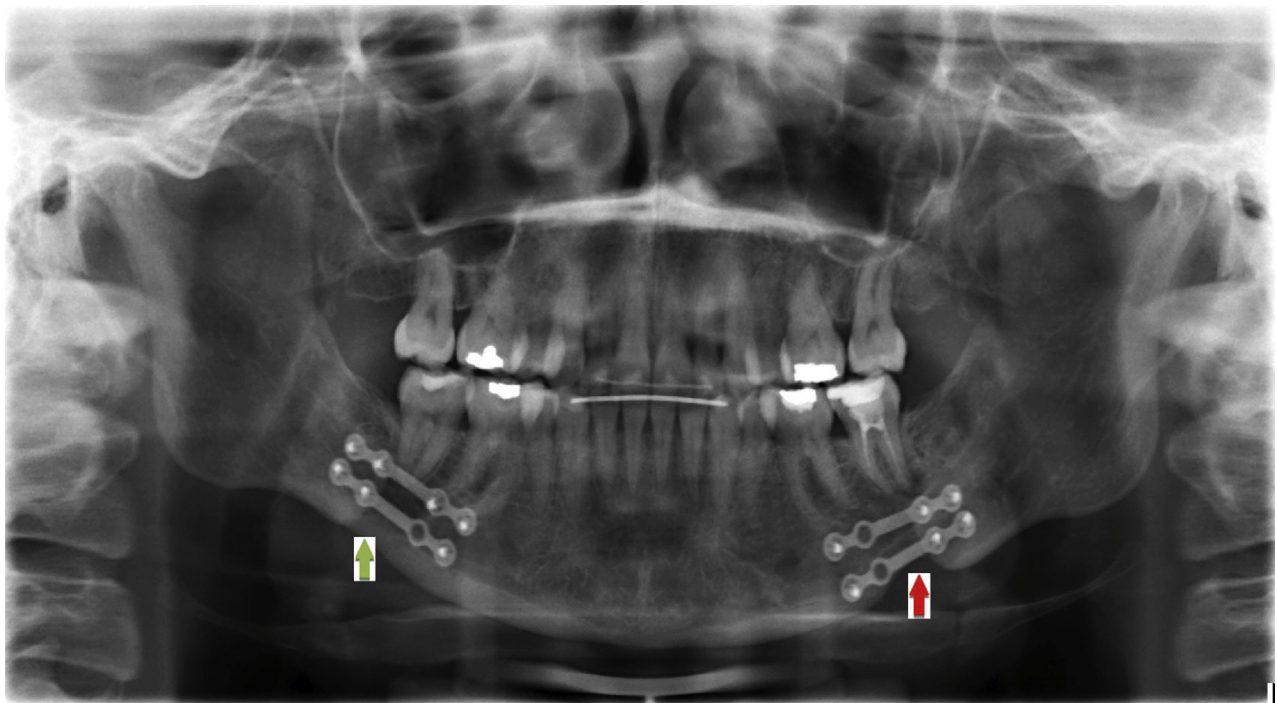


**FIGURE 1.** A panoramic image of the mandible 1 year after bilateral sagittal split osteotomy shows no defect in the mandibular inferior border.

*Agbaje et al. Inferior Border Defects. J Oral Maxillofac Surg 2016.*

6 months, 1 year), panoramic radiographs were taken for all patients. At St John's Hospital, the radiographs were acquired as described in detail by Agbaje et al<sup>16</sup> using the Orthophos XG Plus scanner (Sirona Dental

Systems, Bensheim, Germany) and Sidexis software package (Sirona Dental Systems). At UZ Leuven, a similar scanning protocol was used with the Dürr VistaPano (Dürr Dental, Bietigheim-Bissingen, Germany)



**FIGURE 2.** A panoramic image of the mandible 1 year after the operation shows a defect (*red arrow*) on the left side of the mandibular inferior border. On the right side, there are signs of delayed healing; the continuity of the cortical lining, however, remains intact (*green arrow*).

*Agbaje et al. Inferior Border Defects. J Oral Maxillofac Surg 2016.*



or Planmeca ProMax 3-dimensional scanner (Planmeca Oy, Helsinki, Finland) and the IMPAX 6.0 software package (Agfa Healthcare, Mortsels, Belgium).

#### ASSESSMENT OF MAGNITUDE OF ADVANCEMENT DURING SSO ON ORTHOPANTOGRAPHS

The advancement achieved for all 454 operation sites (227 patients) during SSO was determined from linear measurements made on the panoramic radiographs taken 1 week postoperatively.<sup>16</sup> On each operation site, the magnitude of advancement, as well as the length of the inferior miniplate, was measured using the automatic measurement tool in the Sidexis (St John's Hospital) or IMPAX 6.0 (UZ Leuven) software package (Fig 3). The length of the miniplate on the panoramic radiograph was adapted to the original known length.<sup>16</sup> This allowed conversion of the unequal magnification and geometrical distortion of measured advancement on panoramic images to the actual length of advancement. By use of the Sidexis software, the measured advancement was automatically adapted. At UZ Leuven, the measurements were converted by entering the known variables (length of osteosynthesis plate) into an Excel file (Microsoft, Redmond, WA).

#### ASSESSMENT OF MANDIBULAR INFERIOR BORDER DEFECTS AND ANALYSIS

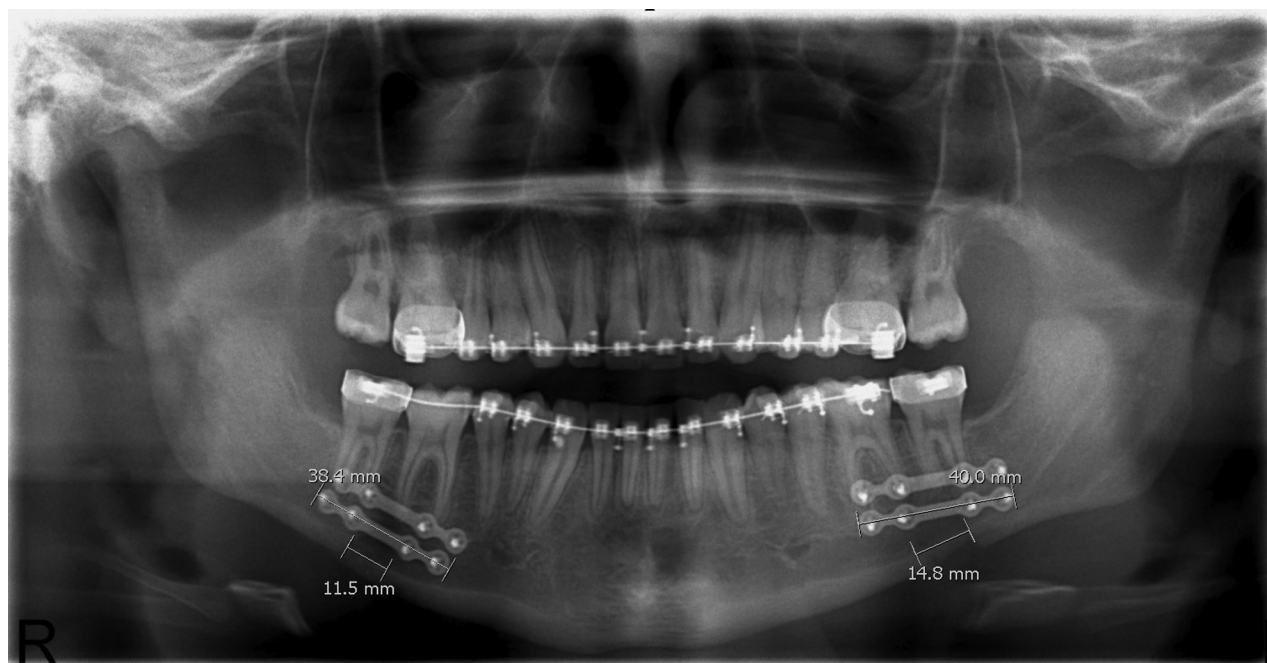The presence or absence of an inferior border defect on each operation site was assessed from the pano-

ramic radiograph taken during the last follow-up appointment (6 months or 1 year). Only those lesions with a well-defined cortical discontinuation were withheld as inferior border defects (Fig 2, red arrow). The radiograph interpretation was performed by 2 independent investigators with good knowledge of oral imaging (J.O.A and B.G.). In the case of disagreement, a final conclusion was reached by consensus agreement between these investigators. Inferior border irregularities (notch, decreased cortical width, and so on) or increased radiolucency without cortical discontinuation (Fig 2, green arrow) was not considered pathologic in the absence of subjective complaints. All pathologic and ambiguous cases were discussed with a second investigator (J.O.A) before inclusion. The surgeon who operated on the cases did not participate in the analysis of radiographs.

All measurements and other variables (age at time of surgery, gender, side of jaw, and use of bone grafts or bone graft substitutes) were entered into an Excel file (Microsoft).

#### STATISTICAL ANALYSIS

All statistical analyses were performed using SAS statistical software (version 9.4; SAS Institute, Cary, NC). Categorical and continuous variables were described using descriptive statistics. Nominal variables (gender, operation sites, movement, detachment, genioplasty, and so on) were summarized using counts and percentages. The number of observations, mean, standard



**FIGURE 3.** Panoramic image of the mandible showing measured linear distances.

deviation, median, interquartile range, and range were used to describe the continuous variables.

The relation between the different variables (age in years at surgery, gender, side of jaw [left vs right], and length of advancement) and the presence of an osseous defect at the last follow-up appointment was determined by univariate and multivariate analyses using a generalized linear model. A generalized linear model (logistic) with a generalized estimating equation was used to estimate the parameters while the correlation between the outcomes on both sides for each patient was taken into account.

Significance was defined as  $P < .05$ . Odds ratios and 95% confidence intervals were determined.

## Results

### SAMPLE DESCRIPTION

Of the original population, 23 patients were lost to follow-up; therefore, the analysis included 204 patients (132 female and 72 male patients), with 408 operation sites, with a mean age of 26.9 years (SD, 12.62 years; median, 22 years; range, 13 to 66 years). An inferior border defect was observed in 5.1% of operation sites (21 operation sites, with 16 in female and 5 in male patients) on postoperative panoramic radiographs taken during the last follow-up consultation. [Table 1](#) summarizes the proportion of defects for the categorical variables gender and side. The continuous variables (age in years and measured length of advancement), grouped by the status of the mandibular inferior border (presence or absence of defect), are reported in [Table 2](#). Mean (39.6 years vs 26.3 years and 10.7 mm vs 9.1 mm) and median (41 years vs 21 years and 9.8 mm vs 9.2 mm) values were higher in patients with a defect than in those without. Two unfavorable sagittal splits occurred during the SSO among the 408 operating sites; both were managed perioperatively. Bone fragments were stabilized using plate osteosynthesis. There was no need

for specific additional measures, such as rigid inter-maxillary fixation or a prolonged hospital stay.

### CORRELATION AND REGRESSION STATISTICS

The estimated odds ratios and 95% confidence intervals for the univariate logistic regression analysis of the risk factors for the presence of an inferior border defect are presented in [Table 3](#). Age at the time of surgery ( $P < .0001$ ) and length of advancement ( $P = .0055$ ) significantly increased the likelihood of the presence of a defect in the mandible ( $P \leq .05$ ). The effects of gender ( $P = .28$ ) and side ( $P = .44$ ) on the probability of a postoperative defect were insignificant.

The results of the multivariate logistic generalized estimating equation model are presented in [Table 4](#). Two variables were important in predicting whether there would be a postoperative defect: age ( $P < .0001$ ) and length of advancement ( $P = .0111$ ). The effects of side of the jaw (left vs right,  $P = .48$ ) and gender (female vs male,  $P = .69$ ) were not statistically significant.

## Discussion

Evaluating the impact of the modified inferior border osteotomy technique on the frequency of a common postoperative complication was the main objective of this study. Wolford et al<sup>17</sup> (1987) stressed the importance of including the lingual cortex in the buccal osteotomy fragment to avoid unfavorable splits. This, however, leads to a significant number of inferior border defects, as has been shown in our previous report.

The later introduction of the technique of splitting the inferior border by Wolford and Davis<sup>6</sup> (1990) showed the importance of maintaining the lingual cortex of the inferior border with the distal segment during the inferior border osteotomy. They performed the inferior border osteotomy with a specially designed reciprocating inferior border saw blade.

On the basis of previous studies,<sup>16,18-20</sup> we hypothesized that implementing the modified SSO technique ([Figs 4-8](#)) would reduce the incidence of persisting inferior border defects. A secondary objective was to identify the risk factors associated with the development of these complications.

In this study an inferior border defect was observed in approximately 5% of operation sites. This finding agrees with our previous study,<sup>16</sup> in which we found a substantial lower frequency (inferior border defects in about 20% of operation sites) 1 year postoperatively when the surgeon ensured that the lingual part of the inferior border remained attached to the mandibular body to avoid unfavorable splits, as compared with a significant number of inferior border defects (inferior border defects in >80% of operation sites) seen with

**Table 1. SUMMARY STATISTICS FOR CATEGORICAL VARIABLES**

Parameter	Proportion of Defects	
	No Defect	Defect
All patients	387 of 408 (94.9%)	21 of 408 (5.1%)
Gender		
Female	248 of 264 (93.9%)	16 of 264 (6.1%)
Male	139 of 144 (96.5%)	5 of 144 (3.5%)
Side		
Left	192 of 204 (94.1%)	12 of 204 (5.9%)
Right	195 of 204 (95.6%)	9 of 204 (4.4%)

**Table 2. SUMMARY STATISTICS FOR CONTINUOUS VARIABLES**

Parameter	Defect Status	SE	Mean (SD)	Range	Median (Q1, Q3)	CI
Age, yr	Defect (n = 21)	2.94	39.6 (13.49)	15-66	41 (36, 50)	33.48-45.76
	No defect (n = 385)	0.62	26.3 (12.21)	13-66	21 (17, 34)	25.05-27.5
Advancement, mm	Defect (n = 21)	0.61	10.7 (2.8)	6-18.1	9.9 (8.7, 12.3)	9.41-11.97
	No defect (n = 383)	0.13	9.1 (2.51)	2.7-17.1	9.2 (7.4, 10.5)	8.82-9.33

*Note:* The continuous variables (age and measured length of advancement), grouped by the status of the mandibular lower border (presence or absence of defect), are shown. Mean (39.6 years vs 26.3 years and 10.7 mm vs 9.1 mm) and median (41 years vs 21 years and 9.8 mm vs 9.2 mm) values were higher in patients with a defect than in those without.

Abbreviations: CI, confidence interval; n, number of observations with a response; Q1, quartile 1; Q3, quartile 3; SE, standard error of mean.

*Agbaje et al. Inferior Border Defects. J Oral Maxillofac Surg 2016.*

the old technique, which included the full thickness of the inferior border in the proximal fragment. Our current findings suggest an over 93% reduction in the complication rate of the development of inferior border defects when the modified osteotomy technique is implemented.

Bone healing is a complex biological process<sup>21,22</sup> influenced by various local and systemic variables.<sup>23</sup> Identification and evaluation of these (perioperative) variables may contribute to a better understanding of the risk factors associated with the development of a permanent osseous defect at the inferior border of the mandible after SSO. In this study the relation between the variables age at the time of surgery, length of advancement, gender, and side of the jaw and the presence of an inferior border defect was assessed, following the hypothesis that the nature of this complication is multifactorial.

Age at the time of surgery seemed to have a significant role in the development of a postoperative osseous defect in our patient population: Patients without defects were strikingly younger than those with defects (median age of 21 years and 41 years, respectively). Both univariate and multiple logistic regression analyses statistically confirmed this assumption, showing a significant association ( $P < .0001$ )

between age and the frequency of inferior border defects. This finding is in accordance with the literature, in which several authors reported faster healing and fewer associated complications in younger age groups.<sup>23,24</sup> The underlying mechanism is not well understood, although an effect of age on the vascularization during bone repair is suspected.<sup>25</sup>

The influence of the magnitude of advancement on the frequency of inferior border defects is presented in [Table 2](#). Patients without an inferior border defect showed a mean length of advancement of 9.1 mm, whereas in patients with a defect, a mean advancement of 10.7 mm was measured. By use of univariate and multivariate logistic regression analyses, statistically significant associations ( $P = .0055$  and  $P = .0111$ , respectively) between this variable and the development of a mandibular defect were shown. The literature supports this finding, indicating that larger defects not only require a longer healing time (indirectly increasing the risk of postsurgical complications, eg, by retraction of the soft tissues in the gap), but also directly increase the likelihood of postoperative complications.<sup>16,26-28</sup>

Our data could not confirm our previous findings regarding the role of the side of the jaw in predicting the probability of having a defect.<sup>16</sup> Although a minor numerical difference between the left side (12 of 204) and right side (9 of 204) was present, no statistically

**Table 3. ORS OBTAINED WITH SIMPLE LOGISTIC REGRESSION MODEL OF EACH FACTOR**

Parameter	OR	95% CI	P Value
Age	1.0709	1.04-1.1	<.0001
Advancement	1.2573	1.07-1.48	.0055
Gender (female vs male)	1.7935	0.63-5.14	.2768
Side (left vs right)	1.3542	0.63-2.92	.4397

*Note:* The logistic model estimates the odds of having a defect compared with having no defect.

Abbreviations: CI, confidence interval; OR, odds ratio.

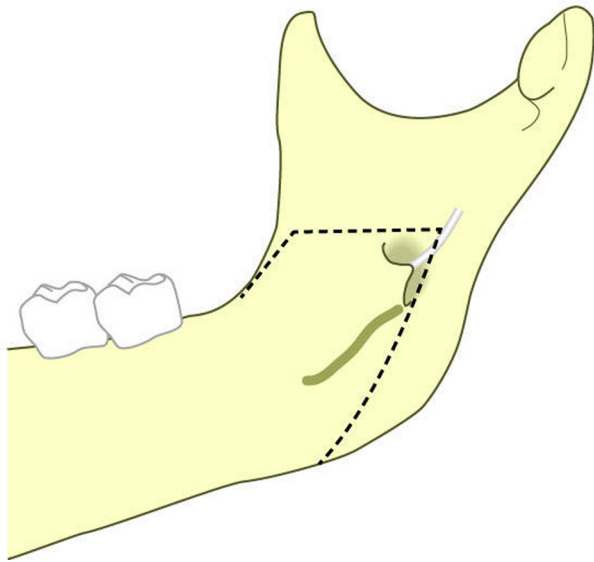
*Agbaje et al. Inferior Border Defects. J Oral Maxillofac Surg 2016.*

**Table 4. ORS OBTAINED WITH MULTIPLE LOGISTIC REGRESSION MODEL**

Parameter	OR	95% CI	P Value
Age	1.0724	1.04-1.11	<.0001
Advancement	1.2602	1.05-1.51	.0111
Gender (female vs male)	1.2393	0.44-3.52	.6874
Side (left vs right)	1.3589	0.58-3.17	.4780

Abbreviations: CI, confidence interval; OR, odds ratio.

*Agbaje et al. Inferior Border Defects. J Oral Maxillofac Surg 2016.*

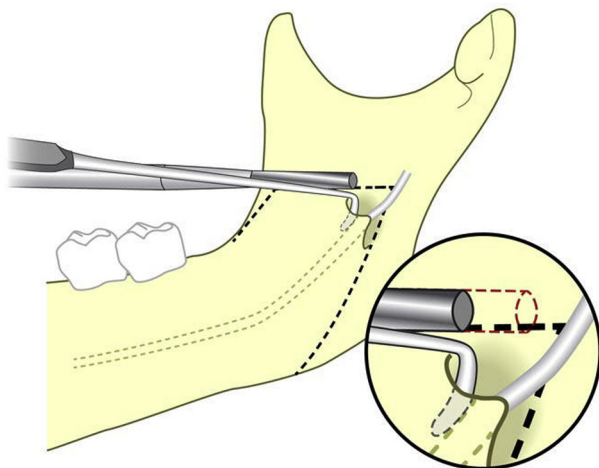


**FIGURE 4.** Buccal and lingual osteotomy technique: medial view of mandible. The horizontal dashed line shows the extent of the initial horizontal cut with the Hall burr (Sabra Dental Products; Deer Park, NY) in a sagittal split osteotomy.

*Agbaje et al. Inferior Border Defects. J Oral Maxillofac Surg 2016.*

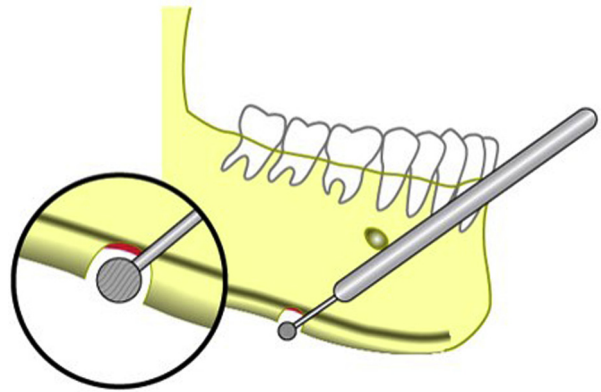
significant association between the side of the jaw and the frequency of inferior border defects was found. This finding might suggest that the inferior border osteotomy technique—as compared with the traditional technique—is less sensitive to differences in the surgeon’s performance when operating on both sides and/or to the possible difference between the left and right sides in the posterior rotation of the proximal fragment of the mandible during the placement of rigid fixation.

In accordance with the literature, no correlation between gender and compromised bone healing was found.<sup>16,23</sup>



**FIGURE 5.** Proper placement of a nerve hook in the anterior aspect of the mandibular canal. This placement prevents nerve damage due to drilling during an osteotomy cut.

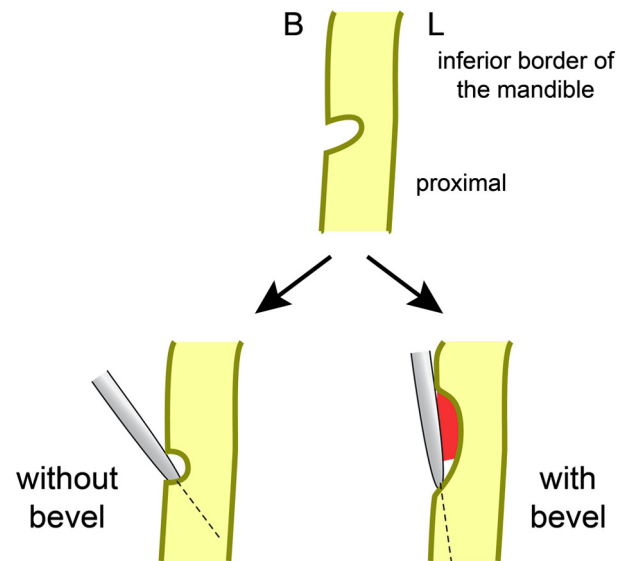
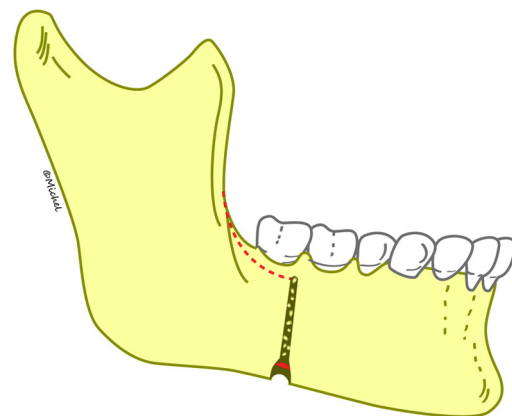
*Agbaje et al. Inferior Border Defects. J Oral Maxillofac Surg 2016.*



**FIGURE 6.** Lower border cut. It should be noted that the cut only goes through the partial thickness of the inferior border.

*Agbaje et al. Inferior Border Defects. J Oral Maxillofac Surg 2016.*

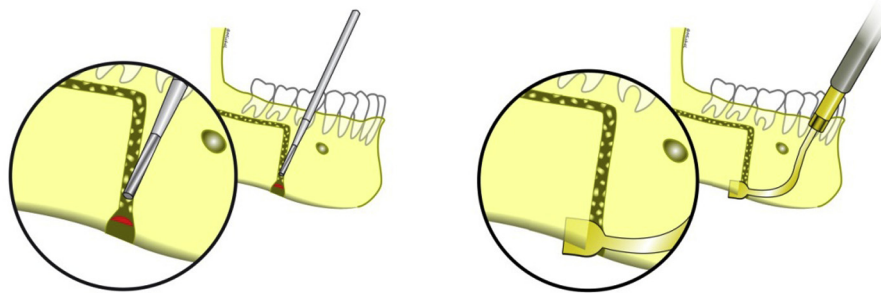
The aforementioned results lend support to our hypothesis that the development of inferior border defects is multifactorial in nature. Although, at present,



**FIGURE 7.** Purpose of bevel cut.

*Agbaje et al. Inferior Border Defects. J Oral Maxillofac Surg 2016.*





**FIGURE 8.** Vertical cortical bone cut of mandibular body. The position vestibular to the first molar should be noted. A piezoelectric ultrasonic device is used to make the lower border cut that divides the inferior border into a lingual fragment and a buccal fragment.

*Agbaje et al. Inferior Border Defects. J Oral Maxillofac Surg 2016.*

only 2 significantly contributing risk factors were identified, several more can be suspected to exert an influence on the frequency of postoperative defects.

Furthermore, the inferior border osteotomy technique used in this study group ensures no increase in the occurrence of bad splits. A bad split occurred in only 2 of 408 sites, which indicates that it is possible to avoid an unfavorable split while keeping the lingual cortex intact, if an inferior border split is initiated with the piezotome.

We realize that this study has several limitations, with the main weaknesses being its retrospective nature and the lack of inclusion of a control site (split-mouth study design). However, because the same surgeon operated on all patients in the former publication with the traditional technique and operated on all patients in this study with the modified inferior border osteotomy technique, comparisons are possible because the characteristics of the 2 study populations do not differ. Furthermore, a split-mouth design was deemed inapplicable because, in the previous study, a significant difference between the left and right sides was found.

During analysis of associated risk factors for impaired bone healing, several possible interesting variables were not taken into account, such as medical history (systemic conditions,<sup>29</sup> history of surgery or trauma, and so on), smoking status,<sup>23,30,31</sup> medication (eg, corticosteroids) and recreational drug use,<sup>23</sup> thickness of the lower border, presence of infection (requiring removal of the miniplates), and possibly others.

No comparison could be made between other fixation types of surgical approach because the same surgeon using the same surgical technique carried out all operations.

Our final remark concerns the use of panoramic images to calculate the magnitude of mandibular advancement. This approach contains 2 problems inherent to the radiologic technique. First, panoramic radiographs do not allow accurate linear measurements because of geometrical distortion and unequal

magnification. The use of a conversion factor, as was used during this study, reduces this error—especially when both sides are considered separately—however, the final measurement cannot be considered exact.<sup>32,33</sup> Second, using a 2-dimensional imaging technique ignores the fact that defects are 3-dimensional volumetric spaces. However, as stated by Agbaje et al,<sup>16</sup> because of regulations concerning patient safety and radiation exposure, routinely performing postoperative high-resolution cone-beam computed tomography of the osteotomy gap (allowing 3-dimensional measurement) could not be justified.

The modified inferior border osteotomy technique in SSO, which leaves the lingual part of the lower border attached to the body of the mandible, results in a significantly lower frequency of persisting lower border defects. By use of this technique, the age of the patient and the length of advancement remain important clinical predictors of whether there will be a postoperative defect. Gender and the side of the jaw, however, showed no statistically significant association with the development of this complication.

To prevent the development of postoperative inferior border defects, clinicians are advised to ensure that the lingual cortex of the inferior border remains intact with the distal segment of the mandible during mandibular advancements. In cases in which the advancement is more than 10 mm and/or the patient is older than 30 years, surgeons may consider using a bone graft, a bone graft substitute, or scaffolds to prevent the ingrowth of surrounding soft tissues, therefore decreasing the occurrence of postoperative defects. The occurrence of unfavorable splits is minimized if the inferior border split is initiated with the piezotome.

## References

1. Trauner R, Obwegeser H: The surgical correction of mandibular prognathism and retrognathia with consideration of genioplasty. I. Surgical procedures to correct mandibular prognathism and reshaping of the chin. *Oral Surg Oral Med Oral Pathol* 10:677, 1957



2. Bockmann R, Meyns J, Dik E, Kessler P: The modifications of the sagittal ramus split osteotomy: A literature review. *Plast Reconstr Surg Glob Open* 2:e271, 2014
3. Dal Pont G: Retro-molar osteotomy for correction of prognathism. *Minerva Chir* 14:1138, 1959 (in Italian).
4. Hunsuck EE: A modified intraoral sagittal splitting technic for correction of mandibular prognathism. *J Oral Surg* 26:250, 1968
5. Epker BN: Modifications in the sagittal osteotomy of the mandible. *J Oral Surg* 35:157, 1977
6. Wolford LM, Davis WM Jr: The mandibular inferior border split: A modification in the sagittal split osteotomy. *J Oral Maxillofac Surg* 48:92, 1990
7. Gil JN, Marin C, Claus JD, Lima SM Jr: Modified osteotome for inferior border sagittal split osteotomy. *J Oral Maxillofac Surg* 65:1840, 2007
8. Kim SG, Park SS: Incidence of complications and problems related to orthognathic surgery. *J Oral Maxillofac Surg* 65:2438, 2007
9. Falter B, Schepers S, Vrielinck L, et al: Occurrence of bad splits during sagittal split osteotomy. *Oral Surg Oral Med Oral Pathol Oral Radiol Endod* 110:430, 2010
10. Reyneke JP: Reoperative orthognathic surgery. *Oral Maxillofac Surg Clin North Am* 23:73, 2011
11. Politis C, Lambrichts I, Agbaje JO: Neuropathic pain after orthognathic surgery. *Oral Surg Oral Med Oral Pathol Oral Radiol* 117:e102, 2014
12. Politis C, Sun Y, Lambrichts I, et al: Self-reported hypoesthesia of the lower lip after sagittal split osteotomy. *Int J Oral Maxillofac Surg* 42:823, 2013
13. Panula K, Finne K, Oikarinen K: Incidence of complications and problems related to orthognathic surgery: A review of 655 patients. *J Oral Maxillofac Surg* 59:1128, 2001
14. Lee EG, Ryan FS, Shute J, Cunningham SJ: The impact of altered sensation affecting the lower lip after orthognathic treatment. *J Oral Maxillofac Surg* 69:e431, 2011
15. Agbaje JO, Salem AS, Lambrichts I, et al: Systematic review of the incidence of inferior alveolar nerve injury in bilateral sagittal split osteotomy and the assessment of neurosensory disturbances. *Int J Oral Maxillofac Surg* 44:447, 2015
16. Agbaje JO, Sun Y, Vrielinck L, et al: Risk factors for the development of lower border defects after bilateral sagittal split osteotomy. *J Oral Maxillofac Surg* 71:588, 2013
17. Wolford LM, Bennett MA, Rafferty CG: Modification of the mandibular ramus sagittal split osteotomy. *Oral Surg Oral Med Oral Pathol* 64:146, 1987
18. Falter B, Schepers S, Vrielinck L, et al: Plate removal following orthognathic surgery. *Oral Surg Oral Med Oral Pathol Oral Radiol* 112:737, 2011
19. Agbaje JO, Sun Y, Lambrichts I, et al: Safe surgical access to the mandibular nerve at the infratemporal fossae. *J Craniofac Surg* 25:1454, 2014
20. Politis C, Lambrichts I, Sun Y, et al: Attachment rate of the inferior alveolar nerve to buccal plate during bilateral sagittal split osteotomy influences self-reported sensory impairment. *J Craniofac Surg* 25:2121, 2014
21. Bab IA, Sela JJ: Cellular and molecular aspects of bone repair, *in* Principles of Bone Regeneration. New York, NY, Springer, 2012, pp 11–41
22. Marsell R, Einhorn TA: The biology of fracture healing. *Injury* 42:551, 2011
23. Gaston MS, Simpson AH: Inhibition of fracture healing. *J Bone Joint Surg Br* 89:1553, 2007
24. Gruber R, Koch H, Doll BA, et al: Fracture healing in the elderly patient. *Exp Gerontol* 41:1080, 2006
25. Lu C, Hansen E, Sapozhnikova A, et al: Effect of age on vascularization during fracture repair. *J Orthop Res* 26:1384, 2008
26. Claes L, Grass R, Schmickal T, et al: Monitoring and healing analysis of 100 tibial shaft fractures. *Langenbecks Arch Surg* 387:146, 2002
27. Verdugo F, Simonian K, D'Addona A, et al: Human bone repair after mandibular symphysis block harvesting: A clinical and tomographic study. *J Periodontol* 81:702, 2010
28. Claes L, Eckert-Hübner K, Augat P: The fracture gap size influences the local vascularization and tissue differentiation in callus healing. *Langenbecks Arch Surg* 388:316, 2003
29. Graves DT, Alblow J, Paglia DN, et al: Impact of diabetes on fracture healing. *J Exp Clin Med* 3:3, 2011
30. W-Dahl A, Toksvig-Larsen S: Cigarette smoking delays bone healing: A prospective study of 200 patients operated on by the hemicallosis technique. *Acta Orthop Scand* 75:347, 2004
31. Ma L, Zheng LW, Sham MH, Cheung LK: Effect of nicotine on gene expression of angiogenic and osteogenic factors in a rabbit model of bone regeneration. *J Oral Maxillofac Surg* 68:777, 2010
32. Chuenchompoonut V, Ida M, Honda E, et al: Accuracy of panoramic radiography in assessing the dimensions of radiolucent jaw lesions with distinct or indistinct borders. *Dentomaxillofac Radiol* 32:80, 2003
33. Nikneshan S, Sharafi M, Emadi N: Evaluation of the accuracy of linear and angular measurements on panoramic radiographs taken at different positions. *Imaging Sci Dent* 43:191, 2013