Made available by Hasselt University Library in https://documentserver.uhasselt.be

Some Examples of Supernumerary Anatomical Structures in Arm and Hand Associated with Genetic Conditions such as the Ellis-Van Creveld Syndrome

Peer-reviewed author version

VAN ZWIETEN, Koos Jaap; SCHMIDT, Klaus; Varzin, S.A.; Piskun, O.E. & ZOUBOVA, Irina (2017) Some Examples of Supernumerary Anatomical Structures in Arm and Hand Associated with Genetic Conditions such as the Ellis-Van Creveld Syndrome. In: Varzin, S.A.; Gromova, V.V.; Piskun, O.E.; Savchenko, U.V.; Semenova, T.V.; Tarasovskaya, O.Y.; Churilov, L.P.; Bondarchuk, I.L.; Vengerova, N.N.; Dyachenko, G.B.; Lyuyk, L.V.; Piskun, T.M. (Ed.). Proceedings of the XII Annual all-Russian research and practical conference with international participation "health – the base of human potential: problems and ways to solve them", Saint Petersburg State University, Peter the Great Saint Petersburg Polytechnic University,p. 676-682.

Handle: http://hdl.handle.net/1942/25738

Ministry of Education and Science of the Russian Federation
Ministry of Health of the Russian Federation
Peter's Academy of Arts and Sciences
Saint Petersburg Professional Association of the Medical Employees
Children's scientific clinical center of infectious diseases of Federal Medical Biological Agency
N.I. Vavilov Federal Research Centre All-Russia's Institute of Plant Genetic Resources
Agrophysical Research Institute
P.F. Lesgaft National State University of Physical Education, Sports and Health
A.I. Herzen Russian State Pedagogical University
Saint Petersburg Theological Academy of the Russian Orthodox Church
St Petersburg Academic University — Nanotechnology Research and Education Centre of the Russian Academy of Sciences
Saint Petersburg State University
Peter the Great Saint Petersburg Polytechnic University

XII

ANNUAL ALL–RUSSIAN RESEARCH AND PRACTICAL CONFERENCE WITH INTERNATIONAL PARTICIPATION

"HEALTH – THE BASE OF HUMAN POTENTIAL: PROBLEMS AND WAYS TO SOLVE THEM"

Proceedings of the Conference

Volume 12, part 2.

23h – 25th November, 2017

Saint Petersburg
2017

Здоровье — основа человеческого потенциала: проблемы и пути их решения. 2017. Т.12, часть 2. 452 с.

Труды конференции подготовили: С.А. Варзин, В.В. Громова, О.Е. Пискун, У.В. Савченко, Т.В. Семенова, О.Ю. Тарасовская, Л.П. Чурилов, И.Л. Бондарчук, Н.Н. Венгерова, Г.Б. Дьяченко, Л.В. Люйк, Т.М. Пискун.

ISSN 2076-4618 *Post-print*

UDK 284; 611; 611.013; 611.014; 616.02; 618.92; 950

K. J. van Zwieten [a], K.P. Schmidt [a],
S.A. Varzin [b, c], O.E. Piskun [b], I.A. Zubova [a]

SOME EXAMPLES OF SUPERNUMERARY ANATOMICAL STRUCTURES IN ARM AND HAND ASSOCIATED WITH GENETIC CONDITIONS SUCH AS THE ELLIS-VAN CREVELD SYNDROME [14]

a) Functional Morphology, Department of Anatomy, University of Hasselt, Diepenbeek, Belgium, b) Department of Physical Culture and Adaptation, Peter-the-Great St. Petersburg Polytechnic University, St. Petersburg, Russia, c) Department of Intermediate Level Surgery, Faculty of Medicine, St. Petersburg State University, St. Petersburg, Russia,
koosjaap.vanzwieten@uhasselt.be

Introduction - supernumerary muscles.

During the ontogeny of human arm and hand, some supernumerary muscles or muscle groups are present, most of which disappear during further normal development. As an example, the contrahentes muscles may be mentioned, for all fingers in the hand. Of this group, only the adductor pollicis muscle of the thumb normally remains in humans [1]. However, among many other tetrapoda, this "contrahentes muscle layer is preserved in most of the great apes. The reason it degenerates in the human hand … is not understood" [2]. Another example, the extensor digitorum profundus muscle in the lower arm and hand, is possibly less known. Although described as a variation [3], this muscle layer is normally absent in humans, with the exception of our well-known (deep) extensor indicis and extensor digiti minimi muscles. Furthermore, in humans a fully developed extensor digitorum profundus muscle is associated with trisomy 18 [4]. In many non-human primates, however, this muscle is normally found [5] (Figure 1).

Supernumerary digital rays.

As explained recently [6], having five fingers is "the norm" for many species. However, the presence of *supernumerary digital rays* in the human hand, also known as *polydactyly*, may be a part of the so-called Ellis-van Creveld syndrome, currently abbreviated as EVC [7] (Figure 2). More details of the "Ellis-van Creveld gene" in this so-called postaxial polydactyly - an autosomal recessive ciliopathy [8] - was recently described in Amish and in Brasilian pedigrees [9].

[14] К. Ван Цвиетен, К. Шмидт, С. Варзин, О. Пискун, И. Зубова Некоторые примеры дополнительных анатомических структур в руке, генетически обусловленных, при синдроме ЭллисаВан Кревелда.

Historically interesting, one such case of EVC was already depicted in Holland by Kerckring, as early as 1670 [10, 11] (Figure 3).

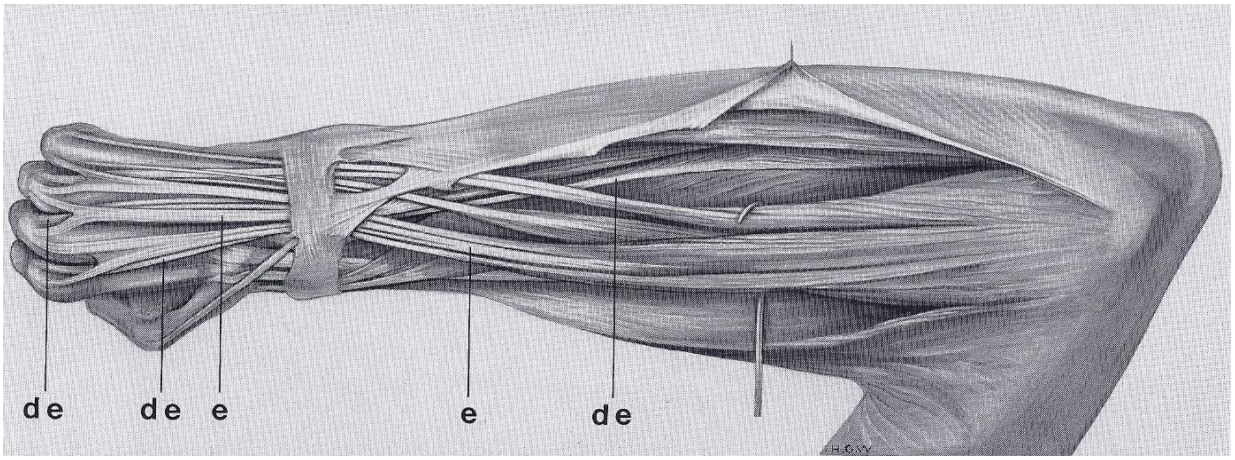

Figure 1.

Dorsal view of right forearm and midhand in *Macaca*. The fingers are flexed. Note the extensor digitorum (e) and extensor digitorum profundus (de) muscles and tendons. For each of the digits II-V there is a long and a deep extensor tendon.

This specific case of genetically determined polydactyly may be linked to the fleeing to Holland, starting from the second half of the seventeenth century, by the anabaptists or mennonites, Swiss and Palatinate (German) refugees to whom this genetic condition could be traced backwards [12]. Expelled from city and canton of Berne, Switzerland, the vicissitudes of life of these refugee groups have been lavishly documented by contemporary as well as by recent authors [13, 14].

Written history.

From these documents it becomes clear that a first group of these involuntary migrants arrived in Holland in April and May 1710 [13]. A following and much larger group of mennonites arrived in Amsterdam not earlier than in the evening of 3 August 1711 [14]. Some of them went to the Dutch Northern province of Groningen to labor in the marshes, eventually becoming peat-farmers there [14]. Others seized the opportunity to sail to Pennsylvania and settled down there as the Amish [13]. From this first group in 1710, it seems plausible that some youngsters chose to join the navy, i.e. the Dutch East India Company, like many European nationalities did those days. This is reflected by the fact that of all soldiers on the Dutch East India ship “Zuytdorp”, bound for the Cape of Good Hope and Java and departing from the port of Wielingen at the Dutch Isle of Walcheren on 1 August 1711 [15], 3 % were Swiss and some 45 % were German [16].

Figure 2.

“PA radiography of the right hand in a 13-year-old female. Extra finger (arrow) on the ulnar side of the hand (postaxial polydactyly). Partial bony fusion of fifth metacarpal and extra metacarpal. Short, broad middle phalanges and hypoplastic distal phalanges. The diagnosis of Ellis-van Creveld Syndrome (EvC) was made.” Data reproduced - permission granted by the Journal of the Belgian Society of Radiology and Ubiquity Press - from van Zwieten K. J. et al. (2007) Imaging of the hand, techniques and pathology: a pictorial essay. Belgian Journal of Radiology, 90, 5, 395-455, p. 443 [7].

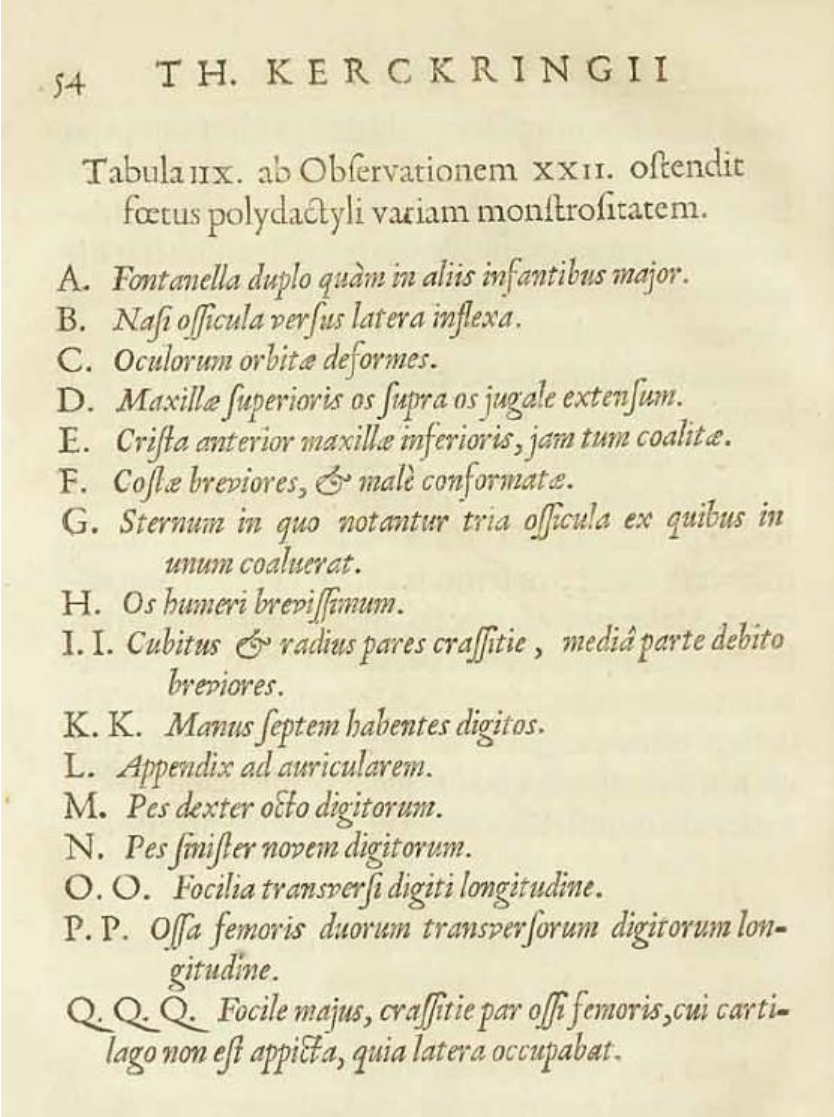

54 TH. KERCKRINGII

Tabula IIX. ab Obſervationem XXII. oſtendit fœtus polydactyli variam monſtroſitatem.

A. *Fontanella duplo quàm in aliis infantibus major.*
B. *Naſi oſſicula verſus latera inflexa.*
C. *Oculorum orbitæ deformes.*
D. *Maxillæ ſuperioris os ſupra os jugale extenſum.*
E. *Criſta anterior maxillæ inferioris, jam tum coalitæ.*
F. *Coſtæ breviores, & malè conformatæ.*
G. *Sternum in quo notantur tria oſſicula ex quibus in unum coaluerat.*
H. *Os humeri breviſſimum.*
I. I. *Cubitus & radius pares craſſitie, mediâ parte debito breviores.*
K. K. *Manus ſeptem habentes digitos.*
L. *Appendix ad auricularem.*
M. *Pes dexter octo digitorum.*
N. *Pes ſiniſter novem digitorum.*
O. O. *Focilia transverſi digiti longitudine.*
P. P. *Oſſa femoris duorum transverſorum digitorum longitudine.*
Q. Q. Q. *Focile majus, craſſitie par oſſi femoris, cui cartilago non eſt appicta, quia latera occupabat.*

Figure 3.

"Table 8, belonging to Observation 22.", indicating that the (right) hand possesses seven fingers (K.K.). From Kerckring T. (1670) Spicilegium Anatomicum, continens Observationum Anatomicarum rariorum centuriam unam. Amsterdam: Andreas Frisius, p. 54. © Herzog August Bibliothek Wolfenbüttel <http://diglib.hab.de/drucke/11-4-phys-1/start.htm?image=00084> [10].

Oral history.

As highlighted recently, traditional children's songs and nursery rhymes may recall dramatic events from the past, even the ones from centuries ago [17]. Following this statement, it can make sense to focus on this Dutch folk-song [18]:

> *There was a man-of-war, a warship long ago.*
> *Within an ace of foundering, she struck a reef below.*

This rhyme more or less applies to the fate of the "Zuytdorp", which in June 1712 wrecked on Western Australian rocks [15, 19]. Several of her passengers and crew apparently reached the rocky shores, after which local Aboriginal people helped

them to survive in the harsh climate. Abandoned forever, as these European castaways were (some must have been mennonites, see above), they presumably have interacted, and by cohabitation eventually mixed up with Western Australian Aboriginals. Some of their offspring in 1992 showed “a relatively high frequency of the Ellis-van Creveld gene” in combination with the post-axial polydactyly [12]

In this respect almost inevitably, another rhyme - a punctuation drill [20] - comes to mind, applicable to some of the castaways’ more fortunate distant cousins: the offspring of the Swiss / Palatinate peat-farmers in the Dutch Northern province of Groningen : *The peasants of the Northern Land, possess ten fingers on each hand.*

Summary and discussion.

We showed some examples of supernumerary structures in lower arm and hand, by means of their presence during ontogeny and in comparative anatomy. In non-human primates and their predecessors, the presence of such supernumerary muscles as the contrahentes muscles and the extensor digitorum profundus muscle, may be quite normal, while with respect to human anatomy most of these muscle-layers disappear during ontogeny [1, 2, 3]. Full persistence however, may be associated with certain genetic conditions [4]. A specific example of supernumerary digital rays in the definitive hand, namely the Ellis-van Creveld (EVC) syndrome or postaxial polydactyly, was then discussed [7]. First depicted in 1670 [10, 11], this genetic condition did persist by inheritance, in the offspring of 17th and 18th century mennonite migrants, fleeing from Switzerland and the Palatinate. Currently described in Amish and Brasilian families [9], this condition also occurs in Western Australian Aboriginal families [12]. By means of palaeography we made plausible that the most probable link with their Swiss and Palinate ancestors via Holland must be the following. Some members of the first mennonite refugee group, who arrived in Holland in April / May 1710 [13] may have joined the crew of the Dutch East India ship “Zuytdorp” during the next year. On 1 August 1711 this ship set sail from the port of Wielingen in Walcheren, Holland. After departing from the Cape of Good Hope on 22 April 1712 [15], she later that year wrecked on the Western Australian coast. Descendants of her castaways, who after being helped by local Aboriginals eventually mixed up with them, subsequently transmitted the EVC-gene in some Aboriginal families [12]. Certain fragments from oral history may support the palaeographic evidence [17].

Acknowledgements.

Next persons are thanked for their interest, encouragement and help over the past four years: Peter de Knijff, Thomas Vanderveldt, Pieter Bol, Frietson Galis, Alain Nchimi, and Johanna Mock.

MSc students of Biomedical Sciences at the University of Hasselt Joy Lodewijckx and Bjorn Hamburg are thanked for their active participation in 2017, during the preparation of this paper.

References.

1. Yamamoto C., Murakami T., Ohtsuka A. (1988) Homology of the adductor pollicis and contrahentes muscles: a study of monkey hands. Acta Medica Okayama, 42, 4, 215-226.
2. Carlson, B. M. (2014) Human Embryology and Developmental Biology, 5th ed. Philadelphia: Elsevier Saunders.
3. Yoshida Y. (1990) Anatomical Study on the Extensor Digitorum Profundus Muscle in the Japanese. Okajimas Folia Anatomica Japonica, 66, 6, 339-354.
4. Aziz M. A., Dunlap S. S. (1986) The Human Extensor Digitorum Profundus Muscle with Comments on the Evolution of the Primate Hand. Primates, 27, 3, 293-319.
5. van Zwieten K. J. (1980) The extensor assembly of the finger in man and non-human primates. A morphological, functional, and comparative anatomical study. PhD Thesis, University of Leiden. Leiden: Drukkerij J. J. Groen & Zoon.
6. Galis F., Arntzen J. W., Lande R. (2010) Dollo's Law and the Irreversibility of Digit Loss in Bachia. Evolution, 64, 8, 2466-76.
7. van Zwieten K. J., Brys P., Van Rietvelde F. *et al.* (2007) Imaging of the hand, techniques and pathology: a pictorial essay. Belgian Journal of Radiology, 90, 5, 395-455.
8. Verma P. K., El-Harouni A. A. (2015) Review of literature: genes related to postaxial polydactyly. Frontiers in Pediatrics, 3, 8, 1-8.
9. Ruiz-Perez V. L., Ide S. E., Strom T. M. *et al.* (2000) Mutations in a new gene in Ellis-van Creveld syndrome and Weyers acrodental dysostosis. Nature Genetics, 24, 283-286.
10. Kerckring T. (1670) Spicilegium Anatomicum, continens Observationum Anatomicarum rariorum centuriam unam. Amsterdam: Andreas Frisius.
11. Boer L., Radziun A. B., Oostra R.-J. (2016) Frederik Ruysch (1638-1731): Historical perspective and contemporary analysis of his teratological legacy. American Journal of Medical Genetics Part A, 173A, 16-41.
12. Goldblatt J., Minutillo C., Pemberton P. J., Hurst J. (1992) Ellis-van Creveld syndrome in a Western Australian Aboriginal community. Postaxial polydactyly as a heterozygous manifestation? The Medical Journal of Australia, 157, 4, 271-272.

13. de Hoop Scheffer J. G. (1878) Mennonite Emigration to Pennsylvania: Friendly Relations Between the Mennonites in Holland and Those in Pennsylvania. *In:* Mennonite Heritage Center Quarterly (2016) 19, 2, 5-12.
14. Dop B. E. (1995) 'Terwyl in de Kalkwyk veele dier doopsgezinden woonen'. Doopsgezinden in een Groninger veenkolonie in de achttiende eeuw. *In:* Doopsgezinde Bijdragen, Nieuwe reeks 21, Doopsgezinde Historische Kring Amsterdam. Hilversum: Uitgeverij Verloren, 97-132.
15. http://www.vochistory.org.au/zuytdorp.html, accessed 15 October 2017.
16. Peters N. (2014) The impact of the Dutch East India Company (VOC) on the history of the Indian Ocean Region and its impact on Western Australia. AAPI Lecture, Curtin University Sustainability Policy (CUSP) Institute, 15 May 2014
17. Maiti A., Naskar D. (2017) Of deception and dogma: the delusive history behind nursery rhymes. European Journal of English Language and Literature Studies, 5, 4, 27-52.
18. de Lange D., van Riemsdijk J. C. M., Kalff G. (1913) Nederlandsch volksliederenboek, eerste bundel, 9th ed. Amsterdam: S. L. van Looy.
19. McCarthy M. (2008) The Australian Contact Shipwrecks Program. *In:* Strangers on the Shore. Early coastal contacts in Australia. P. Veth, P. Sutton, M. Neale, Editors. Canberra: National Museum of Australia Press, 227-236.
20. Holwerda D. (1990) Punten en komma's (1). Opbouw, Opinieblad voor de Nederlands Gereformeerde Kerken, 34, 1.