

EDITORIAL

Getting the “Right” Perspective on Angiotensin Receptor–Neprilysin Inhibition in Heart Failure

Frederik H. Verbrugge , MD, PhD; Barry A. Borlaug , MD

The right and left ventricles conduct the same cardiac output under different loading conditions. The thick-walled left ventricle thickens extensively in a radial orientation during systole, making it well suited to generate the high pressures necessary to perfuse the systemic circulation. This is reflected by its underlying myocardial architecture, with primarily radial myocyte orientation in midlayers, subendocardial myocytes following a right-hand helix configuration, with subepicardial myocytes forming a left-hand helix.¹ In contrast, the thin-walled right ventricle (RV) ejects into a much lower impedance pulmonary circulation and is therefore poorly suited to generate pressure, making it highly sensitive to short- or long-term increases in afterload. Because of the predominant longitudinal orientation of its myocytes, with angulated intrusion of superficial myocytes toward the endocardium, the RV contracts more like a bellow.²

take the form of a primary muscle disorder, ischemic or toxic injury to the myocyte, or myocardial consequences of a systemic disease that alter cardiac function. In contrast, right-sided HF is rarely caused by a primarily cardiomyopathic process (<8% of cases).³ Rather, increased RV afterload secondary to left-sided HF (46%), intrinsic lung disease (17%), pulmonary thromboembolic disease (18%), and pulmonary arterial hypertension (11%) are the predominant causes of right HF. As such, most therapies for the latter syndrome focus on reducing RV afterload, preferentially by treating the underlying disease process. But what if the RV response to afterload mismatch was targeted rather than the load itself in isolation?

In this issue of the *Journal of the American Heart Association (JAHA)*, Sharifi Kia et al tested the hypothesis that cotreatment with the angiotensin receptor–neprilysin inhibitor (ARNi) sacubitril/valsartan would protect against development of maladaptive RV structural and functional changes in a pure pressure overload model in rats via banding of the main pulmonary artery (PA).⁴ Unlike other available pulmonary hypertension models, the PA banding model implies the absence of intrinsic pulmonary vascular pathological characteristics or lung disease. The effects of sacubitril/valsartan versus placebo were studied after a 21-day treatment window immediately following PA banding, so

See Article by Sharifi Kia et al.

These fundamental morphological and functional differences between the right and left sides of the heart translate into a different spectrum of diseases. In isolated left-sided heart failure (HF), an intrinsic cardiac insult typically initiates disease progression. This may

Key Words: Editorials ■ angiotensin receptor–neprilysin inhibitor ■ right ventricle–pulmonary arterial coupling

Correspondence to: Barry A. Borlaug, MD, Mayo Clinic and Foundation, 200 First St SW, Rochester, MN 55905. E-mail: borlaug.barry@mayo.edu

The opinions expressed in this article are not necessarily those of the editors or of the American Heart Association.

For Sources of Funding and Disclosures, see page 4.

© 2020 The Authors. Published on behalf of the American Heart Association, Inc., by Wiley. This is an open access article under the terms of the Creative Commons Attribution-NonCommercial-NoDerivs License, which permits use and distribution in any medium, provided the original work is properly cited, the use is non-commercial and no modifications or adaptations are made.

JAHA is available at: www.ahajournals.org/journal/jaha

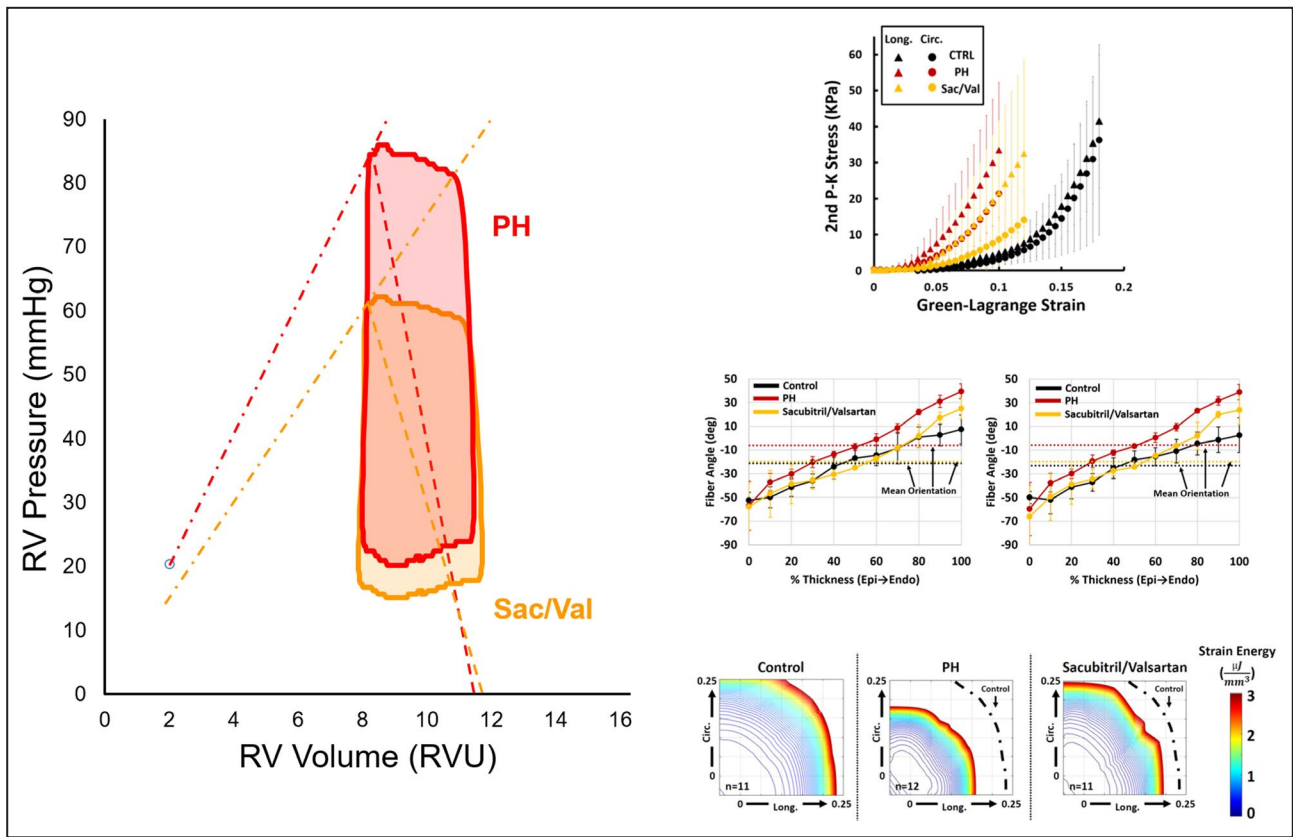


Figure. Effects of sacubitril/valsartan on hemodynamics, myocardial stress–strain relationship, and remodeling in a right ventricular (RV) pressure overload model through pulmonary artery (PA) banding.

The left-sided panel shows theoretical pressure–volume loops in rats with PA banding treated with placebo (red) vs sacubitril/valsartan (orange), on the basis of the summarizing data from the study by Sharifi Kia et al.⁴ The volume intercept of the end-systolic pressure–volume relationship (dotted line) was assumed to be 0 in both groups. As the pressure difference between the peak systolic RV pressure and the minimal diastolic RV pressure was reported in the article, RV diastolic pressure was imputed through an iterative method that matched best with the remainder of the hemodynamic data. The theoretical end-systolic volume and end-diastolic volume were calculated in relative volume units (RVUs) from the estimated imputed end-systolic pressure, end-systolic elastance, and stroke volume. On the basis of the authors’ data, treatment with sacubitril/valsartan likely had little impact on RV volumes, whereas both systolic and diastolic RV pressures were significantly reduced ($\Delta = -22.6$ mm Hg and $\Delta = -5.5$ mm Hg, respectively). RV stroke work (the shaded area of the pressure–volume loops) was reduced. In the right-sided panels (reproduced in part from Sharifi Kia et al.⁴ published on behalf of the American Heart Association, Inc., by Wiley under the terms of the Creative Commons Attribution Non-Commercial License (CC-BY-NC)), the upper figure demonstrates how treatment with sacubitril/valsartan (orange) mitigated changes in the myocardial stress–strain relationship induced by PA banding. The middle figure shows that the orientation of myocardial fibers remained normal in sacubitril/valsartan-treated animals, but became more longitudinal after placebo treatment. In the endocardial zone, some reorientation still occurred in sacubitril/valsartan-treated animals as well. Finally, the right bottom figure illustrates how sacubitril/valsartan treatment was associated with a relative preservation of circumferential strain energy. It remains unclear to what extent the favorable myocardial changes on the right are explained by the ostensible reductions in developed pressure and stroke work (on the left) compared with direct myocardial effects of sacubitril/valsartan, independent of loading. CTRL indicates control animals without PA banding; Circ., Circumferential strain energy; deg, degrees; Endo, endocardial; Epi, epicardial; Long., Longitudinal strain energy PH, animals with pulmonary hypertension through PA banding treated with placebo; P-K., Piola-Kirchhoff Stress and Sac/Val, animals with pulmonary hypertension through PA banding treated with sacubitril/valsartan.

this is a study of right HF prevention rather than treatment. In comparison to placebo-treated controls, the difference between maximal and minimal RV pressure was significantly lower following ARNi treatment. The absolute RV systolic pressure and RV volumes were not reported, but on the basis of the summarizing data reported by the authors, RV systolic pressure should have been ≈ 20 mm Hg lower in ARNi-treated animals versus controls, likely with similar chamber volumes (Figure, left panel). It

is surprising that RV systolic pressure was lower in treated animals, because hydraulic considerations would dictate that a given head of pressure is necessary to overcome the increased and fixed resistance to flow induced by PA banding in all animals, regardless of treatment. It may be that the increase in RV pressure with this model is overly exuberant, exceeding the necessary pressure increase to generate flow across a stenotic PA, and that somehow this was mitigated by ARNi.

The maximal increase in RV pressure with respect to time decreased with sacubitril/valsartan in the PA banding model, which is compatible with a negative inotropic effect, but again this may simply relate to the fact that a lower RV pressure was observed in ARNi-treated animals. Indeed, the RV does not need to increase pressure as rapidly if the peak-developed pressure is lower, as in the present study. Cardiac volumes were not measured, but stroke volume was quantified in relative volume units by a conductance catheter to derive a measure of pulmonary arterial elastance (E_a). The slope of the end-systolic pressure-volume relationship, or end-systolic elastance (E_{es}), was measured in most animals using transient caval occlusion. E_{es} is a load-independent measure of chamber contractility, whereas E_a is a “lumped” measure of arterial stiffness that incorporates resistive and pulsatile components of afterload. As such, the E_{es}/E_a ratio quantifies ventricular-arterial coupling. In humans with right-sided HF caused by pulmonary vascular disease, E_{es} increases, but RV ejection fraction decreases, because the increase in E_{es} is insufficient to match the increase in E_a . This is referred to as “uncoupling.” In the study from Sharifi Kia et al,⁴ E_{es} was nonsignificantly lower in ARNi-treated animals, with a difference of 2.7 mm Hg per relative volume unit compared with controls. This falls in agreement with the maximal increase in RV pressure with respect to time measurements and suggests a negative inotropic effect with ARNi, but this may be better interpreted as the lack of an increase in contractility because of a reduction in hydraulic work with ARNi (lower stroke work, shaded area of the loops, Figure). Because stroke volume was similar in both groups, but RV pressure was lower with ARNi treatment, E_a was reduced and E_{es}/E_a was accordingly higher compared with controls. In other words, sacubitril/valsartan mitigated the uncoupling that occurs with PA banding predominantly through a reduction in RV pressures. The mechanisms leading to this effect are not clear from the authors’ data. Perhaps improved natriuresis following neprilysin inhibition could influence the vascular endothelium and endocardium.⁵ Notably, sacubitril/valsartan has been demonstrated to increase natriuresis in humans with salt-sensitive hypertension.⁶

Regardless of its mechanism, RV unloading with ARNi treatment was associated with favorable morphologic and functional changes, including less pronounced RV free wall thickening compared with controls, yet a similar relative mass of the right versus left ventricle. This argues against significant eccentric remodeling that would be expected in case of an increased RV end-diastolic volume. This is important because RV dilation commonly develops in tandem with RV dysfunction in human right-sided HF, causing geometric changes in the RV that beget worsening tricuspid

regurgitation, promulgating a vicious cycle of remodeling and dysfunction.⁷ On a structural level, the study by Sharifi Kia et al shows that ARNi treatment prevented transmural reorientation of myofibers in a more longitudinal direction from the apex to the RV outflow tract, while counteracting the increase in myofiber stiffness induced by RV pressure overload (Figure, right panel).⁴ Although these changes would be expected to be coupled with improved mechanical properties over time, no impact on collagen deposition or myocardial fibrosis was observed. Collectively, these findings seem more compatible with unloading of the RV than with direct protective effects of sacubitril/valsartan on the myocardium or interference with cardiomyopathic processes. It is again notable that RV pressure was lower with ARNi in the present study, in contrast to earlier studies evaluating therapies targeting the RV response to PA banding, where RV pressure was similar in treated animals, whereas RV structure and function improved.⁸

The current results are consistent with a prior study evaluating the effects of sacubitril/valsartan in a different model of right-sided HF (ie, hypoxia-induced pulmonary hypertension).⁹ That study also showed a reduction in RV pressures and RV hypertrophy with ARNi treatment, but in contrast to the present study, the authors also demonstrated reduced myocardial fibrosis. It is possible that this difference relates to the nature of the model, or to the duration of treatment (6 versus 3 weeks in the present study). More important, ARNi treatment was associated with a lower diastolic RV pressure in the earlier study, which is probably the most important clinical indicator of RV failure.

ARNi treatment may also directly affect the pulmonary vasculature, promoting vasodilation and preventing intima/media hypertrophy to reduce resistive load.⁹ Neprilysin cleaves and inactivates numerous vasoactive peptides, including but not limited to natriuretic peptides and adrenomedullin.¹⁰ Many of these peptides affect the pulmonary circulation, with vasodilatory actions resulting in a lower pulmonary vascular resistance and pressure. A recent study in patients with HF with preserved ejection fraction has shown that one of the most robust neurohormonal “signatures” of group 2 pulmonary hypertension are elevations in endothelin-1 and adrenomedullin, with the latter presumably increased as a counterregulatory response to the former.¹¹ Further study is required to determine the mechanisms by which neprilysin blockade exerts favorable effects on specific peptides that determine RV loading and RV responses to load mismatch.

Observational data in humans suggest that ARNi therapy, when used as a treatment for left-sided heart disease, reduces pulmonary hypertension.^{12,13} The current preclinical results are encouraging to investigate further the effects of ARNi therapy in right HF. However, it remains to be seen to what extent the findings in this

rat model can be extrapolated to clinical practice, where a myriad of interacting pathophysiological mechanisms are operative. Although the pharmacokinetics and pharmacodynamics differ across species, it is notable that the sacubitril/valsartan dose used in both preclinical ARNi studies was ≈ 10 to 15 times higher than the currently approved dose to treat left-sided HF.

Regardless of the cellular mechanisms, the elegant study from Sharifi Kia et al⁴ provides important new preclinical insights that may have significant implications for the treatment of right-sided HF. The current data are especially notable because in this model, the proximate cause of right HF was not directly targeted by the intervention, but RV remodeling was still improved. Maybe in this situation, the “right” perspective is that it is not the stress, but the response to stress that matters, and mitigating this response therapeutically may finally allow us to make some progress in the management of patients with right-sided HF, a phenotype that has for too long been neglected in the field.

ARTICLE INFORMATION

Affiliations

From the Department of Cardiovascular Diseases (F.H.V., B.A.B.), and Biomedical Research Institute, Faculty of Medicine and Life Sciences, Hasselt University, Hasselt, Belgium (F.H.V.)

Sources of Funding

Dr Verbrugge is supported by a Fellowship of the Belgian American Educational Foundation and by the Special Research Fund (BOF) of Hasselt University (BOF19PD04). Dr Borlaug is supported by R01 HL128526, from the National Institutes of Health.

Disclosures

Dr Verbrugge has received consultancy fees and a travel grant from Novartis, which owns the exclusive rights on sacubitril/valsartan. Dr Borlaug has no disclosures to report.

REFERENCES

1. Streeter DD Jr, Spotnitz HM, Patel DP, Ross J Jr, Sonnenblick EH. Fiber orientation in the canine left ventricle during diastole and systole. *Circ Res*. 1969;24:339–347.
2. Ho SY, Nihoyannopoulos P. Anatomy, echocardiography, and normal right ventricular dimensions. *Heart*. 2006;92(suppl 1):i2–i13.
3. Padang R, Chandrashekar N, Indrabhinduwat M, Scott CG, Luis SA, Chandrasekaran K, Michelena HI, Nkomo VT, Pislaru SV, Pellikka PA, et al. Aetiology and outcomes of severe right ventricular dysfunction. *Eur Heart J*. 2020;41:1273–1282.
4. Sharifi Kia D, Benza E, Bachman TN, Tushak C, Kim K, Simon MA. Angiotensin receptor-neprilysin inhibition attenuates right ventricular remodeling in pulmonary hypertension. *J Am Heart Assoc*. 2020;9:e015708. DOI: 10.1161/JAHA.119.015708.
5. Nijst P, Verbrugge FH, Grieten L, Dupont M, Steels P, Tang WH, Mullens W. The pathophysiological role of interstitial sodium in heart failure. *J Am Coll Cardiol*. 2015;65:378–388.
6. Wang TD, Tan RS, Lee HY, Ihm SH, Rhee MY, Tomlinson B, Pal P, Yang F, Hirschhorn E, Prescott MF, et al. Effects of sacubitril/valsartan (LCZ696) on natriuresis, diuresis, blood pressures, and NT-proBNP in salt-sensitive hypertension. *Hypertension*. 2017;69:32–41.
7. Obokata M, Reddy YNV, Melenovsky V, Pislaru S, Borlaug BA. Deterioration in right ventricular structure and function over time in patients with heart failure and preserved ejection fraction. *Eur Heart J*. 2019;40:689–697.
8. Budas GR, Boehm M, Kojonazarov B, Viswanathan G, Tian X, Veeroju S, Novoyatleva T, Grimminger F, Hinojosa-Kirschenbaum F, Ghofrani HA, et al. ASK1 inhibition halts disease progression in preclinical models of pulmonary arterial hypertension. *Am J Respir Crit Care Med*. 2018;197:373–385.
9. Clements RT, Vang A, Fernandez-Nicolas A, Kue NR, Mancini TJ, Morrison AR, Mallem K, McCullough DJ, Choudhary G. Treatment of pulmonary hypertension with angiotensin II receptor blocker and neprilysin inhibitor sacubitril/valsartan. *Circ Heart Fail*. 2019;12:e005819.
10. D'Elia E, Iacovoni A, Vaduganathan M, Lorini FL, Perlini S, Senni M. Neprilysin inhibition in heart failure: mechanisms and substrates beyond modulating natriuretic peptides. *Eur J Heart Fail*. 2017;19:710–717.
11. Obokata M, Kane GC, Reddy YNV, Melenovsky V, Olson TP, Jarolim P, Borlaug BA. The neurohormonal basis of pulmonary hypertension in heart failure with preserved ejection fraction. *Eur Heart J*. 2019;40:3707–3717.
12. De Simone V, Guarise P, Zanotto G, Morando G. Reduction in pulmonary artery pressures with use of sacubitril/valsartan. *J Cardiol Cases*. 2019;20:187–190.
13. Zern EK, Cheng S, Wolfson AM, Hamilton MA, Zile MR, Solomon SD, Kittleson MM. Angiotensin receptor-neprilysin inhibitor therapy reverses pulmonary hypertension in end-stage heart failure patients awaiting transplantation. *Circ Heart Fail*. 2020;13:e006696.