

Long-term neurosensory disturbances after modified sagittal split osteotomy

O. da Costa Senior^{a,b,*}, B. Gemels^a, F. Van der Cruyssen^{a,b}, J.O. Agbaje^b,
G. De Temmerman^a, E. Shaheen^b, I. Lambrichts^c, C. Politis^{a,b}

^a University Hospitals Leuven, Campus Sint-Rafaël, Department of Oral and Maxillofacial Surgery, Kapucijnenvoer 33, 3000 Leuven, Belgium

^b OMFS-IMPACT Research Group, Department of Imaging and Pathology, Faculty of Medicine, Catholic University of Leuven, Kapucijnenvoer 33, 3000 Leuven, Belgium

^c Laboratory of Morphology, Biomedical Research Institute (BIOMED), Hasselt University, Campus Diepenbeek, Agoralaan building D, 3590 Diepenbeek, Belgium

Accepted 5 May 2020

Available online 4 July 2020

Abstract

We have investigated the long-term incidence of neurosensory disturbances after modified bilateral sagittal split osteotomy, and identified associated risk factors. We prospectively studied 376 patients, and their self-reported neurosensory disturbances were evaluated six months, and one, two, and three years postoperatively. The correlations between the following risk factors and neurosensory disturbances were investigated using univariate analysis and stepwise multivariate analysis: age at operation, sex, type of movement (advancement, setback, or rotation), concurrent genioplasty, type of detachment, iliac crest bone graft, and use of dicalcium phosphate synthetic bone graft. Probabilities of less than 0.05 were accepted as significant. Three years postoperatively, 57 patients (15%) reported altered sensation of the lower lip or chin. Older age correlated significantly with neurosensory disturbances ($p < 0.0001$). Greater mandibular advancement correlated with postoperative “positive” neurosensory phenomena (right side $p = 0.08$; left side $p = 0.03$). Intraoperative surgical manipulation of the left inferior alveolar nerve was significantly associated with postoperative hypoaesthesia ($p = 0.014$). Older age at surgery, extensive mandibular advancement, and surgical manipulation of the left inferior alveolar nerve, were associated with long-term neurosensory disturbances after modified bilateral sagittal split osteotomy. The modified operation seems to safeguard the inferior alveolar nerve from transection, without causing damage to other nerves.

© 2020 The Author(s). Published by Elsevier Ltd on behalf of The British Association of Oral and Maxillofacial Surgeons. This is an open access article under the CC BY-NC-ND license (<http://creativecommons.org/licenses/by-nc-nd/4.0/>).

Keywords: Neurosensory disturbances; sagittal split osteotomy; hypoaesthesia; nerve detachment; inferior alveolar nerve

Introduction

Neurosensory disturbance (NSD) after bilateral sagittal split osteotomy (BSSO) is a common complication, and the cause of considerable comorbidity.^{1–3} In particular, neurosensory

phenomena such as hyperaesthesia, paraesthesia, and dysaesthesia lead to patients’ dissatisfaction. A meta-analysis found a mean incidence of patient-reported NSD of 33.9% one year postoperatively.⁴ It has been hypothesised that injury to the peripheral nerves may cause permanent NSD postoperatively; more specifically, perioperative axonal nerve injury of the inferior alveolar nerve (IAN) may be followed by postoperative maladaptive neuroplasty.^{5–7} The risk factors for the development of NSD include older age, intraoperative encounter with the nerve, and concurrent genioplasty.^{4,8–12}

* Corresponding author at: Kapucijnenvoer 33, E91, Department Oral and Maxillofacial surgery, 3000 Leuven, Belgium. Tel.: +3216 33 24 62; Fax: +3216 33 24 37.

E-mail address: Oliver.dacosta@uzleuven.be (O. da Costa Senior).

The influence of sex and the extent of bilateral sagittal split osteotomy (BSSO) advancement on the outcome of NSD remains a matter of debate.^{12–14}

Ever since the introduction of BSSO in 1957 by Trauner and Obwegeser, modifications have been proposed to reduce complications such as postoperative swelling, haemorrhage, and manipulation of the neurovascular bundle.¹⁵ The most well-known modifications are those by Hunsuck¹⁶ and Epker.¹⁷ Politis et al also reported a modified buccal sagittal split osteotomy in 2014.⁸ The modification allows a controlled split of the lower border at the anterior osteotomy site of the mandibular body with a piezotome, to decrease the risk of damage to the IAN, particularly when the nerve is located near the lower border of the mandible.

The primary aim of this study was to evaluate prospectively the long-term incidence of NSD at follow-up after a modified buccal sagittal split technique. The secondary aim was to identify individual and intraoperative risk factors for the development of NSD, which were categorised as “positive” and “negative” sensory phenomena.

Patients and methods

Patients

This prospective study included 380 patients who were treated consecutively. The inclusion criterion was: all patients who underwent BSSO with a modified buccal osteotomy technique between January 2013 and September 2016. The exclusion criteria were the presence of NSD preoperatively and being lost to follow-up.

Collection of data

The following data were collected: patient’s age at operation; sex; class of malocclusion; type of movement; concurrent Le Fort I or genioplasty procedure, or both; the need for, and the type of, detachment of the nerve; and the intraoperative use of an iliac crest bone graft or dicalcium phosphate synthetic bone graft. The type of movement refers to the advancement, and setback or rotation, of the mandible, or both. The type of detachment refers to the need to detach the IAN from the proximal segment of the mandible. This was classified according to the side operated on and according to the need for non-surgical detachment (using a freer) or for more invasive, surgical detachment (using a piezoelectrical device) (Mectron s.p.a, Bois d’Amont). The extent of the mandibular advancement was evaluated using panoramic radiography. The radiographic image was taken one week postoperatively and was subsequently analysed as described by Agbaje et al.¹⁸

Surgical technique

All patients were treated at one centre by the same surgical team (three maxillofacial surgeons) using the modified sagittal split osteotomy technique described by Politis et al⁸ and Agbaje et al.¹⁸ Rigid fixation was achieved using miniplates and monocortical screws. When it was deemed necessary (based on the patient’s age and the width of the bone gap) a dicalcium phosphate synthetic bone graft (CopiOs® Bone Void Filler) was used, without fixation, to support postoperative bone formation and to avoid a bony defect at the lower border of the mandible. An iliac crest bone graft was used to cover bony gaps either at the maxilla (in case of a concurrent Le Fort I procedure) or at the mandible (at the buccal gap).

Neurosensory test procedure

All 376 patients were examined preoperatively and one week, six weeks, three months, six months, one year, and two years postoperatively. A subgroup of 279 patients treated consecutively between January 2013 and September 2015 had follow-up appointments three years postoperatively. A light brush technique and two-point discrimination were used at each follow-up consultation. Anaesthesia was evaluated using the pin-prick test. Altered sensation was categorised as either hypoaesthesia or as “positive” sensory phenomena such as hyperaesthesia, dysaesthesia, or paraesthesia. The severity of the NSD was neither described nor recorded. The location of the sensory impairment was categorised as left lower lip, right lower lip, or central chin. Lingual nerve damage was evaluated using a light-brush technique, and injury to the marginal mandibular branch of the facial nerve was assessed clinically.

Statistical analysis

Patients and operational characteristics were analysed using descriptive statistics. Continuous variables were described as the number of observations, mean, median, SD, and range. Categorical variables were described using absolute counts and percentages.

First, Spearman’s rank correlation analysis was used to establish the relation between the risk factors for development of NSD. Secondly, parametric univariate analysis was used to find out which variables correlated significantly with the NSD outcomes hypoaesthesia and “positive” neurosensory phenomena for each combination of NSD outcome and explanatory variable separately, by means of a generalised linear model for binary outcomes using a logit link. A probability of less than 0.05 was considered significant. Finally, a stepwise model selection (multivariable regression) using generalised linear models for binary data and a logit link was used to identify the variables that contributed to hypoaesthesia, “positive” neurosensory phenomena, and NSD two years postoperatively.

Table 1
Surgical characteristics of 376 patients treated by modified sagittal split osteotomy.

Type of movement	Yes, n or mm	%
Advancement	303	80.6
<i>Left</i>	8.34 mm (3.18) mm	
<i>Right</i>	7.89 mm (2.91) mm	
Setback	69	18.3
Rotation	122	32.4
<i>Left</i>	61	16.2
<i>Right</i>	61	16.2
Concurrent Le Fort I	156	41.5
Concurrent genioplasty	84	22.3
Iliac crest bone graft	101	26.9
CopiOs®	109	29

The number of patients (n) and measurements are shown for the indicated types of mandibular movement. CopiOs® is the dicalcium phosphate synthetic bone graft that was applied perioperatively as needed at the bone gap.

Table 2
Inferior alveolar nerve detachment in 376 patients during right and left sagittal split osteotomy (SSO). Data are number (%).

	Right SSO (n = 376) No. (%)	Left SSO (n = 376) No. (%)
Free nerve	259 (69)	220 (59)
Freer	76 (20)	103(27)
Piezoelectrical device	52 (14)	72 (19)

As appropriate, the nerve was detached with a freer, or with a piezoelectrical device.

Results

Descriptive results

The records of a total of 380 consecutively-treated patients who had had modified buccal split osteotomy were analysed. After we had excluded three patients because they already had NSD, and one who was lost to follow-up, 376 patients were included in this study. The mean (SD) age was 26 (11) years (range 14–66). Of the 376 patients, 243 (65%) were female, giving a male:female ratio of 1:1.8 (Table 1).

Table 2 shows the need for intraoperative surgical detachment of the IAN. On the right side of the mandible, 117 (31%) inferior alveolar nerves required detachment using either a freer or a piezoelectrical device. On the left side of the mandible, 156 (42%) nerves required detachment. Table 3 shows the primary outcome. At two years postoperatively, 61/376 (16%) patients reported NSD. In the subgroup with three years' follow-up, 41 of the 269 patients (15%) reported altered sensation of the lower lip or chin, while four recovered sensation in the lip and chin area between two and three years postoperatively. McNemar's test showed no significant change between two and three years postoperatively (p = 0.1336).

There was no perioperative transection of the IAN and no anaesthesia of the lower lip and chin. There were no injuries

Table 3
Neurosensory outcomes in 376 patients after right and left sagittal split osteotomy.

	Six months (n = 376) No. (%)	One year (n = 376) No. (%)	Two years (n = 376) No. (%)	Three years (n = 269) No. (%)
NSD total	152 (40)	63 (17)	61 (16)	41 (15)
Hyperaesthesia: right	13(3.5)	8 (2)	8 (2)	7 (3)
Hyperaesthesia: left	12 (3)	9 (2)	9 (2)	8 (3)
Hypoaesthesia: right	110 (29)	26 (7)	26 (7)	15 (6)
Hypoaesthesia: left	104(28)	26 (7)	26 (7)	19 (6)
Chin	18 (5)	8 (2)	7 (2)	4 (2)

The neurosensory disturbance (NSD) total indicates the number of patients with NSD at the indicated times postoperatively. Hypoaesthesia and “positive” neurosensory phenomena (hyperaesthesia) are described for the right and left sides of the mandible. NSD of the central chin region was present bilaterally.

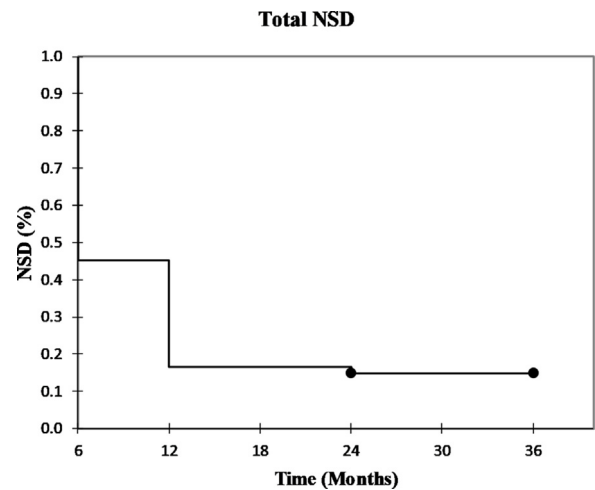


Fig. 1. Neurosensory outcome. Kaplan-Meier curve showing incidence of neurosensory disturbance (y-axis) as a function of time (x-axis).

to the lingual nerve or to the marginal mandibular branch of the facial nerve. Fig. 1 shows the evolution of the patients with NSD six months, one year, two years, and three years postoperatively.

Correlation analysis and univariate and stepwise model building selection

Spearman's rank correlation analysis showed no clinically relevant correlation of risk factors with NSD. Univariate analysis showed a significant relation between increasing age at the time of operation and both hypoaesthesia and “positive” neurosensory phenomena (Table 4). The degree of advancement showed a significant correlation with the development of “positive” neurosensory phenomena on the left side (p = 0.03), but the correlation on the right side was not significant (p = 0.08).

The intraoperative need for detachment (p = 0.014) and surgical detachment (p = 0.0138) of the left IAN was sig-

Table 4
Univariate analysis of 376 patients 2 years after right and left sagittal split osteotomy.

Variable	Hyperaesthesia: right (test value) P value	Hyperaesthesia: left (test value) P value	Hypoesthesia: right (test value) P value	Hypoesthesia: left (test value) P value	NSD total (test value) P value
Age	(3.416) <0.001	(3.300) <0.001	(4.095) <0.001	(3.604) <0.001	(5.694) <0.001
Sex	(-0.614) 0.541	(-0.821) 0.413	(-1.735) 0.084	(-0.928) 0.355	(-1.904) 0.058
Advancement:					
Left	–	(2.001) 0.031	–	(1.733) 0.083	(1.375) 0.171
Right	(1.783) 0.081	–	(-0.778) 0.439	–	(0.741) 0.461
Setback	(-0.429) 0.669	(0.303) 0.763	(-0.404) 0.687	(0.643) 0.522	(-0.070) 0.944
Rotation:					
Left	(-0.288) 0.774	(0.491) 0.625	(0.430) 0.668	(-0.667) 0.506	(0.039) 0.969
Right	(-0.288) 0.774	(-0.027) 0.976	(-0.667) 0.506	(-0.667) 0.506	(-1.090) 0.277
Genioplasty	(0.182) 0.856	(-0.009) 0.993	(-0.394) 0.695	(-1.742) 0.083	(-0.211) 0.834
Iliac crest bone graft	(0.679) 0.498	(0.442) 0.660	(-0.450) 0.654	(0.007) 0.994	(-0.122) 0.904
CopiOs®	(0.515) 0.608	(0.996) 0.321	(-1.150) 0.252	(0.176) 0.861	(-0.260) 0.796
Need for detachment:					
Left	–	(-1.657) 0.099	–	(2.470) 0.014	(1.327) 0.186
Right	(-1.089) 0.278	–	(-0.478) 0.634	–	(-1.198) 0.233
Freer:					
Left	–	(-0.024) 0.978	–	(-0.064) 0.949	(-0.550) 0.584
Right	(-0.542) 0.589	–	(-1.121) 0.264	–	(-1.490) 0.138
Surgical detachment:					
Left	–	(-0.616) 0.539	–	(2.481) 0.014	(1.501) 0.135
Right	(-0.025) 0.978	–	(0.821) 0.413	–	(-0.177) 0.860

The neurosensory disturbance(NSD) total includes both positive neurosensory phenomena and hypoesthesia at the lower lip and at the chin region. Hypoesthesia and positive neurosensory phenomena are described for the right and left sides of the mandible. Statistical analysis was by a generalised linear model for binary outcomes using a logit link. $P < 0.05$ was accepted as significant.

Table 5
Stepwise model building selection of 376 patients two years after right and left sagittal split osteotomy.

Contributing factors	Hyperaesthesia (right)	Hyperaesthesia (left)	Hypoesthesia (right)	Hypoesthesia (left)	NSD total
Age at operation	Yes	Yes	Yes	Yes	Yes
Advancement	Yes	Yes	–	–	–
Surgical detachment	–	–	–	Left	–
Bone graft	–	–	Yes	–	Yes
Genioplasty	–	–	–	Yes	–
CopiOs®	–	Yes	Yes	–	–

The neurosensory disturbance (NSD) total includes CopiOs® both positive neurosensory phenomena and hypoesthesia at the lower lip and at the chin region. Hypoesthesia and positive neurosensory phenomena (hyperaesthesia) are described for the right and left side of the mandible.

nificantly associated with postoperative hypoesthesia. This correlation was not found on the right side of the mandible.

Stepwise model building showed that increasing age at the time of operation contributed to development of total NSD, “positive” neurosensory phenomena, and hypoesthesia two years postoperatively (Table 5). Surgical detachment of the IAN was associated with hypoesthesia on the left side of the mandible. In contrast to univariate analysis, genioplasty was associated with the development of hypoesthesia on the left side. Increasing advancement of the distal mandibular segment contributed to the development of “positive” neurosensory phenomena on both sides.

Discussion

In this study we prospectively evaluated the long-term incidence of postoperative NSD after modified SSO. We found that two years postoperatively, 16% of patients experienced altered sensitivity of the chin, or the lower lip, or both, while 15% of patients complained of this three years postoperatively. This difference was not significant, indicating that two years’ follow-up would be sufficient to estimate long-term neurosensory deficits.

There was no anaesthesia of the lower lip, or chin area, or both, with the modified sagittal split technique. Considering the number of sites (376×2) this is a remarkable result, which could be attributed to the modification of the sagittal split at the lower border. It is difficult to compare this result with those of other studies because of a lack of standardised neurosensory assessment methods.^{19,20} Despite these drawbacks, a meta-analysis by Verweij et al⁴ reported a mean incidence of NSD of 33.9% using subjective neurosensory testing one year postoperatively. Alolayan and Leung²¹ reported an incidence of NSD of 13.8%/operated mandibular side two years after mandibular orthognathic surgery. Our results seem to be in accordance with these reports. The initial report of the BSSO technique, without the modification of the sagittal split that was published by Politis et al,⁹ reported postoperative NSD in 21.6% of the patients. This is higher than we found, even though the patient-specific variables and surgical variables in that study were comparable to those in ours. This reduction in the incidence of NSD could be the result of a decrease in the need for surgical detachment of the IAN.

In 2014, Politis et al also reported an incidence of NSD of 9.4% one year postoperatively in patients who had had the modified SSO.⁸ The lower incidence of NSD could be the result of less need for intraoperative surgical detachment of the neurovascular bundle in the previous study (4.4% for the right side and 6.2% for the left side).

The secondary aim of this study was to identify possible risk factors for the development of NSD. Increasing age showed a significant association with postoperative NSD, as in other reports.^{8,9,12,22} This might be explained by axonal atrophy in older patients, as well as a decreased capacity for

nerve regeneration.²² The amount of advancement did not correlate significantly with postoperative hypoesthesia, but a significant correlation was found between the amount of advancement and the development of “positive” neurosensory phenomena on the left side.

Westermarck et al¹² did not find a long-term correlation between postoperative loss of IAN function and the extent of BSSO advancement. However, Thygesen et al¹³ and Ylikontiola et al¹¹ reported a significant correlation between NSD and a greater extent of advancement. Three causal factors might explain the development of “positive” neurosensory phenomena. First, the altered sensations could result from stretching of the IAN, leading to neuropraxia or axonotmesis.^{11,23} Secondly, extensive mandibular advancement could both crush and stretch the IAN. Such a crushing injury might occur at the level of the bony protuberance of the proximolingual part of the distal mandibular segment, as the nerve must curve around this protuberance into the mandibular canal. Thirdly, exposing the nerve throughout the extension of the gap might prevent the desired vascularisation from the vasa nervorum. This could cause hypoxia and ischaemia, with subsequent axonal damage and development of NSD.²⁴ Measuring perioperative and postoperative axonal vascularisation and their association with resulting nerve damage could provide insights into why NSD develops.

Univariate analysis of genioplasty showed no significant association with NSD. However, concurrent genioplasty is considered by several research workers to be a well-established risk factor (with the exception of Bruckmoser et al¹⁴ who found no significant correlation).^{9,10,25}

Surgical detachment of the IAN during BSSO correlated significantly with the development of hypoesthesia, which could be because the main surgeon was right-handed, so it may be more technically challenging to use the piezoelectrical device on the left side of the mandible.

The main limitation of this study was that the measurement of NSD relied on subjective clinical examination for alterations in sensation, which reduced the reproducibility of the neurosensory evaluation. Additional information could be obtained through the use of a more objective evaluation of sensory function - for example, by quantitative sensory testing, measuring trigeminal somatosensory evoked potentials, sensory nerve action potentials, or blink reflex methods. However, Phillips and Essick²⁶ reported that patients’ self-reporting is reliable compared with objective measurement of NSD. From the patient’s perspective, subjective measurement is probably a more representative outcome than objective assessment of neural damage.

Conclusion

In this prospective study, we reported sensory impairment of the lower lip of 16% at the two-year follow-up, and 15% at the three-year follow-up. No patient presented with clin-

ical signs of nerve transection, so the modified procedure did not fulfil the aim of causing less neurosensory impairment than previous techniques. However, it did safeguard the IAN from transection without causing damage to the LN and VII nerve. Sensory impairment did not significantly change between the two- and three-year follow-up, indicating that long-term follow up of sensory impairment for up to 24 months is sufficient.

The study confirms the following risk factors for the development of sensory disturbance of the IAN: increased age, extensive mandibular advancement, and surgical detachment procedures. The orthodontic community should therefore remain aware that youth rather than older age is preferred when sagittal split osteotomy is indicated. Further technical advancement in the sagittal split technique should aim to eliminate the need for surgical manipulation of the IAN.

Conflict of interest

We have no conflicts of interest.

Ethics statement/confirmation of patients' permission

This study complies with the Declaration of Helsinki "Ethical Principles for Medical Research Involving Human Subjects". Ethics approval was obtained from the Ethics Review Board of the University Hospitals Leuven (S55873). All patients provided written informed consent.

Acknowledgement

We thank the biostatistician Mr. Wim Coucke for his expertise in statistical analysis and for his helpful advice.

References

1. Bothur S, Blomqvist JE. Patient perception of neurosensory deficit after sagittal split osteotomy in the mandible. *Plast Reconstr Surg* 2003;**111**:373–7.
2. Lee EGL, Ryan FS, Shute J, et al. The impact of altered sensation affecting the lower lip after orthognathic treatment. *J Oral Maxillofac Surg* 2011;**69**:e431–45.
3. Kuhlefelt M, Laine P, Suominen AI, et al. Nerve manipulation during bilateral sagittal split osteotomy increases neurosensory disturbance and decreases patient satisfaction. *J Oral Maxillofac Surg* 2014;**72**:2052.e1.e5.
4. Verweij JP, Houppermans PNWJ, Gooris P, et al. Risk factors for common complications associated with bilateral sagittal split osteotomy: A literature review and meta-analysis. *J Craniomaxillofacial Surg* 2016;**44**:1170–80.
5. Teerijoki-Oksa T, Jääskeläinen SK, Soukka T, et al. Subjective sensory symptoms associated with axonal and demyelinating nerve injuries after mandibular sagittal split osteotomy. *J Oral Maxillofac Surg* 2011;**69**:e208–13.
6. Jääskeläinen SK, Teerijoki-Oksa T, Virtanen A, et al. Sensory regeneration following intraoperatively verified trigeminal nerve injury. *Neurology* 2004;**62**:1951–7.
7. Kehlet H, Jensen TS, Woolf CJ. Persistent postsurgical pain: risk factors and prevention. *Lancet* 2006;**367**:1618–25.
8. Politis C, Lambrichts I, Sun Y, et al. Attachment rate of the inferior alveolar nerve to buccal plate during bilateral sagittal split osteotomy influences self-reported sensory impairment. *J Craniomaxillofacial Surg* 2014;**25**:2121–6.
9. Politis C, Sun Y, Lambrichts I, et al. Self-reported hypoesthesia of the lower lip after sagittal split osteotomy. *Int J Oral Maxillofac Surg* 2013;**42**:823–9.
10. van Merkesteyn JP, Zweers A, Corputty JE. Neurosensory disturbances one year after bilateral sagittal split mandibular ramus osteotomy performed with separators. *J Craniomaxillofacial Surg* 2007;**35**:222–6.
11. Ylikontiola L, Kinnunen J, Oikarinen K. Factors affecting neurosensory disturbance after mandibular bilateral sagittal split osteotomy. *J Oral Maxillofac Surg* 2000;**58**:1234–40.
12. Westermarck A, Bystedt H, von Konow L. Inferior alveolar nerve function after sagittal split osteotomy of the mandible: correlation with degree of intraoperative nerve encounter and other variables in 496 operations. *Br J Oral Maxillofac Surg* 1998;**36**:429–33.
13. Thygesen TH, Bardow A, Helleberg M, et al. Risk factors affecting somatosensory function after sagittal split osteotomy. *J Oral Maxillofac Surg* 2008;**66**:469–74.
14. Bruckmoser E, Bulla M, Alacamlioglu Y, et al. Factors influencing neurosensory disturbance after bilateral sagittal split osteotomy: Retrospective analysis after 6 and 12 months. *Oral Surg Oral Med Oral Pathol Oral Radiol* 2013;**115**:473–82.
15. Trauner R, Obwegeser H. The surgical correction of mandibular prognathism and retrognathia with consideration of genioplasty. I. Surgical procedures to correct mandibular prognathism and reshaping of the chin. *Oral Surg Oral Med Oral Pathol* 1957;**10**:677–89.
16. Hunsuck EE. A modified intraoral sagittal splitting technic for correction of mandibular prognathism. *J Oral Surg* 1968;**26**:250–3.
17. Epker BN. Modifications in the sagittal osteotomy of the mandible. *J Oral Surg* 1977;**35**:157–9.
18. Agbaje JO, Gemels B, Salem AS, et al. Modified mandibular inferior border sagittal split osteotomy reduces postoperative risk for developing inferior border defects. *J Oral Maxillofac Surg* 2016;**74**:1062.e1.e1–9.
19. Agbaje JO, Salem AS, Lambrichts I, et al. Systematic review of the incidence of inferior alveolar nerve injury in bilateral sagittal split osteotomy and the assessment of neurosensory disturbances. *Int J Oral Maxillofac Surg* 2015;**44**:447–51.
20. Colella G, Cannavale R, Vicidomini A, et al. Neurosensory disturbance of the inferior alveolar nerve after bilateral sagittal split osteotomy: a systematic review. *J Oral Maxillofac Surg* 2007;**65**:1707–15.
21. Alolayan AB, Leung YY. Resolution of neurosensory deficit after mandibular orthognathic surgery: A prospective longitudinal study. *J Craniomaxillofacial Surg* 2017;**45**:755–61.
22. Verweij JP, Mensink G, Fiocco M, et al. Incidence and recovery of neurosensory disturbances after bilateral sagittal split osteotomy in different age groups: a retrospective study of 263 patients. *Int J Oral Maxillofac Surg* 2016;**45**:898–903.
23. Wall EJ, Massie JB, Kwan MK, et al. Experimental stretch neuropathy. Changes in nerve conduction under tension. *J Bone Joint Surg* 1992;**74B**:126–9.
24. Borstlap WA, Stoelinga PJW, Hoppenreijns TJM, et al. Stabilisation of sagittal split advancement osteotomies with miniplates: A prospective, multicentre study with two-year follow-up. Part I. Clinical parameters. *Int J Oral Maxillofac Surg* 2004;**33**:433–41.
25. Mensink G, Zweers A, Wolterbeek R, et al. Neurosensory disturbances one year after bilateral sagittal split osteotomy of the mandible performed with separators: A multi-centre prospective study. *J Craniomaxillofacial Surg* 2012;**40**:763–7.
26. Phillips C, Essick G. Inferior alveolar nerve injury following orthognathic surgery: A review of assessment issues. *J Oral Rehabil* 2011;**38**:547–54.