


REVIEW ARTICLE

Evidence in peroneal nerve entrapment: A scoping review

Christophe Oosterbos^{1,2}  | Thomas Decramer^{1,2} | Sofie Rummens^{3,4} | Frank Weyns^{5,6} | Annie Dubuisson⁷ | Jeroen Ceuppens⁸ | Sophie Schuind⁹ | Justus Groen¹⁰ | Johannes van Loon^{1,2} | Lukas Rasulic^{11,12} | Robin Lemmens^{13,14,15} | Tom Theys^{1,2}

¹Research Group Experimental Neurosurgery and Neuroanatomy and Leuven Brain Institute, Catholic University of Leuven, Leuven, Belgium

²Department of Neurosurgery, University Hospitals of Leuven, Leuven, Belgium

³Department of Physical Medicine and Rehabilitation, University Hospitals of Leuven, Leuven, Belgium

⁴Locomotor and Neurological Disorders, Catholic University of Leuven, Leuven, Belgium

⁵Department of Neurosurgery, East Limburg Hospital, Genk, Belgium

⁶Neurosciences, Faculty of Medicine and Life Sciences, Hasselt University, Hasselt, Belgium

⁷Department of Neurosurgery, University Hospitals of Liège, Liège, Belgium

⁸Department of Neurosurgery, Groeninge General Hospital, Kortrijk, Belgium

⁹Department of Neurosurgery, Erasme Hospital, Brussels, Belgium

¹⁰Nerve Centre, University of Leiden, Leiden, the Netherlands

¹¹Faculty of Medicine, University of Belgrade, Belgrade, Serbia

¹²Clinic for Neurosurgery, University Clinical Centre of Serbia, Belgrade, Serbia

¹³Department of Neurosciences, Experimental Neurology, Catholic University of Leuven, Leuven, Belgium

¹⁴Centre for Brain & Disease Research, Laboratory of Neurobiology, VIB, Leuven, Belgium

¹⁵Department of Neurology, University Hospitals of Leuven, Leuven, Belgium

Correspondence

Christophe Oosterbos, Department of Neurosurgery, University Hospitals of Leuven, Herestraat 49, 3000 Leuven, Belgium.

Emails: christopheoosterbos@gmail.com;

christophe.oosterbos@uzleuven.be

Abstract

Background and purpose: Daily management of patients with foot drop due to peroneal nerve entrapment varies between a purely conservative treatment and early surgery, with no high-quality evidence to guide current practice. Electrodiagnostic (EDX) prognostic features and the value of imaging in establishing and supplementing the diagnosis have not been clearly established.

Methods: We performed a literature search in the online databases MEDLINE, Embase, and the Cochrane Library. Of the 42 unique articles meeting the eligibility criteria, 10 discussed diagnostic performance of imaging, 11 reported EDX limits for abnormal values and/or the value of EDX in prognostication, and 26 focused on treatment outcome.

Results: Studies report high sensitivity and specificity of both ultrasound (varying respectively from 47.1% to 91% and from 53% to 100%) and magnetic resonance imaging (MRI; varying respectively from 31% to 100% and from 73% to 100%). One comparative trial favoured ultrasound over MRI. Variable criteria for a conduction block (>20%–≥50) were reported. A motor conduction block and any baseline compound motor action potential response were identified as predictors of good outcome. Based predominantly on case series, the percentage of patients with good outcome ranged 0%–100% after conservative treatment and 40%–100% after neurolysis. No study compared both treatments.

Conclusions: Ultrasound and MRI have good accuracy, and introducing imaging in the standard diagnostic workup should be considered. Further research should focus on the

role of EDX in prognostication. No recommendation on the optimal treatment strategy of peroneal nerve entrapment can be made, warranting future randomized controlled trials.

KEYWORDS

conservative treatment, foot drop, neurolysis, peroneal nerve entrapment, review

INTRODUCTION

Rationale

Peroneal neuropathy is the most common mononeuropathy in the lower limbs [1,2] and a very frequent cause of foot drop [3]. Foot drop causes gait difficulties, leading to an increased risk of falling [4]. Even patients with subclinical peroneal neuropathy are at increased risk of falling [5–7]. The pathology being common, epidemiological data nevertheless are scarce. Studies from Egypt [8,9] found a prevalence of symptomatic peroneal neuropathy of 19–40 per 100,000 inhabitants. Based on these data, 0.6%–1.2% of all neuropathies are peroneal neuropathies. These numbers are contrasted by other authors reporting percentages up to 15%, only partially explained by differences in study methodology [10,11].

The aetiology of peroneal neuropathy is very broad. An important anatomical consideration in disease pathology is the superficial course of the nerve at the level of the fibular head. Here, the nerve dives into the fibular tunnel, defined by the fibular neck, peroneus longus, and soleus muscle, rendering it vulnerable to compression [12,13]. Compression can result from cysts and tumours [14], muscle herniation [15], bracing, tight casts, habitual crossing of the legs, squatting, and kneeling [16]. Peroneal neuropathy is frequently associated with excessive weight loss, as seen after bariatric surgery [2,17–20] or anorexia nervosa [21]. Long-term bedridden patients are also prone to develop peroneal neuropathy [1,22,23]. Peroneal nerve damage can be iatrogenic after surgery of the hip, knee, or ankle, or even after thoracic–abdominal/gynaecological surgery due to patient positioning. Other potential causes are trauma [23–25] and metabolic disorders (e.g., diabetes mellitus, hypothyroidism) [26].

Diagnosis is based on clinical examination and confirmed with electrodiagnostics (EDX). In 2005, a practice parameter was published by the American Association of Neuromuscular & Electrodiagnostic Medicine (AANEM). However, "guidelines" for motor and sensory nerve conduction studies (NCS) were based on Class III evidence, holding a Level C recommendation. Data were insufficient to determine the role of needle electromyography (Level U recommendation, Class IV evidence), and prognostic studies hold only a Level C recommendation based on Class III and IV evidence [27]. No limits of abnormality for motor NCS were defined. A scoping review was conducted to summarize reported limits of abnormality for NCS. Furthermore, evidence for the prognostic value of EDX is mapped.

The role of imaging with dedicated magnetic resonance imaging (MRI) sequences and ultrasound (US) in diagnosing peroneal neuropathy is evolving due to technologic advancements. Articles on imaging in peripheral nerve pathology report a high sensitivity and specificity and a clear added value to EDX, with the ability to localize the lesion, characterize pathologic changes in the nerve and innervated muscles

(MRI) and localize intrinsic and extrinsic masses [28]. Because no synthesis of data on diagnostic performance of MRI and US in peroneal neuropathy is currently available, we summarized the available data.

Given the broad range of causes of peroneal neuropathy, treatment strategies are likely to vary in the different subtypes of peroneal nerve pathology. Peroneal neuropathies can be classified as idiopathic, idiopathic with established risk factors (e.g., leg crossing, squatting, weight loss, kneeling, metabolic disorders, bracing, positioning during surgery), and nonidiopathic peroneal neuropathies (e.g., trauma, iatrogenic, cysts, tumours). The term *peroneal nerve entrapment* will be used to refer to idiopathic peroneal neuropathies with and without established risk factors in this review. The term *peroneal neuropathy* refers to all possible causes.

This scoping review mainly focuses on the controversy around the role of decompressive surgery versus conservative treatment in peroneal nerve entrapment. Current practice varies greatly between (and even within) centres. Treatment is mostly based on the personal experience of the physician and expert opinions. Many centres tend to follow a conservative treatment, whereas other centres tend to operate on these patients after varying time windows.

In the absence of high-level evidence, no guidelines exist on the management of peroneal nerve entrapment. This also limits the potential of conducting a valuable in-depth systematic review with a meta-analysis. Instead, we conducted a scoping review to systematically map and discuss existing data and to identify knowledge gaps to guide further research.

The literature was systematically searched for articles answering one of the following research questions: "Does MRI have a superior diagnostic accuracy in patients with peroneal neuropathy, compared to ultrasound?", "Is electrodiagnostics, in patients with foot drop due to peroneal neuropathy, an added value for prognosticating patient outcome?", "Which limits for abnormality in nerve conduction studies in patients with peroneal neuropathy are defined since AANEM 2005 [27]?", and "Does an adult patient with foot drop (ankle dorsiflexion strength comparable to Medical Research Council [MRC] Muscle Scale grade ≤ 3) due to peroneal nerve entrapment recover better in terms of muscle strength and/or gait difficulties after surgical decompression or any form of conservative treatment?"

METHODS

Protocol and registration

The protocol was drafted using PRISMA-P (Preferred Reporting Items for Systematic Reviews and Meta-Analysis Protocols) [29] by the first author and was revised by the senior authors (R.L. and

T.T.). The final protocol was prospectively registered with the Open Science Framework on 15 March 2021 (<https://osf.io/xrdbv>).

Eligibility criteria

For papers on diagnostic performance of imaging to be included in the review, they needed to focus on sensitivity, specificity, positive and negative predictive value, and/or diagnostic accuracy of MRI and/or US in peroneal neuropathy. Papers comparing diagnostic performance of MRI and US or papers comparing MRI and/or US with clinical or EDX features were eligible as well. Peer-reviewed articles were included if they were published in the past 20 years (after 31 December 2000), were written in English, and included adult patients only and the full-text article was available. Papers were excluded if their design was any of the following: case reports, expert opinions, meeting abstract, posters, and reviews without focus on diagnostic performance. Papers discussing imaging of the peroneal nerve outside the context of peroneal neuropathy were not eligible.

Peer-reviewed articles reporting the prognostic value of EDX and/or NCS limits for abnormal values were included if they were published after the 2005 AANEM practice parameter, criteria for determining abnormality were clearly stated, the EDX protocol was unambiguously established, they were written in English, they included adult patients only, and the full-text article was available. Papers were excluded if their design was any of the following: case reports, expert opinion, meeting abstracts, and posters. If the EDX protocol did not extend beyond a referral to the AANEM practice parameter, or if EDX of the peroneal nerve was conducted outside the context of peroneal neuropathy (e.g., polyneuropathy), papers were not eligible. Papers were not considered for inclusion if they solely discussed intraoperative peroneal nerve monitoring.

Articles on the treatment of peroneal nerve entrapment were included in the review if they provided a clear definition of foot drop and of outcome measures. Only papers discussing neurolysis and/or conservative treatment were considered for inclusion. Peer-reviewed articles were included if they were published after 1970, were written in English, and included adult patients only and full-text was available. Papers were excluded if their design was any of the following: case reports, expert opinions, meeting abstracts, and posters. Papers were excluded if they discussed exclusively nonidiopathic peroneal neuropathies, surgical techniques other than neurolysis, entrapment at a level other than the fibular head, or peroneal nerve entrapment without foot drop (ankle dorsiflexion strength comparable to MRC > 3) or if reliable data extraction on peroneal nerve entrapment was not possible. Papers discussing polyneuropathies, hereditary neuropathies, or critical illness neuropathies were not eligible.

Information sources and search

To identify eligible articles, the following online databases were searched on 16 March 2021: MEDLINE (PubMed), Embase, and

the Cochrane Library. The search strategies were drafted by the first author (C.O.). The final search strategies for all three research questions can be found in the protocol or in Appendix 1. The final search results were exported into EndNote citation manager. Duplicate papers were removed using EndNote and Rayyan for verification [30]. The online database search was supplemented by scanning the reference lists of included papers (snowballing).

Selection of sources of evidence

All unique search results were imported into Rayyan [30] to screen titles and abstracts for eligibility. Keywords linked to inclusion and exclusion criteria were added to Rayyan to aid in selecting abstracts. In case of doubt, the full text was analysed for eligibility. The full text versions of the included abstracts were obtained from the online databases and analysed for eligibility. The selection procedure was done by the first author. In case of doubt, eligibility was discussed within the study team.

Data charting and data items

For all included papers, data were extracted on article characteristics (authors, year of publication, study design, trial objective) and patient characteristics (number of patients, aetiology, age).

The following data on diagnostic performance of imaging were extracted: imaging technique, trial outcome, sensitivity, specificity, diagnostic accuracy, positive and negative predictive values, and correlation with clinical or EDX features including prognostic features.

The following EDX data were extracted: limits for abnormality for conduction block and/or motor nerve conduction velocities, predictors of good outcome, and predictors of bad outcome.

The following outcome data items were extracted (if available): treatment strategy, time to surgery (if applicable), conservative treatment registry (if applicable), length of follow-up, time to recovery, outcome of treatment, outcome 1 year after treatment, and outcome measure (MRC score, other measure of muscle strength, gait analysis, other).

Critical appraisal of individual sources of evidence

EDX studies were evaluated using the criteria for the assessment of the utility of a diagnostic test [27], comparable to the 2005 AANEM guideline. Studies with no (primary) EDX objectives, as well as imaging trials, were evaluated using the Oxford Centre for Evidence-Based Medicine 2011 Levels of Evidence [31]. The methodologic quality of included papers regarding treatment outcome was assessed using the Oxford Centre for Evidence-Based Medicine 2011 Levels of Evidence [31].

RESULTS

Source selection

The online database search for diagnostic performance of imaging in peroneal neuropathy yielded 647 records. After removal of 394 duplicates, we screened 253 records and excluded 215 records based on the abstracts. We evaluated the remaining 38 articles for eligibility and after examination of the full text included 10 articles for analysis in the scoping review. Figure 1 summarizes the study selection.

The online database search for the prognostic value of EDX in peroneal neuropathy and NCS limits for abnormal values yielded 868 records. After removal of 396 duplicates, we screened 472 records and excluded 438 records based on the abstracts. We evaluated the remaining 34 articles for eligibility and after examination of

the full text included 11 articles for analysis in the scoping review. Figure 2 summarizes the study selection.

The online database search for treatment of peroneal nerve entrapment yielded 3865 records. After removal of 1850 duplicates, we screened 2015 records and excluded 1933 records based on the abstracts. We evaluated the remaining 82 articles for eligibility and after examination of the full text included 26 articles for analysis in the scoping review. Figure 3 summarizes the study selection.

Source characteristics and level of evidence

Table 1 summarizes the included studies according to the level of evidence. Overall, data from 1661 unique study subjects were extracted from 42 different papers, predominantly with low level of evidence.

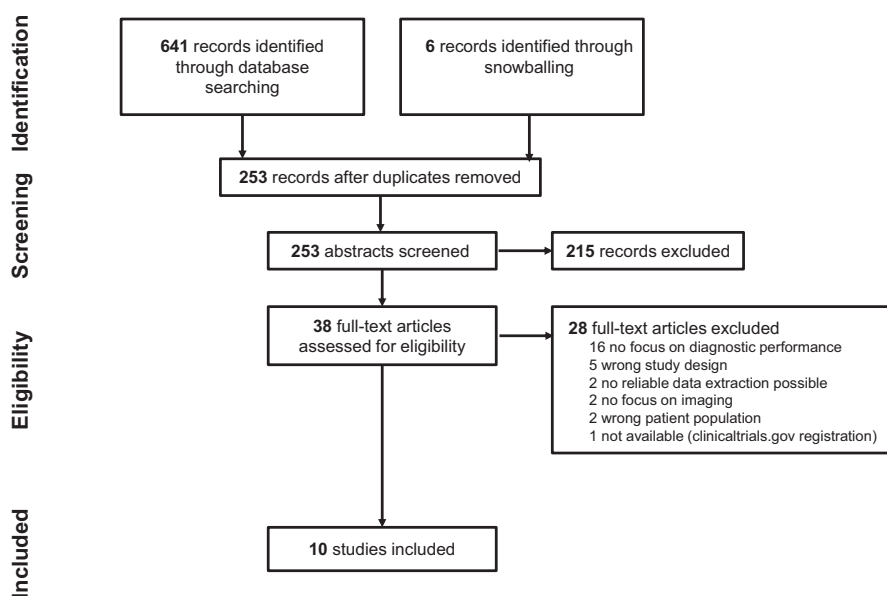


FIGURE 1 Study selection for papers on diagnostic performance of ultrasound and magnetic resonance imaging in peroneal neuropathy

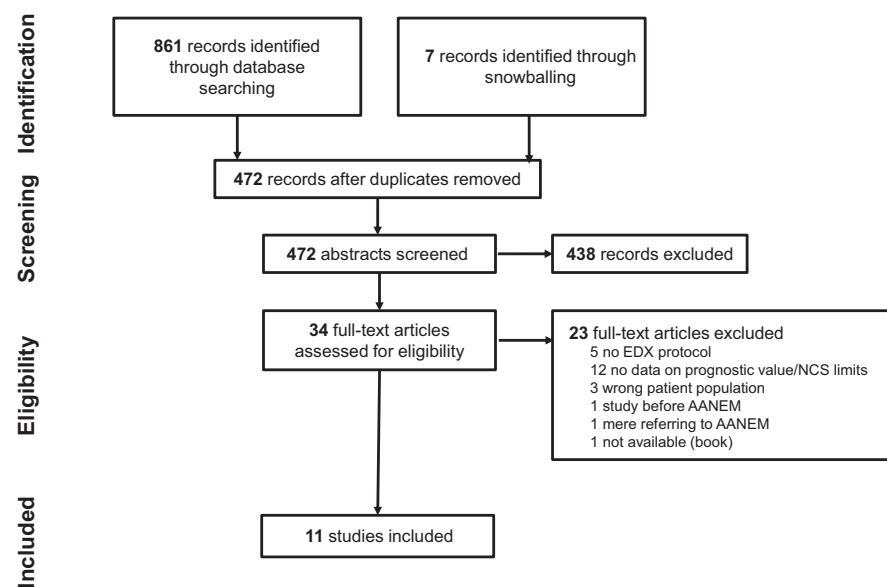
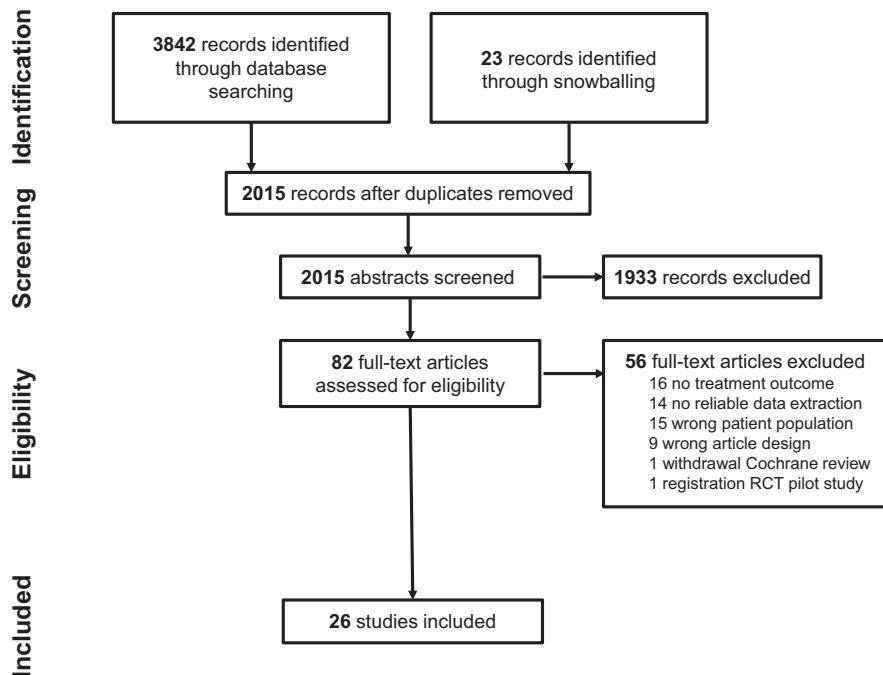


FIGURE 2 Study selection for papers on the prognostic value of electrodiagnostics (EDX) in peroneal neuropathy and papers discussing nerve conduction study (NCS) limits for abnormal values. AANEM, American Association of Neuromuscular & Electrodiagnostic Medicine

FIGURE 3 Study selection for papers on treatment of peroneal nerve entrapment. RCT, randomized controlled trial



One study compared diagnostic performance of US and MRI [32]. Seven papers focused on diagnostic performance of US [32–38], and four papers reported on diagnostic performance of MRI [32,39–41].

We identified 10 studies reporting on criteria for conduction block [16,22,33,36,37,42–46] and six studies stating criteria for slowing of motor nerve conduction velocity [33,36,37,42,43,46]. Five studies [16,22,44,45,47] reported on the prognostic value of EDX in peroneal neuropathy.

All but four papers identified as reporting on treatment of peroneal nerve entrapment were case series [2,10,19,24,45,48–64]. One systematic review on the surgical treatment of peroneal neuropathy, with a variety of surgical techniques and patients, was included [65]. We identified one prospective multicentre follow-up study [66] on conservative treatment of peroneal neuropathy (including peroneal nerve entrapment) and one monocentric follow-up study on surgical treatment of idiopathic peroneal nerve entrapment [67]. One literature review on peroneal nerve entrapment after weight loss included a narrative description of treatment outcome [68]. We found no randomized controlled trials (RCTs) or systematic reviews.

Results of individual sources of evidence

Diagnostic performance of US and MRI

Table 2 gives an overview of the included papers on diagnostic performance of US and MRI.

Assessment of increased cross-sectional area (CSA) of the peroneal nerve, a measurement for the nerve's surface at one specific two-dimensional slice, was routinely performed in all articles on US, reflecting the importance of this diagnostic parameter [69,70]. Even single fascicular involvement can be assessed with CSA

measurements [42]. Studies measured CSA at the level of maximal nerve diameter [32,33,36], at the level of the fibular head [37] or at and above the fibular head [33,34]. Other authors reported CSA ratios [35,38], including CSA measures of the healthy contralateral peroneal nerve [38]. Cutoff values for CSA measures and ratios are summarized in Table 2. Overall reported values for sensitivity and specificity are high, with up to 90% sensitivity [32,33] and 92% specificity [32], if CSA was measured at maximal nerve diameter. Visser et al. [33] reported only a moderate specificity of 69% with CSA measurements at maximal diameter. Here, a cutoff value of $>8 \text{ mm}^2$ was used, instead of $11.5\text{--}12 \text{ mm}^2$ as reported in the other papers [32,36]. Data on the prognostic value of CSA measures is very limited, with one paper [45] reporting no difference in outcome between groups of patients with increased CSA and without increased CSA.

Several authors report on echogenicity of the peroneal nerve [32,34,36]. Increased hypoechogenic areas likely result from pathologic intraneural oedema, and can represent a possible early sign of nerve pathology [34]. Lee et al. calculated the hypoechogenic fraction of the peroneal nerve using three automatic thresholding methods and reported a high sensitivity and specificity [34]. Significant differences in hypoechogenic fractions between patients and healthy controls were reported, with corresponding high values for sensitivity and specificity (see Table 2). Furthermore, 11 patients with suspected peroneal neuropathy had normal CSA measurements, whereas hypoechogenic fraction in all 11 subjects was increased. These findings support the idea that increased hypoechogenicity could be an earlier sign of peroneal neuropathy in comparison to increased CSA.

In addition to morphological changes in the peroneal nerve [32,39] MRI studies also evaluated regionally innervated muscles [39–41]. Reported values for sensitivity and specificity of CSA and

TABLE 1 Mapping of available evidence

	Design level of evidence		Number of included articles [References]	Sample size
Imaging, 10 articles	Systematic review of cross-sectional studies (with blinding and constantly applied reference standards)	1	0	0
	Individual cross-sectional study (with blinding and constantly applied reference standards)	2	3 [32,33,40]	287
	Nonconsecutive study, study without consistently applied reference standards	3	0	0
	Case-control study Case series	4	6 [34,36-39,41] 1 [35]	422
EDX criteria, 11 articles	Prospective study with broad spectrum of subjects with suspected disease with use of gold standard and blinding measures	I	0	0
	Prospective study with narrow spectrum of persons with suspected disease (use of diagnostic gold standard and blinding measures)	II	0	0
	Well-designed retrospective study with large patient group (confirmed using gold standard) and large control group and blinding measures		0	0
	Small retrospective study with either small control group or patient group (use of golden diagnostic standard) and use of blinding measures	III	0	0
	Any design without EDX in blinded setting Descriptive case series	IV	2 [16,37] 5 [43-47]	320
	EDX limits for abnormal values in trial with non-EDX objectives			
	Cross-sectional study Nonrandomized follow-up study Case-control study	2 3 4	1 [33] 1 [22] 2 [36,42]	300
Treatment outcome, 26 articles	Systematic review of randomized controlled trials or number of Level 1 evidence articles	1	0	
	Randomized controlled trial or observational study with dramatic effect	2	0	
	Systematic review of all surgical techniques in peroneal neuropathy	3	1 [65]	
	Poor-quality narrative literature review on peroneal nerve entrapment due to weight loss		1 [68]	189
	Nonrandomized follow-up study		2 [66,67]	
	Case series mostly on surgical treatment		13 [2,19,48-58]	533
	Case series on conservative treatment and/or spontaneous evolution (predominantly)	4	9 [10,24,45,59-64]	

Note: Level of evidence was assessed using the Oxford Centre for Evidence-Based Medicine 2011 Levels of Evidence [31] and the criteria for the assessment of the utility of a diagnostic test [27]. Size of the included study sample is reported.

Abbreviation: EDX, electrodiagnostics.

changes in T2 signal intensity were high [32,39], with up to 87.5% sensitivity and 85% specificity [32]. Diagnostic accuracy of T2 signal intensity was 75% in another study [39]. In two studies, assessment of the pattern of changes in denervated muscles was accurate for all cases of peroneal neuropathy based on signal alterations [40] and gadolinium enhancement [41], a finding that was not confirmed by Lee et al. [39].

One paper, describing a randomized reading protocol, prospectively compared US with MRI in patients with peroneal neuropathy [32]. Diagnostic performance for both imaging modalities was high (see Table 2), but the results favoured US over MRI. However, denervated muscle assessment was not taken into account. Combining US and MRI increased sensitivity up to 94%. A slight decrease of specificity to 84% was observed.

TABLE 2 Diagnostic performance of imaging in peroneal neuropathy

Authors	Imaging	Imaging feature(s)	SENS	SPEC	DA	PPV	NPV
Bayrak et al. [36]	US	CSA maximal diameter (cutoff 11.5 mm ²) Echogenicity	80%	90%	-	-	-
Bignotti et al. [32]	US	CSA maximal diameter (cutoff 12 mm ²) Loss of fascicular echotexture Echogenicity Intrinsic/extrinsic lesions	90%	92%	91.3%	92.3%	90.2%
	MRI	Increased CSA Intrinsic/extrinsic lesion Increased T2 signal hyperintensity	87.5%	85%	86.3%	85.4%	87.2%
	US + MRI	-	94%	84%	-	-	-
Bucklan et al. [35]	US	CSA FH/CSA PF ratio (cutoff 1.25)	51%	71%	-	-	-
Lee et al. [34]	US	CSA (cutoff FH > 11 mm ² , cutoff AFH ≥ 9 mm ²) Hypoechoic fraction with 3 automatic thresholding methods: MaxEntropy (M), RenyiEntropy (R) & Yen (Y)	M _{FH} : 82% R _{FH} : 82% Y _{FH} : 84% M _{AFH} : 91% R _{AFH} : 86% Y _{AFH} : 91%	M _{FH} : 93% R _{FH} : 95% Y _{FH} : 83% M _{AFH} : 91% R _{AFH} : 100% Y _{AFH} : 83%	-	-	-
Lee et al. [39]	MRI	T2 signal intensity (T2)	T2: 77%	T2: 73%	T2: 75%	-	-
		CPN size (S)	S: 54%	S: 100%	S: 79%	-	-
		CPN course (C)	C: 38%	C: 100%	C: 71%	-	-
		CPN fascicular morphology (FM)	FM: 38%	FM: 100%	FM: 71%	-	-
		Regional muscle oedema (ME)	ME: 62%	ME: 93%	ME: 79%	-	-
		Regional muscle fatty infiltration (FI)	FI: 62%	FI: 93%	FI: 79%	-	-
		Regional muscle atrophy (MA)	MA: 31%	MA: 100%	MA: 68%	-	-
		Overall abnormal/normal report (OR)	OR: 77%	OR: 80%	OR: 79%	-	-
Nageeb et al. [37]	US	CSA (cutoff FH 11 mm ²)	83%	53%	-	-	-
Visser et al. [33]	US	CSA maximal diameter (cutoff FH > 8 mm ²)	90%	69%	-	-	-
Kim et al. [38]	US	CSA at FH (cutoff 11.7 mm ²)	CSA _{FH} : 85%	CSA _{FH} : 90%	-	-	-
		CSA ΔSx-Asx (cutoff 1.70 mm ²)	CSA _{ΔSx-Asx} : 83.3%	CSA _{ΔSx-Asx} : 97%	-	-	-
		CSA FH/PF ratio (1.11)	CSA _{FH/PF} : 47.1%	CSA _{FH/PF} : 93.3%	-	-	-
		CSA Sx/Asx ratio (cutoff 1.24)	CSA _{Sx/Asx} : 72.2%	CSA _{Sx/Asx} : 96.7%	-	-	-
Bendszus et al. [40]	MRI	Muscle denervation pattern (T1 and TIRM)	100%	100%	100%	100%	100%

Abbreviations: AFH, above fibular head; CPN, common peroneal nerve; CSA, cross-sectional area; DA, diagnostic accuracy; FH, fibular head; MRI, magnetic resonance imaging; NPV, negative predictive value; PF, popliteal fossa; PPV, positive predictive value; SENS, sensitivity; SPEC, specificity; Sx/Asx ratio, ratio of CSA at the FH of symptomatic side over asymptomatic side; TIRM, turbo inversion recovery magnitude sequences; US, ultrasound; ΔSx-Asx, difference in CSA at the FH between symptomatic and asymptomatic side.

EDX thresholds for abnormal values

In 2020, a review of existing guidelines of EDX testing was published [71]. The review mainly cited the 2005 AANEM practice parameter [27], without introducing (major) alterations to the established "guidelines." No additional data on prognostication were provided. We identified only low level evidence papers (see Table 1). Table 3 summarizes all EDX data included in this scoping review.

A threshold value for conduction block, a drop in compound motor action potential (CMAP) amplitude across the fibular head, was defined in 10 papers. Reported threshold values varied between series, ranging from >20% [16,36,46] to ≥50% [22,37,43,44].

Marciniak [16] reported a 99% specificity of localizing the lesion at the level of the knee if a conduction block of >20% was observed. Criteria for slowing of motor nerve conduction velocity were more consistently reported; two articles [37,43] considered a velocity < 40 m/s pathological, and three papers [33,36,42] used 44 m/s as the cutoff. A decrement of motor velocity > 10 m/s was considered abnormal in three papers [37,43,46].

Five studies [16,22,44,45,47] reported the prognostic value of EDX features. Three papers identified the presence of a pure conduction block as a predictor of good outcome [22,44,45]. Marciniak [16] found the CMAP remaining present to be a predictor of good outcome (MRC ankle dorsiflexion ≥ 4), a finding confirmed by Derr

TABLE 3 Nerve conduction study limits for abnormal values and electrodiagnostic predictors of good and bad outcome in peroneal neuropathy

Authors	Conduction block	Motor nerve conduction velocity across FH	Predictors of good outcome?	Predictors of bad outcome?
Bayrak et al. [36]	>20%	Absolute slowing < 44 m/s	N/A	N/A
Bignotti et al. [42]	≥25%	Slowing < 44 m/s	N/A	N/A
Derr et al. [47]	N/A	N/A	Baseline (TA or EDB) CMAP response Baseline TA motor unit recruitment	No
Kang et al. [43]	≥50%	Velocity decrement > 10 m/s Slowing < 40 m/s (lower leg segment, >44 m/s)	N/A	N/A
Nageeb et al. [37]	≥50%	Velocity decrement > 10 m/s Slowing < 40 m/s (lower leg segment, >44 m/s)	N/A	N/A
Tsukamoto et al. [44]	>50%	N/A	Presence of pure conduction block	N/A
Visser et al. [33]	≥25%	Slowing < 44 m/s	N/A	N/A
Aprile et al. [22]	>50%	Slowing compared to age-specific normal values	Presence of pure conduction block	N/A
Marciniak [16]	>20%	N/A	Baseline CMAP response	
Bsteh et al. [45]	>33%	N/A	Presence of pure conduction block	Acute denervation
Kwon et al. [46]	>20%	Velocity decrement > 10 m/s	N/A	N/A

Note: A conduction block is defined as a drop in CMAP amplitude across the FH.

Abbreviations: CMAP, compound motor action potential; EDB, extensor digitorum brevis muscle; FH, fibular head; N/A, not available; TA, tibialis anterior muscle.

et al. [47], as 81% of patients with a (tibialis anterior [TA] or extensor digitorum brevis [EDB]) CMAP response at baseline recovered (MRC ankle dorsiflexion ≥4) within 3 months. However, an absent CMAP does not equal bad outcome, as 46% of patients with absent TA CMAP and 52% of patients with absent EDB CMAP still reported good outcomes. If the EDB CMAP response was absent, the presence or absence of any TA CMAP response respectively improved or worsened outcome. Finally, 55% of patients with TA motor unit recruitment at baseline had good outcome.

Treatment of peroneal nerve entrapment

Tables 4 and 5 give an overview of the included papers on conservative and/or surgical treatment of peroneal nerve entrapment.

Overall, we evaluated outcome data in 722 subjects. Frequently, case series described a heterogeneous patient sample, complicating reliable data extraction. The number of patients with reliable data extraction on peroneal nerve entrapment was often low, varying between two and 200 in the case series. One systematic review on surgical treatment of 1577 patients with peroneal neuropathy included 128 cases of peroneal nerve entrapment [65]. We identified only two studies with a clear prospective study design. One multicentre prospective follow-up study on 69 patients with peroneal neuropathy reported outcome of 34 conservatively managed patients with

peroneal nerve entrapment [66]. One surgical prospective follow-up study reported outcome of 15 patients with idiopathic entrapment [67].

Recovery was most often defined in terms of muscle strength, with 18 articles [2,24,45,50–56,58,61–67] reporting muscle strength according to the MRC scale and five studies using other scales [10,48,49,57,59] including the Louisiana State University muscle grading system for peroneal nerve injuries [48,49]. Three articles described (motor) symptom resolution [19,60,68], one additionally described gait improvement using the deambulation index [66] and one reported the absence of gait difficulties [24]. The percentage of patients with good outcome varied between 40% and 100% for surgically treated patients and between 0% and 100% for conservatively treated patients. Additionally, five surgical papers reported recovery of sensory changes, ranging from 55.3% to 76% in four retrospective series [2,50,52,58]. One prospective follow-up study [67] reported normal light touch, pinprick, and thermal sensation in respectively 66.78%, 42.9%, and 60% of affected patients.

Length of follow-up differed substantially, not only between, but even within surgical series (where follow-up could range from 2 months to 5 years) [52]. Length of follow-up in conservative series also differed between and within included papers, ranging from 3 months to 3 years, even within the same case series [24]. Outcome of neurolysis at 1-year follow-up is limited to one nonrandomized

TABLE 4 Surgical treatment of peroneal nerve entrapment

Authors	Pat _T	Pat _{PNE}	Etio _{PNE}	Age _{mean}	Outcome measure	% good outcome	Time _{SURG}	Time _{REC}	Follow-up _{mean}
George & Boyce [65]	1577	128	Entrapment (128)	32	Ankle dorsiflexion strength (MRC ≥ 4)	85.2%	19.8 months	N/A	31 months
Tarabay et al. [67]	15	14	Idiopathic (15)	55	Ankle dorsiflexion strength (MRC ≥ 4)	85.7%	25.7 days	1 month (median)	12 months
Broekx & Weyns [2]	200	200	Weight loss (200)	55.6	Ankle dorsiflexion strength (MRC ≥ 4)	85%	4 months	83 days	N/A
Enamhadi et al. [48]	36	2	Entrapment (2)	N/A	Ankle dorsiflexion strength (comparable to MRC ≥ 4)	100%	N/A	N/A	20 months
Fares et al. [68]	21	12	Weight loss (12)	N/A	Normal motor strength	100%	N/A	N/A	N/A
Kim & Kline [49]	276	17	Entrapment (17)	N/A	Ankle dorsiflexion and eversion strength (comparable to MRC ≥ 4)	91.4%	12–24 months	12–16 months	30 months
Maalla et al. [50]	15	8	Idiopathic or prolonged squatting (10)	33	Ankle dorsiflexion strength (comparable to MRC ≥ 4)	87.5%	8 months	N/A	46 months
Nirenberg [51]	21	17	Entrapment (17)	48.5	Hallux extension strength (MRC ≥ 4)	41.20%	N/A	17/21 some improvement in first week	Minimum 4 months
Ramanan & Chandran [52]	20	10	Idiopathic (10)	58	Ankle dorsiflexion strength (MRC ≥ 4)	40%	11 months	N/A	2–60 months
Sipahioğlu et al. [61]	16	2	Prolonged squatting (2)	23.7	Normal motor strength	100%	12 weeks	N/A	1 year
Solmaz et al. [53]	30	29	Idiopathic (2) Positional (1) Dynamic (26)	32.7	Ankle dorsiflexion strength (MRC ≥ 4)	86.2%	5 months	N/A	14 months
Weyns et al. [19]	9	9	Weight loss (9)	38	Normal motor strength	100%	N/A	N/A	N/A
Wilson et al. [54]	21	14	Idiopathic (14)	56.4	Improvement of motor strength	71.3%	13.1 months	1 month (median)	29 months (median)
Yasar [55]	16	2	Idiopathic (2)	49.6	Ankle dorsiflexion strength (MRC ≥ 4)	100%	N/A	30 days	N/A
Lale et al. [56]	9	9	Weight loss (9)	35.5	Normal motor strength	100%	9 days	30 days (median)	Maximum 60 days
Fabre et al. [58]	60	38	Idiopathic (32) Postural (5) Dynamic (1)	51	Ankle dorsiflexion strength (MRC ≥ 4)	87%	14 months	2.5 months	42 months
Vastamäki [57]	24	10	Idiopathic (5) Kneeling (3) Leg crossing (1) Dynamic (1)	41.8	Normal motor strength	90%	9.92 months	N/A	6.2 months
Cruz-Martinez et al. [10]	30	1	Weight loss (1)	27.6	Ankle dorsiflexion strength (comparable to MRC ≥ 4)	100%	6 months	2 weeks	N/A

Abbreviations: Age_{mean}, mean age in years; Etio_{PNE}, etiology of included peroneal neuropathy; Follow-up_{mean}, mean follow-up (unless otherwise specified); MRC, Medical Research Council; N/A, not available; Pat_{PNE}, number of eligible patients with peroneal nerve entrapment and possibility for reliable data extraction on surgical treatment; Pat_T, total number of included patients; Time_{REC}, average time to recovery (unless otherwise specified); Time_{SURG}, average time to surgery (unless otherwise specified).

TABLE 5 Conservative treatment of peroneal nerve entrapment

Authors	Pat _T	Pat _{PNE}	Etio _{PN}	Age _{mean}	Type of treatment	Outcome measure	% good outcome	Time _{REC}	Follow-up _{mean}
Aprile et al. [66]	69	34	Postural (11) Idiopathic (9) Weight loss (6) Bedridden (5) Tight cast (3)	48.4	Muscle strengthening Muscle stretching Gait rehabilitation No treatment	Improvement of ankle dorsiflexion	79%	N/A	6 months
Bai [59]	24	24	Prolonged squatting (14) Idiopathic (10)	N/A	Acupuncture	Normal motor strength	100%	Maximum 46 days	Maximum 46 days
Bsteh et al. [45]	83	25	Postural (?) Idiopathic (?)	54	Not specified	Ankle dorsiflexion strength (MRC \geq 4)	88%	N/A	9.3 months
Fares et al. [68]	21	3	Weight loss (3)	N/A	1 not specified 2 spontaneous	Normal motor strength	100%	N/A	N/A
Kim & Kline [49]	276	4	Entrapment (4)	N/A	Not specified	Ankle dorsiflexion and eversion strength (comparable to MRC \geq 4)	25%	N/A	30 months
Singhal et al. [60]	7	7	Weight loss + perioperative positioning + metabolic (7)	48.6	Physiotherapy Diet Vitamins	Normal motor strength	100%	6 months	N/A
Sipahioglu et al. [64]	16	14	Prolonged squatting (14)	23.7	Rest + stop squats Foot-ankle orthosis Physiotherapy	Normal motor strength	87.5%	3-16 weeks	7.4 weeks
Tarabay et al. [67]	15	1	Idiopathic (1)	55	Not specified	Ankle dorsiflexion strength (MRC \geq 4)	0%	N/A	1 year
Yu et al. [62]	26	20	Postural (20)	54	Not specified	Improvement of motor strength	100%	2-12 weeks	3-36 weeks
Aprile et al. [24]	36	14	Postural (5) Idiopathic (3) Bedridden (3) Chalk positioning (2) Weight loss (1)	46.1	Not specified	Normal clinical investigation and/or no gait abnormalities during telephone interview	71.4%	N/A	3-36 months
Berry & Richardson [63]	70	5	Idiopathic (4) Postural (1)	40.2	Not specified	Ankle dorsiflexion strength (comparable to MRC \geq 4)	60%	N/A	Maximum 1 year
Cruz-Martinez et al. [10]	30	30	Weight loss + postural (22) Weight loss (8)	27.6	Not specified or no treatment	Ankle dorsiflexion strength (comparable to MRC \geq 4)	96.7%	3 weeks to 3.5 months	Maximum 6 months
Sangwan et al. [64]	30	25	Prolonged squatting (25)	33.1	Rest + stop squats Foot-ankle orthosis Physiotherapy	Normal motor strength	100%	5.44 weeks	28.2 months

Abbreviations: Age_{mean}, mean age in years; Etio_{PN}, etiology of included peroneal neuropathy; Follow-up_{mean}, mean follow-up (unless otherwise specified); MRC, Medical Research Council; N/A, not available; Pat_{PNE}, number of eligible patients with peroneal nerve entrapment and possibility for reliable data extraction on conservative treatment; Pat_T, total number of included patients; Time_{REC}, average time to recovery (unless otherwise specified).

follow-up study [67] recording improvement of ankle dorsiflexion in 13 of 14 patients (92.9%) and an MRC score ≥ 4 in 85.7% of patients, with half of the patients having normal ankle dorsiflexion. Outcome of conservative treatment at 1-year follow-up was retrospectively reported by Yu et al. [62], who documented an MRC score of 5 in 76.9% of 26 patients with postural peroneal nerve entrapment. However, this study included six patients without a true foot drop (i.e., with MRC score > 3).

Time to recovery was not consistently defined and reported. Five articles on conservative [10,59,61,62,64] treatment and seven articles [2,51,54–56,58,67] on outcome after neurolysis reported recovery (or improvement of muscle strength) within the first weeks to months. In a monocentric, surgical follow-up study, the median MRC equalled 4 at 1 month [67]. Aprile et al. [66] reported improvement of motor function in 79% of patients at 6 months in their multicentre follow-up study on conservative treatment. In the largest retrospective series of Broekx and Weyns [2], average time to recovery was 83 days after neurolysis. Data on outcome of neurolysis after failure of conservative treatment are anecdotal, with two studies [10,61] reporting good outcome in three patients.

Eleven papers focussing on outcome after neurolysis reported time to surgery. Average time to surgery varied between studies, ranging from 9 days to 19.8 months [2,50,52–54,56–58,65,67]. Average time to surgery (for all 460 patients) equalled 9.7 months. Kim et al. [49] reported time to recovery as a range between 1 and 2 years after symptom onset. Some authors promoted neurolysis as soon as possible after diagnosis [56,67], or at a very early stage [2,50,53,57]. Fabre et al. advocate decompressing the nerve if there is no recovery after a period of 2–4 months [58]. Considering surgery only after failure of months of conservative therapy is supported by several authors (who did not meet the inclusion criteria for this scoping review) [1,72–76]. Wilson et al. [54] performed a meta-analysis to identify predictors of outcome for their dataset and an additional 115 patients with peroneal neuropathy (idiopathic and nonidiopathic) from previous papers. Patients who underwent surgery after 12 months had poorer outcomes, a phenomenon that was not seen at 6 months. A paper by Ramanan and Chandran [52] considered surgery within 12 months of onset of symptoms to be useful based on their retrospective results in 20 patients.

Literature discussing predictors of good and bad outcome is scarce and mostly limited to case series [2,45,58,61,77,78]. Apart from these case series, we identified one meta-analysis on predictors of favourable and unfavourable surgical outcome in peroneal neuropathy [54] and one multicentre prospective study on conservative treatment [66]. In general, a postural peroneal neuropathy was considered prognostic of favourable outcome by several authors [45,58,61,77,78], with complete recovery in 80% [58] to 100% [77,78] of conservatively treated patients. Aprile et al. [66] found that patients with a subacute onset of foot drop scored significantly higher on mental aspects of quality of life. Identified predictors of bad outcome are an associated polyneuropathy [58,77], alcohol abuse [58,77], diabetes [66] and smoking [54].

DISCUSSION

Summary of evidence

Based on our review, we can conclude that the diagnostic performance of both US and MRI is high. Measurement of increased CSA with US is routinely performed and has proven to be efficient, with up to 90% sensitivity [32,33] and 92% specificity [32], if CSA is measured at maximal nerve diameter. Calculation of the increased hypoechogenic fraction shows promising results as an early marker of peroneal neuropathy [34]. Apart from an evaluation of the peroneal nerve with high sensitivity (up to 87.5%) and high specificity (85%) [32], MRI has a distinct potential for additional regional denervated muscle assessment. One paper directly compared MRI and US in peroneal neuropathy, with results preferring US [32].

Threshold values for the presence of a conduction block ranged from $>20\%$ [37,43] to $\geq 50\%$ [22,37,43,44]. Criteria for slowing of motor nerve conduction velocity are more uniformly reported around <40 m/s [37,43] to <44 m/s [33,36,42], or as a velocity decrement across the fibular head of >10 m/s [37,43,46]. Differences in reported thresholds for motor nerve conduction velocities are largely explained by differences in measuring techniques, patient positioning, and the use of different equipment and are therefore to be expected. The absence of a clear definition of a conduction block, however, can possibly induce interobserver variability in diagnosing peroneal neuropathy. Literature remains scarce regarding the prognostic value of EDX measures. The presence of a pure motor conduction block [22,44,45] and the presence of a baseline CMAP response [16,47] were identified as predictors of good outcome by more than one author.

We identified 26 articles discussing surgical or conservative outcome of peroneal nerve entrapment in a total of 722 subjects with foot drop. Our findings indicate a paucity of high-level evidence, as most studies included were case series, frequently retrospective in nature. Although peroneal nerve entrapment represents the most common neuropathy in the lower limbs, not a single study comparing surgical versus conservative treatment in a prospective manner was identified. Treatment guidelines are currently not available.

Based on the current literature, the percentage of patients with good outcome varies from 0 to 100% for conservatively treated patients and from 40% to 100% after surgery. Outcome of surgical treatment was extracted from 18 papers [2,10,19,48–58,61,65,67,68] including one systematic review of different surgical techniques in the treatment of peroneal neuropathy [65] one prospective follow-up study [67] and one large retrospective case series of 200 patients [2], all reporting good outcome in around 85% of patients. Outcome of conservative treatment was extracted from 13 papers [10,24,45,49,59–64,66–68], including one multicentre, prospective follow-up study reporting improvement of ankle dorsiflexion in 79% of patients at 6 months [66]. The reported lower limits of good outcome (0%, 25%) originated from surgical papers, discussing conservative treatment in only one to four patients [49,67]. To our knowledge, this represents the first scoping review, summarizing treatment results in patients with foot drop due to peroneal nerve entrapment.

Limitations

EDX testing is considered the gold standard for diagnosing peroneal neuropathy. Given the high sensitivity and specificity of US and MRI, additional imaging seems warranted for all patients with peroneal neuropathy. Based on the reported results, US can be recommended as an efficient first additional investigation, with supplementary MRI assessing muscle denervation in selected cases.

Several methodological issues were identified, when reviewing the available literature on the diagnostic and treatment modalities for peroneal neuropathy. The lack of prospective studies on this topic is remarkable, as most of the patient series on both the conservative and surgical treatment are retrospective in nature. Most patient series are very heterogeneous, as patients with nonidiopathic peroneal neuropathy were often included, which makes it difficult to draw conclusions on the clinical management. The overall number of patients in the reported studies was generally low. Good outcome was not uniformly defined and duration of follow-up differed, not only between but even within studies. For the aforementioned reasons, a meta-analysis of the included trials was not meaningful.

There is also no consensus on the timing of surgery among those authors who favour surgery. Reported average time to surgery varied from 9 days to 19.8 months [2,50,52–54,56–58,65,67]. Even within the same series, time to surgery could vary from 1 to 60 months [52]. Based on data of 460 patients, average time to surgery equalled 9.7 months. However, several authors advocate an early release [2,50,53,56,57,67] which might conflict with the good outcome described after conservative treatment within several months [10,61,64]. An initial conservative approach seems warranted, but again, no good data exist on the long-term prognosis after conservative treatment.

An RCT is warranted to guide management strategies in patients with foot drop due to peroneal nerve entrapment. One ongoing RCT, the FOOTDROP trial (clinicaltrials.gov number NCT04695834), was identified. The FOOTDROP trial randomizes patients with a persisting foot drop (MRC for ankle dorsiflexion \leq 3) after 6–14 weeks between maximal conservative treatment and operative decompression (neurolysis) of the peroneal nerve. The primary endpoint is the difference in distance covered during the 6-min walk test between randomization and 9 months after randomization. A feasibility pilot study is currently enrolling patients at six centres in Belgium and the Netherlands. No other ongoing research was identified.

The current study is methodologically limited by using slightly different eligibility criteria for each research question, decreasing overall uniformity of the results.

CONCLUSIONS

Presence of a pure motor conduction block and presence of any baseline CMAP response are established as predictors of good outcome by several authors in low level evidence papers. Further research should be dedicated to establishing the role of EDX in

providing prognostic information. US and MRI have good accuracy, and introducing imaging into the standard diagnostic workup should be explored to further increase diagnostic performance. US is recommended as a cost-effective first-line investigation. Further research comparing MRI and US could be useful to establish clear indications for additional MRI.

We can conclude that the current literature lacks good data to recommend either a conservative or an operative treatment for peroneal nerve entrapment. Current practice is based on habits, beliefs, and experience rather than on evidence. A prospective RCT is mandatory to establish future treatment guidelines.

CONFLICT OF INTEREST

None of the authors has any conflict of interest to disclose.

AUTHOR CONTRIBUTIONS

Christophe Oosterbos: Conceptualization (lead), data curation (lead), formal analysis (lead), methodology (lead), project administration (lead), visualization (lead), writing–original draft (lead), writing–review & editing (lead). **Thomas Decramer:** Methodology (supporting), supervision (supporting), writing–original draft (supporting), writing–review & editing (supporting). **Sofie Rummens:** Methodology (supporting), supervision (supporting), validation (supporting), writing–original draft (supporting), writing–review & editing (supporting). **Frank Weyns:** Supervision (supporting), writing–original draft (supporting), writing–review & editing (supporting). **Annie Dubuisson:** Supervision (supporting), writing–original draft (supporting), writing–review & editing (supporting). **Jeroen Ceuppens:** Supervision (supporting), writing–original draft (supporting), writing–review & editing (supporting). **Sophie Schuind:** Supervision (supporting), writing–original draft (supporting), writing–review & editing (supporting). **Justus Groen:** Supervision (supporting), writing–original draft (supporting), writing–review & editing (supporting). **Johannes van Loon:** Supervision (supporting), writing–original draft (supporting), writing–review & editing (supporting). **Lukas Rasulic:** Supervision (supporting), writing–original draft (supporting), writing–review & editing (supporting). **Robin Lemmens:** Conceptualization (supporting), formal analysis (supporting), methodology (supporting), project administration (supporting), supervision (lead), validation (lead), writing–original draft (supporting), writing–review & editing (supporting). **Tom Theys:** Conceptualization (supporting), formal analysis (supporting), methodology (supporting), project administration (supporting), supervision (lead), validation (lead), writing–original draft (supporting), writing–review & editing (supporting).

DATA AVAILABILITY STATEMENT

The authors confirm that the data supporting the findings of this study are available within the article [and/or] its supplementary materials.

ORCID

Christophe Oosterbos  <https://orcid.org/0000-0003-2142-9941>

REFERENCES

1. Poage C, Roth C, Scott B. Peroneal nerve palsy: evaluation and management. *J Am Acad Orthop Surg*. 2016;24(1):1-10.
2. Broeckx S, Weyns F. External neurolysis as a treatment for foot drop secondary to weight loss: a retrospective analysis of 200 cases. *Acta Neurochir (Wien)*. 2018;160(9):1847-1856.
3. Carolus A, Mesbah D, Brenke C. Focusing on foot drop: results from a patient survey and clinical examination. *Foot (Edinb)*. 2021;46:101693.
4. Stewart JD. Foot drop: where, why and what to do? *Pract Neurol*. 2008;8(3):158-169.
5. Poppler LH, Bansal A, Groves A, Sacks G, Davidge K, Mackinnon SE. Abstract 65: subclinical peroneal nerve entrapment may be an under-recognized cause of falls in hospitalized patients. *Plast Reconstr Surg*. 2014;133:76.
6. Poppler LH, Yu J, Mackinnon SE. Subclinical peroneal neuropathy affects ambulatory, community-dwelling adults and is associated with falling. *Plast Reconstr Surg*. 2020;145(4):769e-e778.
7. Poppler LH, Groves AP, Sacks G, et al. Subclinical peroneal neuropathy: a common, unrecognized, and preventable finding associated with a recent history of falling in hospitalized patients. *Ann Fam Med*. 2016;14(6):526-533.
8. Khedr EM, Fawi G, Allah Abbas MA, El-Fetoh NA, Zaki AF, Gamea A. Prevalence of common types of compression neuropathies in Qena Governorate/Egypt: a population-based survey. *Neuroepidemiology*. 2016;46(4):253-260.
9. Kandil MR, Darwish ES, Khedr EM, Sabry MM, Abdulah MA. A community-based epidemiological study of peripheral neuropathies in Assiut. *Egypt. Neurol Res*. 2012;34(10):960-966.
10. Cruz-Martinez A, Arpa J, Palau F. Peroneal neuropathy after weight loss. *J Peripher Nerv Syst*. 2000;5(2):101-105.
11. Shahar E, Landau E, Genizi J. Adolescence peroneal neuropathy associated with rapid marked weight reduction: case report and literature review. *Eur J Paediatr Neurol*. 2007;11(1):50-54.
12. Gloobe H, Chain D. Fibular fibrous arch. Anatomical considerations in fibular tunnel syndrome. *Acta Anat (Basel)*. 1973;85(1):84-87.
13. Ryan W, Mahony N, Delaney M, O'Brien M, Murray P. Relationship of the common peroneal nerve and its branches to the head and neck of the fibula. *Clin Anat*. 2003;16(6):501-505.
14. Weyns F, Bringmans T, Vandevenne J, et al. Peripheral neuropathy caused by joint-related cysts: a review of 17 cases. *Acta Neurochir*. 2012;154(10):1741-1753.
15. Tong O, Bieri P, Herskovitz S. Nerve entrapments related to muscle herniation. *Muscle Nerve*. 2019;60(4):428-433.
16. Marciniak C. Fibular (peroneal) neuropathy: electrodiagnostic features and clinical correlates. *Phys Med Rehabil Clin N Am*. 2013;24(1):121-137.
17. Elias WJ, Pouratian N, Oskouian RJ, Schirmer B, Burns T. Peroneal neuropathy following successful bariatric surgery. Case report and review of the literature. *J Neurosurg*. 2006;105(4):631-635.
18. Sen O, Karaca FC, Turkcapar A. Neurological complication after laparoscopic sleeve gastrectomy: foot drop. *Obes Surg*. 2020;30(3):957-960.
19. Weyns FJ, Beckers F, Vanormelingen L, Vandersteen M, Niville E. Foot drop as a complication of weight loss after bariatric surgery: is it preventable? *Obes Surg*. 2007;17(9):1209-1212.
20. Meylaerts L, Cardinaels E, Vandevenne J, et al. Peroneal neuropathy after weight loss: a high-resolution ultrasonographic characterization of the common peroneal nerve. *Skeletal Radiol*. 2011;40(12):1557-1562.
21. Lutte I, Rhys C, Hubert C, et al. Peroneal nerve palsy in anorexia nervosa. *Acta Neurol Belg*. 1997;97(4):251-254.
22. Aprile I, Caliendo P, La Torre G, et al. Multicenter study of peroneal mononeuropathy: clinical, neurophysiologic, and quality of life assessment. *J Peripher Nerv Syst*. 2005;10(3):259-268.
23. Bowley MP, Doughty CT. Entrapment neuropathies of the lower extremity. *Med Clin North Am*. 2019;103(2):371-382.
24. Aprile I, Padua L, Padua R, et al. Peroneal mononeuropathy: predisposing factors, and clinical and neurophysiological relationships. *Neurol Sci*. 2000;21(6):367-371.
25. Pattyn R, Loder R, Mullis BH. Iatrogenic peroneal nerve palsy rates secondary to open reduction internal fixation for Tibial Plateau fractures using an intraoperative distractor. *J Orthop Trauma*. 2020;34(7):359-362.
26. Farhad K, Traub R, Ruzhansky KM, Brannagan TH 3rd. Causes of neuropathy in patients referred as "idiopathic neuropathy". *Muscle Nerve*. 2016;53(6):856-861.
27. Marciniak C, Armon C, Wilson J, Miller R. Practice parameter: Utility of electrodiagnostic techniques in evaluating patients with suspected peroneal neuropathy: an evidence-based review. *Muscle Nerve*. 2005;31(4):520-527.
28. Agarwal A, Chandra A, Jaipal U, et al. Can imaging be the new yardstick for diagnosing peripheral neuropathy?—a comparison between high resolution ultrasound and MR neurography with an approach to diagnosis. *Insights Imaging*. 2019;10(1):104.
29. Shamseer L, Moher D, Clarke M, et al. Preferred reporting items for systematic review and meta-analysis protocols (PRISMA-P) 2015: elaboration and explanation. *BMJ*. 2015;350:g7647.
30. Ouzzani M, Hammady H, Fedorowicz Z, Elmagarmid A. Rayyan—a web and mobile app for systematic reviews. *Syst Rev*. 2016;5(1):210.
31. Howick J, Chalmers L, Glasziou P, et al. *OCEBM Levels of Evidence Working Group. "The Oxford 2011 Levels of Evidence" 2011*. Oxford Centre for Evidence-Based Medicine. <http://www.cebm.net/index.aspx?o=5653>
32. Bignotti B, Assini A, Signori A, Martinoli C, Tagliafico A. Ultrasound versus MRI in common fibular neuropathy. *Muscle Nerve*. 2017;55(6):849-857.
33. Visser LH, Hens V, Soethout M, De Deugd-Maria V, Pijnenburg J, Brekelmans GJ. Diagnostic value of high-resolution sonography in common fibular neuropathy at the fibular head. *Muscle Nerve*. 2013;48(2):171-178.
34. Lee H, Brekelmans GJF, Visser LH. Quantitative assessment of nerve echogenicity as an additional tool for evaluation of common fibular neuropathy. *Clin Neurophysiol*. 2016;127(1):874-879.
35. Bucklan JN, Morren JA, Shook SJ. Ultrasound in the diagnosis and management of fibular mononeuropathy. *Muscle Nerve*. 2019;60(5):544-548.
36. Bayrak İK, Oytun Bayrak A, Türker H, Akpınar ÇK, Bolat N. Diagnostic value of ultrasonography in peroneal neuropathy. *Turk J Med Sci*. 2018;48(6):1115-1120.
37. Nageeb RS, Mohamed WS, Nageeb GS, Desoky EA, Azmy TM. Role of superficial peroneal sensory potential and high-resolution ultrasonography in confirmation of common peroneal mononeuropathy at the fibular neck. *Egypt J Neurol Psychiatry Neurosurg*. 2019;55(1):1-8.
38. Kim JY, Song S, Park HJ, Rhee WI, Won SJ. Diagnostic cutoff value for ultrasonography of the common fibular neuropathy at the fibular head. *Ann Rehabil Med*. 2016;40(6):1057-1063.
39. Lee PP, Chalian M, Bizzell C, et al. Magnetic resonance neurography of common peroneal (fibular) neuropathy. *J Comput Assist Tomogr*. 2012;36(4):455-461.
40. Bendszus M, Wessig C, Reiners K, Bartsch AJ, Solymosi L, Koltzenberg M. MR imaging in the differential diagnosis of neurogenic foot drop. *AJNR Am J Neuroradiol*. 2003;24(7):1283-1289.
41. Bendszus M, Koltzenberg M. Visualization of denervated muscle by gadolinium-enhanced MRI. *Neurology*. 2001;57(9):1709-1711.
42. Bignotti B, Cadoni A, Assini A, Martinoli C, Tagliafico A. Fascicular involvement in common fibular neuropathy: evaluation with ultrasound. *Muscle Nerve*. 2016;53(4):532-537.
43. Kang PB, Preston DC, Raynor EM. Involvement of superficial peroneal sensory nerve in common peroneal neuropathy. *Muscle Nerve*. 2005;31(6):725-729.

44. Tsukamoto H, Granata G, Coraci D, Paolasso I, Padua L. Ultrasound and neurophysiological correlation in common fibular nerve conduction block at fibular head. *Clin Neurophysiol.* 2014;125(7):1491-1495.
45. Bsteh G, Löscher WN, Gruber H, Seppi K, Wanschitz JV. Prognosis and prognostic factors in non-traumatic acute-onset compressive mononeuropathies: radial and peroneal mononeuropathies. *J Peripher Nerv Syst.* 2013;18:S14-S15.
46. Kwon HK, Kim L, Park YK. Compound nerve action potential of common peroneal nerve and sural nerve action potential in common peroneal neuropathy. *J Korean Med Sci.* 2008;23(1):117-121.
47. Derr JJ, Micklesen PJ, Robinson LR. Predicting recovery after fibular nerve injury: which electrodiagnostic features are most useful? *Am J Phys Med Rehabil.* 2009;88(7):547-553.
48. Emamhadi M, Bakhshayesh B, Andalib S. Surgical outcome of foot drop caused by common peroneal nerve injuries; is the glass half full or half empty? *Acta Neurochir.* 2016;158(6):1133-1138.
49. Kim DH, Kline DG. Management and results of peroneal nerve lesions. *Neurosurgery.* 1996;39(2):312-319; discussion 9-20.
50. Maalla R, Youssef M, Ben Lassoued N, Sebai MA, Essadam H. Peroneal nerve entrapment at the fibular head: outcomes of neurolysis. *Orthop Traumatol Surg Res.* 2013;99(6):719-722.
51. Nirenberg MS. A simple test to assist with the diagnosis of common fibular nerve entrapment and predict outcomes of surgical decompression. *Acta Neurochir.* 2020;162(6):1439-1444.
52. Ramanan M, Chandran KN. Common peroneal nerve decompression. *ANZ J Surg.* 2011;81(10):707-712.
53. Solmaz I, Cetinalp EN, Göçmez C, et al. Management outcome of peroneal nerve injury at knee level: experience of a single military institution. *Neurol Neurochir Pol.* 2011;45(5):461-466.
54. Wilson C, Yaacoub AP, Bakare A, Bo N, Aasar A, Barbaro NM. Peroneal nerve decompression: institutional review and meta-analysis to identify prognostic associations with favorable and unfavorable surgical outcomes. *J Neurosurg Spine.* 2019;30(5):714-721.
55. Yasar D. Treatment and follow up outcomes of patients with peroneal nerve injury: a single center experience. *J Clin Anal Med.* 2017;8(1):44-46.
56. Lale A, Kirkil C, Ozturk S, et al. The results of surgical decompression in the treatment of foot drop due to peroneal nerve entrapment after bariatric surgery. *Surg Obes Relat Dis.* 2020;16:1684-1691.
57. Vastamäki M. Decompression for peroneal nerve entrapment. *Acta Orthop Scand.* 1986;57(6):551-554.
58. Fabre T, Piton C, Andre D, Lasseur E, Durandeu A. Peroneal nerve entrapment. *J Bone Joint Surg Am Vol.* 1998;80(1):47-53.
59. Bai SX. Acupuncture for 24 cases of peroneal nerve palsy. *World J Acupuncture Moxibustion.* 2012;22(3):55-56.
60. Singhal A, Varma M, Goyal N, Vij V, Wadhawan M, Gupta S. Peroneal neuropathy following liver transplantation: possible predisposing factors and outcome. *Exp Clin Transplant.* 2009;7(4):252-255.
61. Sipahioğlu S, Zehir S, Aşkar H, Işıkan UE. Peroneal nerve palsy secondary to prolonged squatting in seasonal farmworkers. *Acta Orthop Traumatol Turc.* 2015;49(1):45-50.
62. Yu JK, Yang JS, Kang SH, Cho YJ. Clinical characteristics of peroneal nerve palsy by posture. *J Korean Neurosurg Soc.* 2013;53(5):269-273.
63. Berry H, Richardson PM. Common peroneal nerve palsy: a clinical and electrophysiological review. *J Neurol Neurosurg Psychiatry.* 1976;39(12):1162-1171.
64. Sangwan SS, Marya KM, Kundu ZS, Yadav V, Devgan A, Siwach RC. Compressive peroneal neuropathy during harvesting season in Indian Farmers. *Trop Doct.* 2004;34(4):244-246.
65. George SC, Boyce DE. An evidence-based structured review to assess the results of common peroneal nerve repair. *Plast Reconstr Surg.* 2014;134(2):302e-311e.
66. Aprile I, Tonali P, Caliandro P, et al. Italian multicentre study of peroneal mononeuropathy: multiperspective follow-up. *Neurol Sci.* 2009;30(1):37-44.
67. Tarabay B, Abdallah Y, Kobaiter-Maarrawi S, Yammine P, Maarrawi J. Outcome and prognosis of microsurgical decompression in idiopathic severe common fibular nerve entrapment: prospective clinical study. *World Neurosurg.* 2019;126:e281-e287.
68. Fares MY, Dimassi Z, Fares J, Musharrafieh U. Peroneal neuropathy and bariatric surgery: untying the knot. *Int J Neurosci.* 2020;130(4):417-423.
69. Ali ZS, Pisapia JM, Ma TS, Zager EL, Heuer GG, Khoury V. Ultrasonographic evaluation of peripheral nerves. *World Neurosurg.* 2016;85:333-339.
70. Becciolini M, Pivec C, Riegler G. Ultrasound imaging of the deep peroneal nerve. *J Ultrasound Med.* 2021;40:821-838.
71. Pugdahl K, Tankisi H, Fuglsang-Frederiksen A. Electrodiagnostic testing of entrapment neuropathies: a review of existing guidelines. *J Clin Neurophysiol.* 2020;37(4):299-305.
72. Mont MA, Dellon AL, Chen F, Hungerford MW, Krackow KA, Hungerford DS. The operative treatment of peroneal nerve palsy. *J Bone Joint Surg Am Vol.* 1996;78(6):863-869.
73. Souter J, Swong K, McCoyd M, Balasubramanian N, Nielsen M, Prabhu VC. Surgical results of common peroneal nerve neuroplasty at lateral fibular neck. *World Neurosurg.* 2018;112:e465-e472.
74. Humphreys DB, Novak CB, Mackinnon SE. Patient outcome after common peroneal nerve decompression. *J Neurosurg.* 2007;107(2):314-318.
75. Lu JCY, Dengler J, Poppler LH, et al. Identifying common peroneal neuropathy before foot drop. *Plast Reconstr Surg.* 2020;146(3):664-675.
76. Thoma A, Fawcett S, Ginty M, Veltri K. Decompression of the common peroneal nerve: experience with 20 consecutive cases. *Plast Reconstr Surg.* 2001;107(5):1183-1189.
77. Maalla R, Youssef M, Ben Lassoued N, Sebai MA, Essadam H. Peroneal nerve entrapment at the fibular head: outcomes of neurolysis. *Orthop Traumatol Surg Res.* 2013;99(6):719-722.
78. Sangwan SS, Marya KM, Kundu ZS, Yadav V, Devgan A, Siwach RC. Compressive peroneal neuropathy during harvesting season in Indian farmers. *Trop Doct.* 2004;34(4):244-246.
79. Lo YL, Fook-Chong S, Leoh TH, et al. High-resolution ultrasound as a diagnostic adjunct in common peroneal neuropathy. *Arch Neurol.* 2007;64(12):1798-1800.
80. Tsai PY, Cheng H, Huang WC, et al. Outcomes of common peroneal nerve lesions after surgical repair with acidic fibroblast growth factor. *J Trauma.* 2009;66(5):1379-1384.

How to cite this article: Oosterbos C, Decramer T, Rummens S, et al. Evidence in peroneal nerve entrapment: A scoping review. *Eur J Neurol.* 2022;29:665–679. <https://doi.org/10.1111/ene.15145>

APPENDIX 1

Final search strategies

1. Search strategy for treatment strategies

The following search terms will be used in the three online databases: "peroneal neuropathies (M*) and guidelines", "peroneal neuropathies (M*) and systematic review", "peroneal neuropathies (M*) and randomized controlled trial", "peroneal nerve entrapment and management", "peroneal neuropathies (M*) and therapy (M*)", "peroneal neuropathies (M*) and rehabilitation (M*)", "peroneal nerve entrapment and rehabilitation", "peroneal neuropathies (M*) and surgery (M*)", "peroneal neuropathies (M*) and neurolysis", "peroneal nerve entrapment and neurolysis", "peroneal nerve entrapment and physiotherapy", "peroneal neuropathies (M*) and physiotherapy", "peroneal nerve entrapment and conservative outcome", and "peroneal nerve entrapment and surgical outcome".

Synonym: fibular nerve

M* indicates the use of a Medical Subject Headings (MeSH) term in the PubMed database.

Often peroneal neuropathy is used in the search terms. There is no official terminology classifying peroneal nerve entrapment as idiopathic neuropathy and idiopathic neuropathy with risk factors. Therefore, the more general term peroneal neuropathy was often used.

Filters will not be strictly applied during the database search not to miss any possible eligible article. Filtering will be mostly done based on abstract screening.

2. Search strategy for electrodiagnostic criteria

Following search terms will be used in the three online databases: "peroneal neuropathies (M*) and electrodiagnosis (M*)", "peroneal neuropathies (M*) and electromyography (M*)", "peroneal neuropathies (M*) and nerve conduction studies", "peroneal neuropathies/diagnosis (M*) and guideline (M*)", "electrodiagnosis (M*) and foot drop", "electrophysiology (M*) and peroneal neuropathies (M*)", "electrophysiology (M*) and foot drop", "peroneal nerve (M*) and foot drop and nerve conduction study", "peroneal nerve (M*) and foot drop and electromyography".

Synonym: fibular nerve

M* indicates the use of a MeSH term in the PubMed database.

3. Search strategy for imaging studies

The following search terms will be used in the three online databases: "peroneal neuropathies (M*) and ultrasonography (M*)", "peroneal neuropathies (M*) and ultrasound", "peroneal neuropathies (M*) and magnetic resonance imaging (M*)", "peroneal neuropathies (M*) and MR neurography", "peroneal neuropathies (M*) and ultrasonography (M*) and magnetic resonance imaging (M*)", "peroneal neuropathies (M*) and imaging", "peroneal neuropathies/diagnostic imaging (M*)", "peroneal neuropathies (M*) and ultrasonography (M*) and guidelines (M*)", "peroneal neuropathies (M*) and ultrasonography (M*) and systematic review (M*)", "peroneal neuropathies (M*) and magnetic resonance imaging (M*) and guidelines (M*)", "peroneal neuropathies (M*) and magnetic resonance imaging (M*) and systematic review (M*)", "peroneal neuropathies (M*) and ultrasonography (M*) and magnetic resonance imaging (M*) and randomized controlled trial (M*)".

Synonym: fibular nerve

M* indicates the use of a MeSH term in the PubMed database.