Made available by Hasselt University Library in https://documentserver.uhasselt.be

Relationship Among the Foraminal Area and Demographic and Clinical Characteristics of Patients with Low Back Pain

Peer-reviewed author version

Lorenc , Tomasz & BURZYKOWSKI, Tomasz (2022) Relationship Among the Foraminal Area and Demographic and Clinical Characteristics of Patients with Low Back Pain. In: World Neurosurgery, 160 , p. E520 -E528.

DOI: 10.1016/j.wneu.2022.01.062
Handle: http://hdl.handle.net/1942/37563

Journal Pre-proof

Title: Relationship Between the Foraminal Area and Demographic and Clinical Characteristics of Patients with Low Back Pain

Abstract

Objective: Our study aims to contribute to existing knowledge by evaluating patients with low back pain to provide a more accurate relationship between the diameter of the intervertebral foramen and the clinical, demographic, and lumbar spine anatomical factors such as age, sex, BMI, the Zurich Claudication Questionnaire (ZCQ) , facet joint, intervertebral disc, ligamentum flavum, and spinal canal.

Methods: We studied 90 consecutive patients who had undergone evaluation for low back pain. We used magnetic resonance imaging to assess the cross-sectional areas of the intervertebral foramina at each level of the lumbar spine together with the ligamentum flavum area and the dural sac cross sectional area measurements. The presence of disc and facet joint degeneration was evaluated and data on symptoms was obtained.

Results: Age ($p<0.0001$), lumbar disc degeneration (LDD) grade ($p=0.016$), and dural sac cross sectional area (DSCSA, $p<0.0001$) were found to statistically significantly influence the foraminal area (FA). The mean FA at all lumbar levels increased with increasing DSCSA. The mean FA decreased with age at all levels except of L5/S1. LDD grade 1-3 increased the mean FA at L5/S1, but not at other levels. No statistically significant effects of the side of the measurement, sex, BMI, ZCQ score, ligamentum flavum area, nor facet joint degeneration were found.

Conclusions: The results of the present study allow us to quantify the effect of age, dural sac cross-sectional area, and lumbar disc degeneration grade on the foraminal area.

Journal Pre-proof

Journal Pre-proof

1. Introduction

The area of the intervertebral foramen is particularly sensitive to progressive degeneration of the facet joints, intervertebral disks, and ligamentous structures [1]. Degenerative changes that are common in elderly patients may alter true foraminal dimensions [2]. Although little is known about constitutional factors affecting the foraminal dimensions, it has been reported that congenital anomaly or obesity can influence the foraminal size [3, 4]. The lumbar intervertebral foramen is a space that contains the spinal nerve and dorsal root ganglia, which are composed of sensory neurons. Thus, foraminal dimensions affect physical function, health status, quality of life, and severity of symptoms [5]. Lumbar foraminal stenosis (LFS) is a relatively common cause of lumbar radiculopathy characterized by a narrowing of the canal space for the exiting nerve root with a reported incidence rate of 8% to 26% [6]. Clinical LFS is often unrecognized and accounts for approximately 60% of failed back surgery syndromes with continued postoperative symptoms [7, 8]. The dimensions of the foramen are of clinical importance in the diagnosis of foraminal stenosis and radiculopathy. The radiological diagnosis of LFS is performed using multiple radiological modalities, such as magnetic resonance imaging, including plain examination and novel protocols such as diffusion tensor imaging, as well as dynamic X-ray, and computed tomography. Obliteration of the perineural fat surrounding the nerve root on parasagittal magnetic resonance imaging (MRI) [9, 10] has long been the recommended method for diagnosing intervertebral foramen stenosis. However, recent reports state that these magnetic resonance images do not always provide complete information and sometimes result in false positive or false negative findings [11]. Efforts to investigate whether constitutional factors and degenerative changes affect the area of the intervertebral foramen may be helpful for clinical care.

There are minimal in vivo data that assess the relationship between the foraminal area with demographic and clinical characteristics such as age, sex, BMI, Zurich Claudication Questionnaire (ZCQ) score, facet joint, intervertebral disc, ligamentum flavum, and spinal canal. In the present study, we used high-resolution, three-dimensional magnetic resonance (3D-MR) images to evaluate the foraminal area and to investigate its relationship with demographic and clinical characteristics of patients with low back pain. Our aim is to improve existing knowledge by evaluating a large sample size of patients with low back pain to provide a more accurate

relationship between the intervertebral foramen area and clinical, demographic, and lumbar spine anatomical factors.

2. Materials and Methods

2.1. Patient Selection, Key Inclusion, and Exclusion Criteria

Ninety consecutive patients who had a history of back, buttock, or leg pain were enrolled in a retrospective study. Patients were consecutively examined following the National Health Fund waiting list for diagnostic imaging examinations and following the diagnostic workflow. We conducted this study in compliance with the principles of the Declaration of Helsinki. The study was approved by the Institutional Review Board of the Medical University of Warsaw (IRB No. AKBE/100/13). All patients signed an informed consent form before participation in the study. To participate in the study, the patients had to be at least 18 years of age and have leg, buttock or groin pain with or without back pain. We excluded patients with previous lumbar surgery, acute trauma, malignant spinal neoplasm, or spinal infection.

2.2. MRI settings

All examinations were performed using a 1.5-T digital MR system (Ingenia, Philips, Best, The Netherlands), using phased array digital coils: dStream Posterior (12-channel, self-positioning, embedded in a patient table) and dStream Anterior (16-channel, flexible, placed on the patient's abdomen). Patients participating in the study were routinely evaluated using standard fast spin echo sequences, as well as 3D, high resolution T2-weighted MRI sequences (Volume Isotropic Turbo Spin Echo Acquisition [VISTA], Philips Healthcare, Nederlanden). Spine VISTA is an ultrafast pulse sequence that produces high resolution thin-section images (0.5 mm) with outstanding image contrast between fat and other structures (vessels or nerves) in the intervertebral foramina. For 3D VISTA MRI, sagittal 3D T2- weighted FSE images were acquired with a reconstruction voxel size of 0.5x0.5x0.5 mm.

2.3. MRI measurements

Multiplanar images were reconstructed using workstation software (Intellispace Portal, Philips, Best, The Netherlands). On magnified MRI views, we first determined the best sagittal plane for the anatomical and

Journal Pre-proof

morphometric assessment of each intervertebral foramen (IVF) (Figure 1). The foraminal area (FA) was evaluated on the sagittal 3D-MR images, showing the smallest cross-sectional area of IVF (Figure 1). The foraminal area was defined as the area bounded by the adjacent superior and inferior vertebral pedicles, the posterosuperior boundary of the inferior vertebral body, the surface of the intervertebral disc anteriorly, the posteroinferior boundary of the superior vertebral body and the surface of the ligamentum flavum posteriorly. The ligamentum flavum area (LFA), the dural sac cross sectional area (DSCSA), the degree of the facet joint degeneration according to Weishaupt, and the degree of the lumbar disc degeneration according to the Pfirrmann classification were also evaluated. LFA and DSCSA were evaluated in the transverse plane, perpendicular to the spinal canal by encircling the outlines of the ligamenta flava and dural sac, respectively. The Weishaupt classification was evaluated as joint space width, osteophytes, and hypertrophy of the articular process, subarticular bone erosions, and subchondral cysts on conventional T1-weighted images, graded as follows: grade 0, normal; grade 1, mild degenerative disease; grade 2, moderate degenerative disease; and grade 3, severe degenerative disease [12]. The Pfirrmann classification was evaluated as structure, signal intensity, nucleus and anulus distinction and height of the intervertebral disc on T2-weighted parasagittal images, classified from grade 1 (normal) to grade 5 (severe degeneration) [13].

2.4. Clinical assessment

Symptom severity and physical function were assessed using the Zurich Claudication Questionnaire (ZCQ) [14]. Furthermore, the clinical assessment was performed using body mass index (BMI), Visual Analog Scale (VAS) score for the evaluation of low back pain and leg pain, and the Oswestry Low Back Pain Disability Questionnaire [15].

2.5. Statistical analysis

The distributions of continuous variables were summarized using the sample mean, standard deviation, median, lower, and upper quartiles, and minimum and maximum values. Distributions of categorical variables (factors) were described by percentages of observations falling into separate categories (factor levels). The association between pairs of continuous variables was described using scatterplots and summarized using

Journal Pre-proof

Pearson's correlation coefficients. The association between a continuous variable and a factor was described using boxplots and summarized by listing sample means for different levels of the factor.

For each patient, measurements of the foraminal area (FA) were obtained for each side (left or right) at each vertebra level (L1/L2, L2/L3, L3/L4, L4/L5, L5/S1). Given the correlation between the measurements and the observational nature of the data, the measurements were analyzed using a linear model for the correlated observations [16]. A general unrestricted form of the variance-covariance matrix of the measurements was used. The model included the side (left or right) and the vertebra level (L1/L2, L2/L3, L3/L4, L4/L5, L5/S1), at which the FA measurement was obtained, as factors. It also included the following variables describing a patient: sex (as a factor), age (in years), BMI, and the Zurich Claudication Questionnaire (ZCQ) score. Additionally, the following variables describing the lumbar spine were used: ligamentum flavum area (LFA, mm^2), the dural sac cross sectional area (mm^2), the degree of the facet joint degeneration (FJD, a factor with three levels: 0, 1, 2-3), and the degree of lumbar disc degeneration (LDD, a factor with two levels: 1-3, 4-5).

In an initial model, the effects of the patient and spine-related variables were assumed to be side- and level-specific by including the interactions of the variables with side- and level factors. Subsequently, the initial model was simplified by removing non-significant interactions (at the two-sided 5% significance level) and main effects. The fit of the initial and final models was checked by using marginal normalized residuals [16].

All statistical significance tests were conducted at the two-sided 5% significance level. Given the exploratory nature of the analysis, no correction for multiple testing was applied.

The analysis was conducted by using SAS v. 9.4, STATA v.16 and R v.3.6.2 software.

3. Results

The analyzed dataset included 90 subjects, of which 46 (51.1%) were women. Table 1 presents descriptive statistics for age, BMI, and ZCQ score. There were 33 (36.7%) individuals with BMI<25, 38 (42.2%) individuals with BMI between 25 and 30, and 19 (21.1%) individuals with BMI>30.

For the 90 subjects enrolled in this study, a total of 900 intervertebral foramen were analyzed for L1/L2, L2/L3, L3/L4, L4/L5, and L5/S1 bilaterally. Table 2 presents descriptive statistics for FA and LFA per spine level and side, and for DSCSA per spine level. An increasing trend in the mean values of FA and LFA for decreasing levels can be observed.

In terms of facet joint degeneration (FJD), 300 (33.3%) of the measurements had grade 0, 405 (45%) had grade 1, and 195 (21.7%) had grade 2-3, according to the criteria of Weishaupt et al. Table 3 presents the distribution of the FJD grade per spine level and side. The percentage of degree 0 decreases with decreasing spine level, with a simultaneous increase of percentages of degree 1 and degree 2-3 categories.

In terms of disc degeneration, 144 (16%) of 900 measurements had grade 1-3 and 756 (84%) had grade 4-5 according to the criteria of Pfirrmann et al. Table 4 presents the distribution of the degree of lumbar disc degeneration (LDD) per spine level. A trend towards a decreasing percentage of degree 1-3 cases with decreasing spine level can be noted. This means that the lower the disc level, the more severe the disc degeneration.

Figure 2 presents a scatterplot matrix of FA measurements. A substantial correlation (more than 0.5) between the measurements obtained at two sides of the same level can be observed. The correlation decreases for measurements obtained for more distant levels.

Table 5 shows the pairwise correlation coefficients corresponding to the scatterplots. Note that the coefficients are presented as a means of summarizing the data without any inferential goal. Therefore, no standard deviations nor any p-values are reported. On average, there is a consistent positive correlation of FA with DSCSA (mean 0.47) and a negative correlation with age (mean -0.36) and the ZCQ score (mean -0.10). For BMI (mean -0.15) and LFA (mean -0.09), there is some fluctuation of the correlation coefficients between small positive and negative values. The results suggest a possible association between FA and age and DSCSA.

Table 6 shows the sample means of FA for each level of those factors. Note that the means are presented here as a tool to summarize the data without any inferential goal. Hence, no standard deviations nor any p-values are reported. Across the lumbar spine levels, a trend towards higher sample means of FA for females can be

Journal Pre-proof

Journal Pre-proof

observed. Also, the sample means of degree 1-3 of the LDD appear to be systematically higher than for degrees 4-5. Similarly, the means decrease with an increasing degree of the facet joint degeneration.

Table 7 presents the coefficients of the final linear model fitted to the data. No statistically significant effects of the side of the measurement, sex, BMI, ZCQ score, LFA, and FJD were found. Thus, those variables are not included in the model presented in Table 7. For age and LDD, the effect is described by vertebra-level-specific coefficients (p-value for the interaction test of the hypothesis that all coefficients are equal: p=0.0005 for age and p=0.038 for LDD). For age, the coefficients are statistically significantly different from 0 for all but the L5/S1 level. For LDD, the coefficients are statistically significantly different from 0 only for the level L5/S1. For DSCSA, the effect is expressed by the same coefficient for all levels (p-value for the interaction test: p=0.11). The coefficient is statistically significantly different from 0.

4. Discussion

This study aimed to use a 3D magnetic resonance imaging method to explore the morphological characteristics of the intervertebral foramen in the lower back in different age groups, both sexes, different degrees of degeneration of the lumbar disc and facet joints, and different states of claudication and BMI.

An important and novel aspect of the presented study, compared to previous investigations reported in the literature, is the simultaneous evaluation of the effect of several demographic (age, sex, BMI, ZCQ score) and clinical (facet joint, intervertebral disc, ligamentum flavum, and spinal canal) characteristics on the foraminal area. In fact, only a few authors have sought to determine factors that affect the area of the intervertebral foramen, and each investigation has focused on a single factor. For instance, a recent MRI study by Paholpak et al. showed a significant difference in the foraminal area measured at the level of lumbar spondylolisthesis in degenerative lumbar spondylolisthesis group compared to the control group [17]. Patients with lumbar spondylolisthesis had significantly smaller foraminal cross-sectional area compared to control patients. Recently, Modi et al. [18] noted that at all lumbar levels, the foraminal area was decreased in patients with achondroplasia compared to the control group. Interestingly, although the size of the foramina narrowed in

achondroplasia at the lumbar level, the occupancy of lumbar nerve root is not more than normal patients, mainly due to narrowing of lumbar nerve root size. Therefore, it is interesting to know that why achondroplasia patients do not develop severe paraparesis, even though they show narrowing of spinal canal at thoracolumbar junction along with kyphosis. Our study has not dealt with achondroplasia and spondylolisthesis. Yan et al. [19] investigated the relationship of the foramen area with age. According to the authors of the latter study, the bony boundary area of L3/L4 and L4/L5 intervertebral foramina decreased significantly from the young age group to the middle age group, while no significant differences were found between the middle age group and the old age group. In addition, the decrease of bony foramen area at L3/L4 and L4/L5 was observed earlier than at L5/S1. Since the boundary of the bony foramen is not continuous due to the disc, this makes it difficult to compare with the MRI models.

Few studies assessed the neuroforaminal area in magnetic resonance imaging (MRI) in a series of patients before and after surgery for degenerative disease of the lumbar spine. Cho et al. [20] sought to compare preoperative foraminal dimensions at each operative level with the corresponding postoperative size to determine the change attributable to anterior interbody fusion (ALIF). The authors reported a significant increase in the foraminal area to 124.7 mm^2 after ALIF performed on 26 patients. Some authors investigated a small sample of asymptomatic volunteers [21], other authors measured foraminal area only at the selected level of the lumbar spine [17, 22]. When it comes to foramen dimension measurement, most of the authors reported only a single dimension (height) of the intervertebral foramen [23], few authors reported two dimensions. The height and width of the foramen were measured and then the foraminal area was deduced using known mathematical formulations for the area of ellipses [24]. Besides, previous radiologic reports regarding spinal foramen are limited to the occurrence of abnormalities in cadaveric specimens [25] or focus mainly on changes at the cervical level [26]. Comparison between studies is difficult given differences in testing conditions.

Although it may be difficult to directly compare our data with measurements obtained in other studies, our findings are similar to some findings reported in the literature. In particular, we found (Table 2) that the mean foraminal area ranged from 93.1 ± 33.0 mm^2 to 119.3 ± 40.8 mm^2. In the study by Simonovich et al. [27], the mean of FA measurements ranged from 102.19 ± 34.56 mm^2 to 119.26 ± 38.76 mm^2. Canbek et al. [24] reported the mean FA ranging from 90.22 ± 31.52 mm^2 to 107.04 ± 43.93 mm^2. In the study by Shin and colleagues [5],

the preoperative FA ranged from 94.5±16.56 mm^2 to 103.26±15.82 mm^2. Cho et al [20] found that the average FA at the stenotic level was equal to 87.03 ± 30.36 mm^2 and the average size at the superadjacent level was equal to 125.84 ± 32.38 mm^2. Phalopak [17] reported that the average FA was 117.97 ± 25.83 mm^2. Our mean FA values are somewhat smaller than those reported by Modi et al. [18] who evaluated a wide range of foraminal areas among different groups and found that the minimum mean FA value was equal to 151.27 ± 8.56 mm^2 and 269.35 ± 18.24 mm^2 in patients with achondroplasia and in the control group, respectively. The discrepancy may be due to differences in the selected group of LFS patients.

An important aspect of our study was a simultaneous, model-based analysis of the effect of the demographic and clinical characteristics on the foraminal area that properly adjusted for potential correlations between the measurements of the area. None of the previous investigations reported in the literature has applied such a model-based approach. The results of our analysis indicate that, out of the eight considered characteristics, age, DSCSA, and LDD had a statistically significant effect on the foraminal area. The importance of age is a finding similar to the one reported for the study by Yan et al. [19] mentioned earlier.

In particular, in our analysis, the foraminal area decreased with increasing age at the level L1/L2, L2/L3, L3/L4, and L4/L5 . This suggests that the nerve root of older patients may be more easily affected compared to younger patients by spinal stenosis at L1/L2, L2/L3, L3/L4 and L4/L5 lumbar level. However, no statistically significant effect of age was obtained at L5/S1 level. This difference may result from a mobile range of different lumbar levels, as the moving range of L1/L2, L2/L3, L3/L4, and L4/L5 is larger than that of L5/S1. It is also possible that it is a false-negative finding.

Our analysis indicates that individuals with a greater DSCSA had a greater foraminal area at all spinal levels. Hence, a decrease of dural sac cross sectional area may imply a decrease of foraminal area and might additionally cause the compression or irritation of nerve root, which might be a pathological source of radiculopathy and could cause low back pain and failed back surgery syndrome. The relationship between FA and DSCSA and clinical symptoms is very meaningful in the pathology of lumbar foramen stenosis and may be beneficial for the diagnosis of lumbar foramen stenosis, which should be explored in a further study.

Journal Pre-proof

For the degree of lumbar disc degeneration, only the effect at level L5/S1 was statistically significant in our analysis. This could be a false positive finding. However, the difference, compared to the other levels, may be due to the fact that the moving range of L1/L2, L2/L3, L3/L4 and L4/L5 is larger than that of L5/S1.

To gain more insight into the interpretation of the model-based results presented in Table 7, note that they can be expressed in the form of an equation that can be used to predict the mean foraminal area at different vertebral levels. For instance, for a 50-year-old patient with degree 2 of intervertebral disc degeneration and the area of spinal canal equal to 200 at L2/L3, the expected value of the area of the intervertebral foramen at L2/L3 is equal to 136.83-2.45-1.02x50+0.16x200 = 115.38 mm^2. For a similar patient, but with degree 4 of intervertebral disc degeneration, the expected area is equal to 136.83-1.02x50+0.16x200 = 117.83 mm^2.

The limitations of our study include its retrospective nature and the fact that all foraminal parameters were measured in the supine position, while patients can suffer in the standing position. Further weight-bearing or axially loaded magnetic resonance analysis could provide more clinically relevant information.

Conclusions

The study provides information about foraminal morphological characteristics in different age groups of both sexes, different grades of lumbar disc and facet joint degeneration, and different states of claudication at lower back with 3D method. This information is valuable to better understand intervertebral foramen diseases, which may be helpful for their pathology and surgery planning.

Journal Pre-proof

References

1. Orita S, Inage K, Eguchi Y, et al. Lumbar foraminal stenosis, the hidden stenosis including at L5/S1. *Eur J Orthop Surg Traumatol.* 2016;26(7): 685-693. https://doi.org/10.1007/s00590-016-1806-7.
2. Liu W, Zhao Y, Jia J, et al. Morphologic Changes of Intervertebral Foramen After Minimally Invasive Transforaminal Lumbar Interbody Fusion: A Radiographic and Clinical Study. *World Neurosurg.* 2020;142: e151-e159. https://doi.org/10.1016/j.wneu.2020.06.143.
3. Verbiest H. A radicular syndrome from developmental narrowing of the lumbar vertebral canal. *J Bone Joint Surg Br.* 1954;36-B(2): 230-237.
4. Lorenc T, Palczewski P, Wojcik D, Glinkowski W, Golebiowski M. Diagnostic Benefits of Axial-Loaded Magnetic Resonance Imaging Over Recumbent Magnetic Resonance Imaging in Obese Lower Back Patients. *Spine.* 2018;43(16): 1146-1153. https://doi.org/10.1097/BRS.0000000000002532.

5. Shin SH, Choi WG, Hwang BW, et al. Microscopic anterior foraminal decompression combined with anterior lumbar interbody fusion. *The spine journal : official journal of the North American Spine Society.* 2013;13(10): 1190-1199. https://doi.org/10.1016/j.spinee.2013.07.458.
6. Jenis LG, An HS. Spine update. Lumbar foraminal stenosis. *Spine.* 2000;25(3): 389-394. https://doi.org/10.1097/00007632-200002010-00022.
7. Burton CV, Kirkaldy-Willis WH, Yong-Hing K, Heithoff KB. Causes of failure of surgery on the lumbar spine. *Clin Orthop Relat Res.* 1981(157): 191-199.
8. Kunogi J, Hasue M. Diagnosis and operative treatment of intraforaminal and extraforaminal nerve root compression. *Spine.* 1991;16(11): 1312-1320. https://doi.org/10.1097/00007632-199111000-00012.
9. Lee S, Lee JW, Yeom JS, et al. A practical MRI grading system for lumbar foraminal stenosis. *AJR Am J Roentgenol.* 2010;194(4): 1095-1098. https://doi.org/10.2214/AJR.09.2772.
10.Wildermuth S, Zanetti M, Duewell S, et al. Lumbar spine: quantitative and qualitative assessment of positional (upright flexion and extension) MR imaging and myelography. *Radiology.* 1998;207(2): 391-398. https://doi.org/10.1148/radiology.207.2.9577486.
11.Aota Y, Niwa T, Yoshikawa K, Fujiwara A, Asada T, Saito T. Magnetic resonance imaging and magnetic resonance myelography in the presurgical diagnosis of lumbar foraminal stenosis. *Spine.* 2007;32(8): 896-903. https://doi.org/10.1097/01.brs.0000259809.75760.d5.
12.Weishaupt D, Zanetti M, Boos N, Hodler J. MR imaging and CT in osteoarthritis of the lumbar facet joints. *Skeletal Radiol.* 1999;28(4): 215-219.
13.Pfirrmann CW, Metzdorf A, Zanetti M, Hodler J, Boos N. Magnetic resonance classification of lumbar intervertebral disc degeneration. *Spine.* 2001;26(17): 1873-1878. https://doi.org/10.1097/00007632-200109010-00011.
14.Stucki G, Daltroy L, Liang MH, Lipson SJ, Fossel AH, Katz JN. Measurement properties of a self-administered outcome measure in lumbar spinal stenosis. *Spine.* 1996;21(7): 796-803. https://doi.org/10.1097/00007632-199604010-00004.
15.Fairbank JC, Pynsent PB. The Oswestry Disability Index. *Spine.* 2000;25(22): 2940-2952; discussion 2952. https://doi.org/10.1097/00007632-200011150-00017.
16.Gałecki AT, Burzykowski T. *Linear mixed-effects models using R : a step-by-step approach*. New York, NY: Springer; 2013.
17.Paholpak P, Nazareth A, Khan YA, et al. Evaluation of foraminal cross-sectional area in lumbar spondylolisthesis using kinematic MRI. *Eur J Orthop Surg Traumatol.* 2019;29(1): 17-23. https://doi.org/10.1007/s00590-018-2276-x.
18.Modi HN, Suh SW, Song HR, Yang JH. Lumbar nerve root occupancy in the foramen in achondroplasia: a morphometric analysis. *Clin Orthop Relat Res.* 2008;466(4): 907-913. https://doi.org/10.1007/s11999-008-0142-6.
19.Yan S, Zhang Y, Wang K, et al. Three-Dimensional Morphological Characteristics of Lower Lumbar Intervertebral Foramen with Age. *BioMed Research International.* 2018;2018: 1-8. https://doi.org/10.1155/2018/8157061.
20.Cho W, Sokolowski MJ, Mehbod AA, et al. MRI measurement of neuroforaminal dimension at the index and supradjacent levels after anterior lumbar interbody fusion: a prospective study. *Clin Orthop Surg.* 2013;5(1): 49-54. https://doi.org/10.4055/cios.2013.5.1.49.
21.Khalaf AM, Yedavalli V, Massoud TF. Magnetic resonance imaging anatomy and morphometry of lumbar intervertebral foramina to guide safe transforaminal subarachnoid punctures. *Clin Anat.* 2020;33(3): 405-413. https://doi.org/10.1002/ca.23533.

Journal Pre-proof

22.Qu H, Yu LJ, Wu JT, et al. Spine system changes in soldiers after load carriage training in a plateau environment: a prediction model research. *Mil Med Res.* 2020;7(1): 63. https://doi.org/10.1186/s40779-020-00293-1.
23.Phan K, Mobbs RJ, Rao PJ. Foraminal height measurement techniques. *J Spine Surg.* 2015;1(1): 35-43. https://doi.org/10.3978/j.issn.2414-469X.2015.07.01.
24.Canbek U, Rosberg DBH, Rosberg HE, Canbek TD, Akgun U, Comert A. The effect of age, BMI, and bone mineral density on the various lumbar vertebral measurements in females. *Surg Radiol Anat.* 2021;43(1): 101-108. https://doi.org/10.1007/s00276-020-02560-1.
25.Cinotti G, De Santis P, Nofroni I, Postacchini F. Stenosis of lumbar intervertebral foramen: anatomic study on predisposing factors. *Spine.* 2002;27(3): 223-229. https://doi.org/10.1097/00007632-200202010-00002.
26.Knapik DM, Abola MV, Gordon ZL, Seiler JG, Marcus RE, Liu RW. Differences in Cross-Sectional Intervertebral Foraminal Area From C3 to C7. *Global spine journal.* 2018;8(6): 600-606. https://doi.org/10.1177/2192568218758085.
27.Simonovich A, Nagar Osherov A, Linov L, Kalichman L. The influence of knee bolster on lumbar spinal stenosis parameters on MR images. *Skeletal Radiol.* 2020;49(2): 299-305. https://doi.org/10.1007/s00256-019-03287-w.

Figure Legends:

Figure 1. MRI images show type of measurements. (A) Cross-sectional area of ligamentum flavum, between medial border of ligamentum flavum and medial border of vertebral arch. (B) Dural sac cross-sectional area. (C) Cross-sectional area of neural foramina. Foraminal area was defined as the area bounded by the adjacent superior and inferior vertebral pedicles, the posterosuperior portion of the inferior vertebral body, the surface of the intervertebral disk anteriorly, the posteroinferior portion of the superior vertebral body, and the surface of the ligamentum flavum posteriorly.

Figure 2. Scatterplot matrix of the repeated measurements of the foraminal area with pairwise scatterplots (below the diagonal) pairwise correlations (above the diagonal), and histograms (on the diagonal). The vertebra level and the side of the measurement presented in a particular row or column are indicated on the diagonal.

Journal Pre-proof

Journal Pre-proof

Table 1. Descriptive statistics (mean, standard deviation, median, minimum, maximum) for age, BMI, and the Zurich Claudication Questionnaire (ZCQ) score.

Variable	mean	Sd	median	min	Max
Age	49.7	15.8	51.5	21.0	89.0
BMI	26.5	4.2	26.0	18.6	42.5
ZCQ	49.4	13.4	50.0	11.7	80.0

Journal Pre-proof

Journal Pre-proof

Table 2. Descriptive statistics (mean, standard deviation, median, minimum, maximum) for the foraminal area (FA), the ligamentum flavum area (LFA), and for the dural sac cross-sectional area (DSCSA).

Foraminal area	mean	sd	median	min	max
L1/L2,L	117.1	33.3	119.5	11.0	218.0
L1/L2,R	118.4	30.5	114.5	46.0	220.0
L2/L3,L	119.3	40.8	117.5	35.0	256.0
L2/L3,R	117.4	39.9	111.0	56.0	249.0
L3/L4,L	110.8	35.2	109.0	43.0	210.0
L3/L4,R	107.2	36.2	107.5	47.0	228.0
L4/L5,L	93.1	31.5	87.0	28.0	155.0
L4/L5,R	96.0	33.0	92.5	16.0	204.0
L5/S1,L	98.4	34.2	100.0	22.0	196.0
L5/S1,R	99.9	31.9	98.0	25.0	166.0
Ligamentum flavum area	mean	sd	median	min	max
L1/L2,L	49.2	12.5	48.0	24.0	78.0
L1/L2,R	47.7	14.0	48.0	2.0	83.0
L2/L3,L	57.2	15.3	57.0	23.0	108.0
L2/L3,R	56.6	17.4	55.0	6.0	116.0
L3/L4,L	59.7	16.9	56.5	30.0	115.0
L3/L4,R	59.7	17.0	57.0	30.0	105.0
L4/L5,L	73.5	22.2	71.0	27.0	155.0
L4/L5,R	76.2	23.0	75.0	25.0	154.0
L5/S1,L	68.1	23.6	67.5	23.0	156.0
L5/S1,R	68.9	25.3	66.0	22.0	167.0

Journal Pre-proof

Journal Pre-proof

Dural sac cross-sectional area	mean	sd	median	min	max
L1/L2	237.8	49.1	231.5	126.0	364.0
L2/L3	198.1	52.9	198.0	36.0	348.0
L3/L4	165.6	51.8	167.5	41.0	283.0
L4/L5	153.7	66.1	150.0	12.0	313.0
L5/S1	175.6	67.7	161.0	60.0	383.0

Journal Pre-proof

Journal Pre-proof

Table 3. Distribution of the degree of the facet joint degeneration per vertebra level and side. First row: N; second row: %.

Level, side	Grade 0	Grade 1	Grade 2-3	Total
L1/L2,L	52	33	5	90
	57.78	36.67	5.56	100.00
L1/L2,R	52	32	6	90
	57.78	35.56	6.67	100.00
L2/L3,L	42	38	10	90
	46.67	42.22	11.11	100.00
L2/L3,R	42	38	10	90
	46.67	42.22	11.11	100.00
L3/L4,L	30	44	16	90
	33.33	48.89	17.78	100.00
L3/L4,R	30	42	18	90
	33.33	46.67	20.00	100.00
L4/L5,L	14	44	32	90
	15.56	48.89	35.56	100.00
L4/L5,R	14	43	33	90
	15.56	47.78	36.67	100.00
L5/S1,L	12	45	33	90
	13.33	50.00	36.67	100.00
L5/S1,R	12	46	32	90
	13.33	51.11	35.56	100.00

Journal Pre-proof

Journal Pre-proof

Table 4. Distribution of the degree of the lumbar disc degeneration per spine level. First row: N; second row: %.

Level	Grade 1-3	Grade 4-5	Total
L1/L2	16	74	90
	17.78	82.22	100.00
L2/L3	19	71	90
	21.11	78.89	100.00
L3/L4	16	74	90
	17.78	82.22	100.00
L4/L5	13	77	90
	14.44	85.56	100.00
L5/S1	8	82	90
	8.89	91.11	100.00

Journal Pre-proof

Journal Pre-proof

Table 5. Correlation coefficients between the foraminal area and age, BMI, the Zurich Claudication Questionnaire (ZCQ) result, the ligamentum flavum area (LFA) and the dural sac cross-sectional area (DSCSA) per lumbar spine level and side.

Spine level, side	Age	BMI	ZCQ	LFA	DSCSA
L1/L2, L	-0.35	-0.10	-0.03	-0.01	0.50
L1/L2, R	-0.34	-0.16	-0.14	-0.22	0.45
L2/L3, L	-0.49	-0.22	-0.25	0.11	0.59
L2/L3, R	-0.36	-0.20	-0.07	-0.15	0.58
L3/L4, L	-0.44	-0.22	-0.12	-0.09	0.61
L3/L4, R	-0.35	-0.19	-0.10	-0.05	0.53
L4/L5, L	-0.38	-0.24	-0.10	-0.16	0.52
L4/L5, R	-0.43	-0.12	-0.07	-0.28	0.44
L5/S1, L	-0.09	0.02	-0.10	0.01	0.21
L5/S1, R	-0.06	-0.04	-0.04	-0.11	0.24
Mean value	-0.33	-0.15	-0.10	-0.09	0.47

Journal Pre-proof

Journal Pre-proof

Table 6. Mean values of the foraminal area for each sex, the degree of the facet joint degeneration (FJD), and the degree of the lumbar disc degeneration (LDD) per spine level and side.

Level, side	Sex		Facet Joint degeneration (grade)			Lumbar disc degeneration (grade)	
	M	F	0	1	2-3	1-3	4-5
L1/L2,L	112.5	121.9	125.8	109.0	79.6	135.4	113.1
L1/L2,R	113.2	123.9	123.4	114.9	93.7	125.1	117.0
L2/L3,L	116.2	122.6	132.3	113.4	87.5	139.2	114.0
L2/L3,R	111.2	123.9	129.0	111.9	89.5	132.4	113.4
L3/L4,L	107.7	114.1	126.6	108.8	87.1	125.4	107.7
L3/L4,R	103.0	111.6	116.7	111.4	81.4	130.1	102.2
L4/L5,L	93.2	93.1	110.1	101.4	74.3	108.6	90.5
L4/L5,R	91.8	100.5	114.3	104.7	76.9	114.1	93.0
L5/S1,L	99.4	97.3	120.8	95.4	94.4	125.8	95.7
L5/S1,R	100.0	99.7	123.2	96.3	96.3	133.3	96.6

Journal Pre-proof

Journal Pre-proof

Table 7. Estimated coefficients per spine level and the corresponding p-values (in parentheses) for the final model for the area of the intervertebral foramen. Last column: p value for the overall test of the hypothesis that all coefficients in the particular row are equal to 0.

	L1/L2	L2/L3	L3/L4	L4/L5	L5/S1	Overall test
Intercept	109.87 (p<0.0001)	136.83 (p<0.0001)	114.38 (p<0.0001)	96.43 (p<0.0001)	58.77 (p<0.0001)	p<0.0001
Degree 1-3 of lumbar disc degeneration (LDD)	6.28 (p=0.29)	-2.45 (p=0.73)	7.74 (p=0.23)	2.16 (p=0.74)	34.46 (p=0.0014)	P=0.016
Age	-0.64 (p=0.0006)	-1.02 (p<0.0001)	-0.66 (p=0.0012)	-0.54 (p=0.0032)	0.17 (p=0.40)	p<0.0001
Dural sac cross-sectional area (DSCSA)	0.16 (p<0.0001)	0.16 (p<0.0001)	0.16 (p<0.0001)	0.16 (p<0.0001)	0.16 (p<0.0001)	p<0.0001

Journal Pre-proof

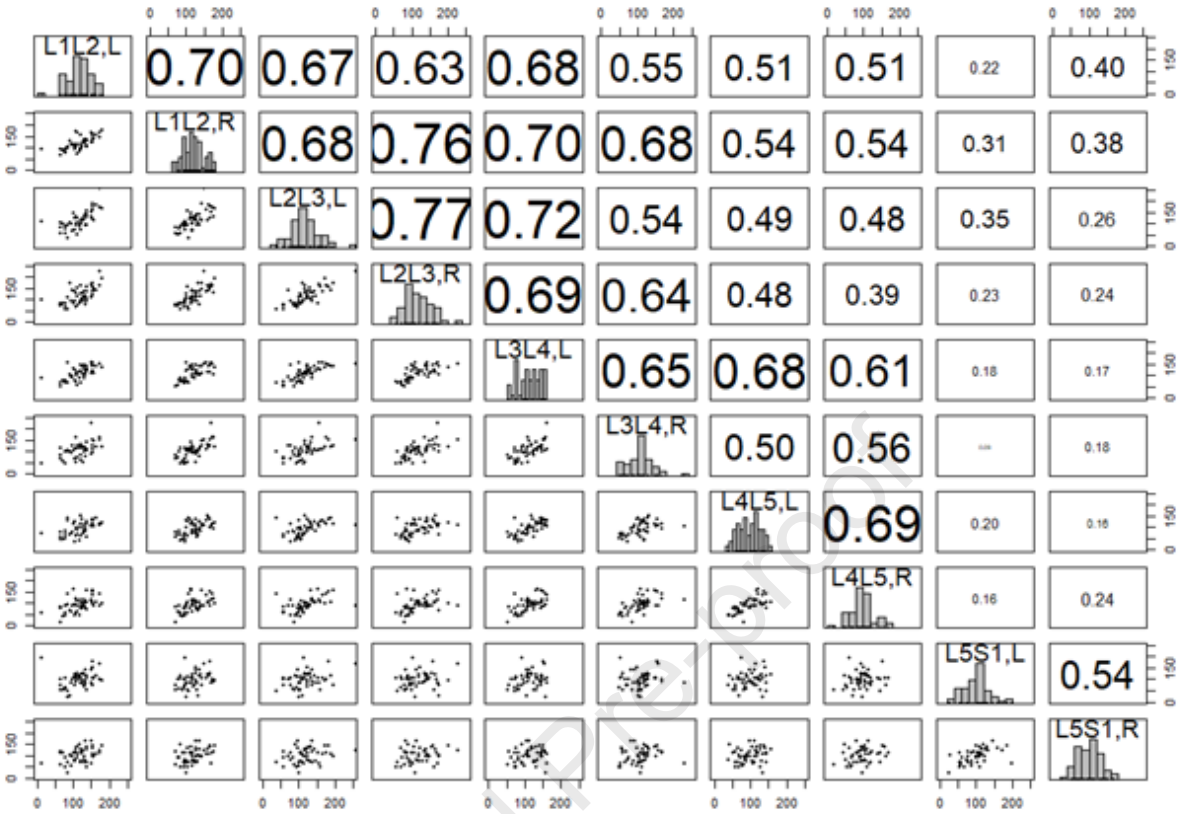

Journal Pre-proof

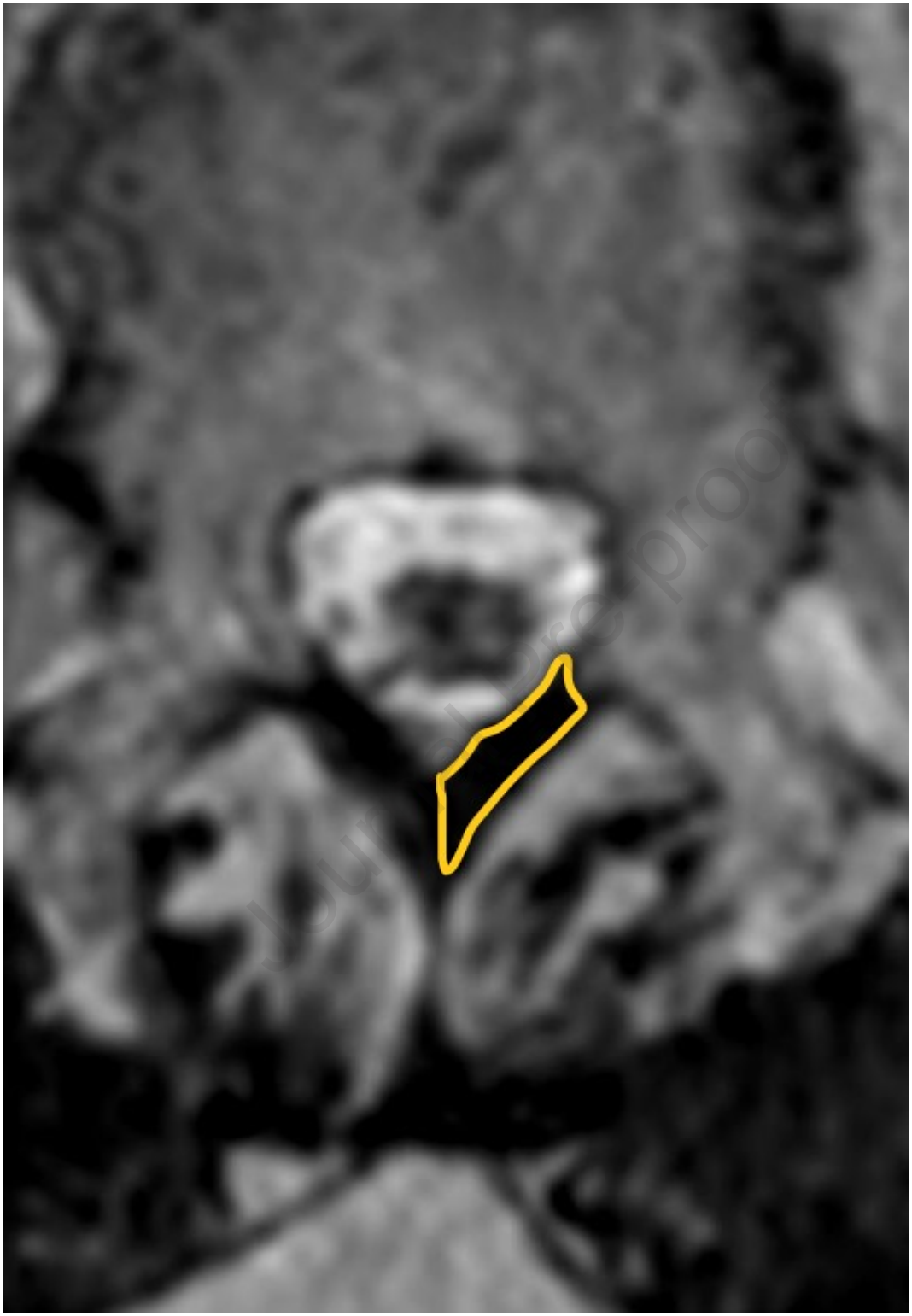

Journal Pre-proof

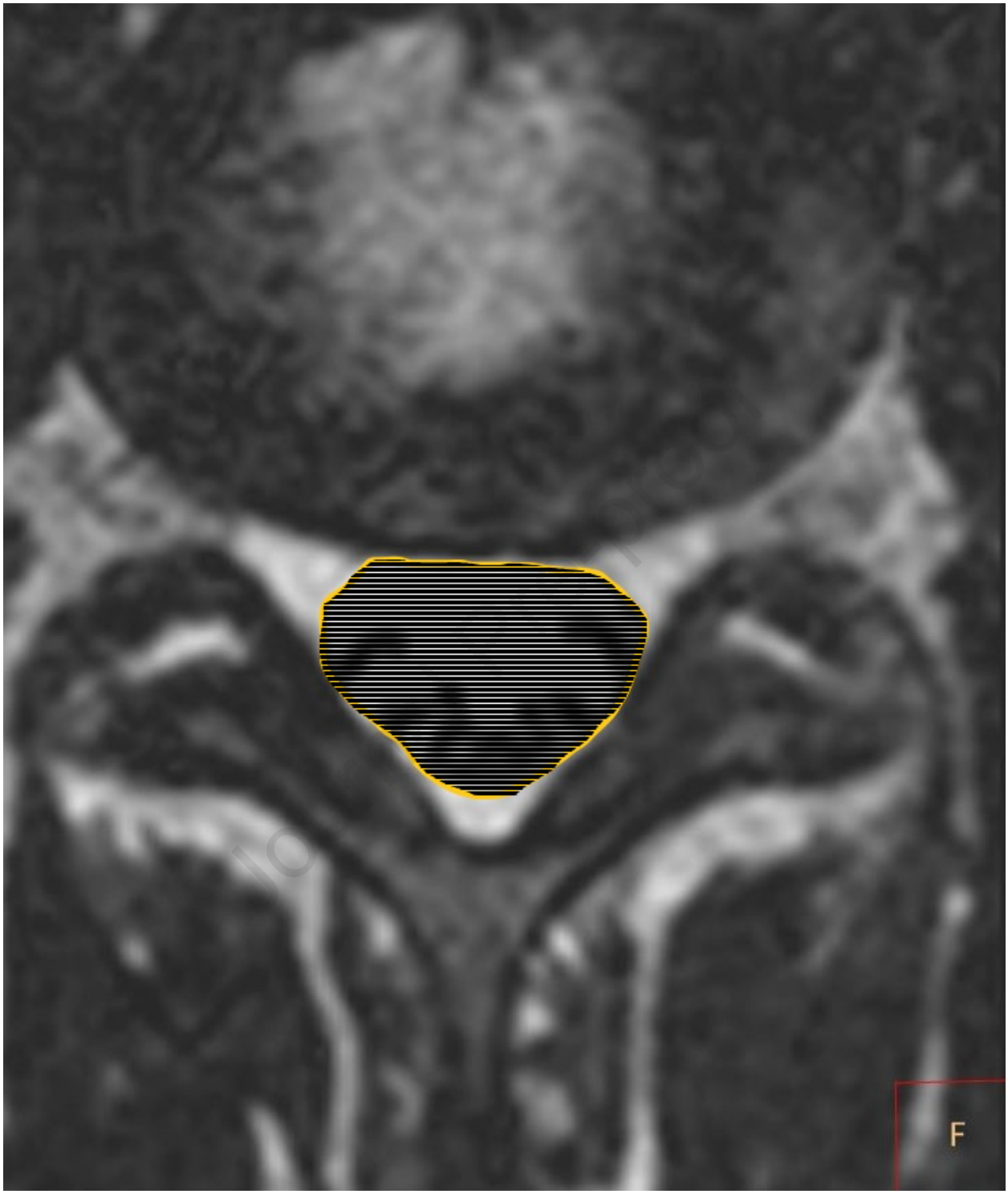
F

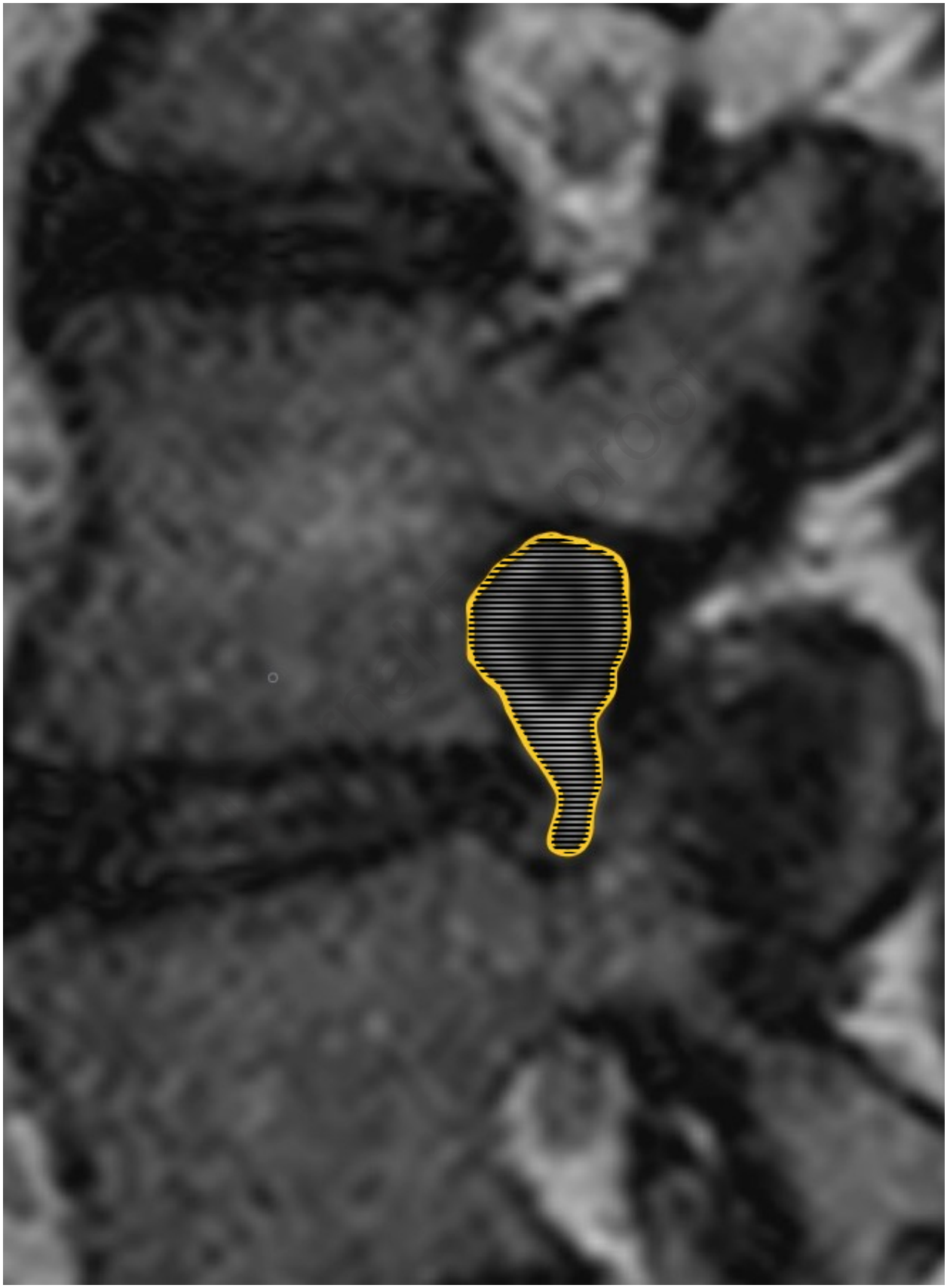

Journal Pre-proof

AUTHORSHIP STATEMENT

Manuscript title: **Relationship Between the Foraminal Area and Demographic and Clinical Characteristics of Patients with Low Back Pain**

All persons who meet authorship criteria are listed as authors, and all authors certify that they have participated sufficiently in the work to take public responsibility for the content, including participation in the concept, design, analysis, writing, or revision of the manuscript.

Author Contributions: Conceptualization, T.L. and T.B.; methodology, T.L. and T.B.; software, T.L. and T.B.; validation, T.L. and T.B.; formal analysis, T.L. and T.B.; investigation, T.L. and T.B.; resources, T.L.; data curation, T.L. and T.B.; writing—original draft preparation, T.L. and T.B.; writing—review and editing, T.L. and T.B.; visualization, T.L. and T.B.; supervision, T.L. and T.B.; project administration, T.L.

Journal Pre-proof

Journal Pre-proof

ABBREVIATIONS

BMI - Body Mas Index

DSCSA - Dural Sac Cross Sectional Area

FA - Foraminal Area

LFA - Ligamentum Flavum Area

FJD - Facet Joint Degeneration

IVF - Intervertebral Foramen

LDD - Lumbar Disc Degeneration

LFS - Lumbar Foraminal Stenosis

MRI - Magnetic Resonance Imaging

VAS - Visual Analog Scale

VISTA -Volume Isotropic Turbo Spin Echo Acquisition

ZCQ - Zurich Claudication Questionnaire

.

Journal Pre-proof