

JACC REVIEW TOPIC OF THE WEEK

Mitral Valve Dysfunction in Patients With Annular Calcification



JACC Review Topic of the Week

Timothy W. Churchill, MD,^a Evin Yucel, MD,^a Sébastien Deferm, MD, PhD,^{b,c} Robert A. Levine, MD,^a Judy Hung, MD,^a Philippe B. Bertrand, MD, PhD^{a,b,c}

ABSTRACT

Mitral annular calcification (MAC) is a common clinical finding and is associated with adverse clinical outcomes, but the clinical impact of MAC-related mitral valve (MV) dysfunction remains underappreciated. Patients with MAC frequently have stenotic, regurgitant, or mixed valvular disease, and this valvular dysfunction is increasingly recognized to be independently associated with worse prognosis. MAC-related MV dysfunction is a distinct pathophysiologic entity, and importantly much of the diagnostic and therapeutic paradigm from published rheumatic MV disease research cannot be applied in this context, leaving important gaps in our knowledge. This review summarizes the current epidemiology, pathophysiology, diagnosis, and classification of MAC-related MV dysfunction and proposes both an integrative definition and an overarching approach to this important and increasingly recognized clinical condition.

(J Am Coll Cardiol 2022;80:739-751) © 2022 by the American College of Cardiology Foundation.

Mitral annular calcification (MAC), a common incidental finding in asymptomatic patients, is common in the aging population and is linked to poor cardiovascular outcomes.¹⁻⁴ Significant valvular dysfunction directly related to MAC occurs in a minority of patients, yet the importance of MAC-related mitral valve (MV) dysfunction is increasingly recognized, as this now represents the dominant etiology of MV stenosis in Western populations and is itself associated with worse prognosis.⁵ However, data regarding MAC-related MV dysfunction are limited, and significant challenges exist in the diagnostic and therapeutic approach to these patients, ranging from limitations of conventional echocardiographic assessment to ongoing controversy regarding clinical benefit of surgical or percutaneous treatment options in this high-risk population.

In this review we aim to: 1) summarize the prevalence and pathophysiology of MAC-related MV dysfunction; 2) highlight strengths and limitations of contemporary diagnostic imaging tools in this patient population; and 3) provide an overview of the prognostic implications of MAC-related MV disease.

EPIDEMIOLOGY

MAC was first described pathologically more than a century ago, and reports since have progressively expanded the anatomical, functional, and prognostic understanding of this condition. Although initial diagnosis was by pathology, radiography, and ultimately fluoroscopy, starting in the 1970s echocardiographic features of MAC were recognized, allowing more widespread and easier detection and diagnosis. At present MAC is commonly diagnosed by either



Listen to this manuscript's audio summary by Editor-in-Chief Dr Valentin Fuster on www.jacc.org/journal/jacc.

From the ^aMassachusetts General Hospital, Harvard Medical School, Boston, Massachusetts, USA; ^bDepartment of Cardiology, Ziekenhuis Oost-Limburg, Genk, Belgium; and the ^cFaculty of Medicine and Life Sciences, Hasselt University, Hasselt, Belgium. The authors attest they are in compliance with human studies committees and animal welfare regulations of the authors' institutions and Food and Drug Administration guidelines, including patient consent where appropriate. For more information, visit the [Author Center](#).

Manuscript received February 24, 2022; revised manuscript received May 30, 2022, accepted May 31, 2022.

**ABBREVIATIONS
 AND ACRONYMS**

- CT** = computed tomography
- HFpEF** = heart failure with preserved ejection fraction
- LV** = left ventricular
- LVOT** = left ventricular outflow tract
- MAC** = mitral annular calcification
- MR** = mitral regurgitation
- MS** = mitral stenosis
- MV** = mitral valve
- MVA** = mitral valve area
- TEE** = transesophageal echocardiography
- TMG** = transmitral gradient

echocardiography or computed tomography (CT), and prevalence estimates typically range from 8% to 15% in the general population, up >40% or higher in studies of elderly individuals,⁴ with considerable variation according to the specific population studied and the diagnostic modality used. MAC is more common in women, patients of advanced age, and those with chronic kidney disease and is associated with multiple cardiovascular risk factors,^{3,4,6,7} likely because of shared pathophysiologic mechanisms with atherosclerosis. In addition, MAC is known to be associated with calcific aortic valve disease and with conditions that increase stress on the MV annulus, such as hypertension, left ventricular (LV) hypertrophy, and MV prolapse.^{2,8}

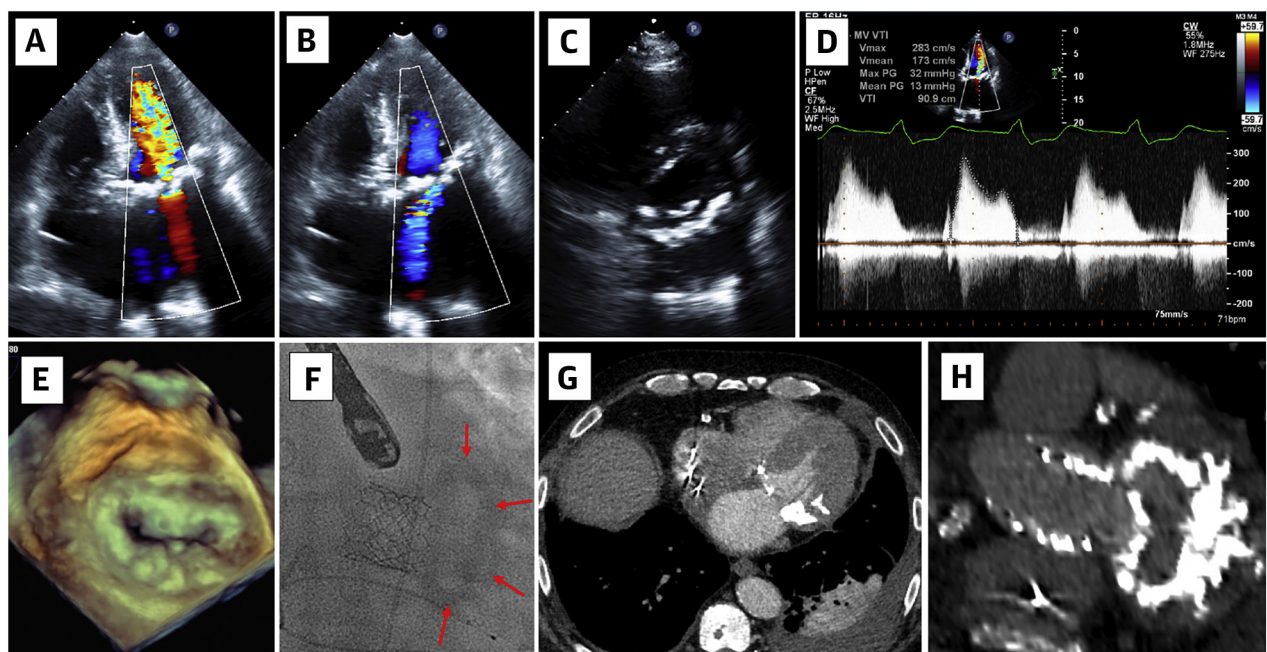
The prevalence of MAC-related MV dysfunction, however, is less well described, at least in part because of the absence of a clear and well-established definition of what constitutes “MAC-related MV dysfunction.” In its simplest formulation, a pathologic elevation in the mean transmitral gradient (TMG) directly related to the presence of MAC can be

HIGHLIGHTS

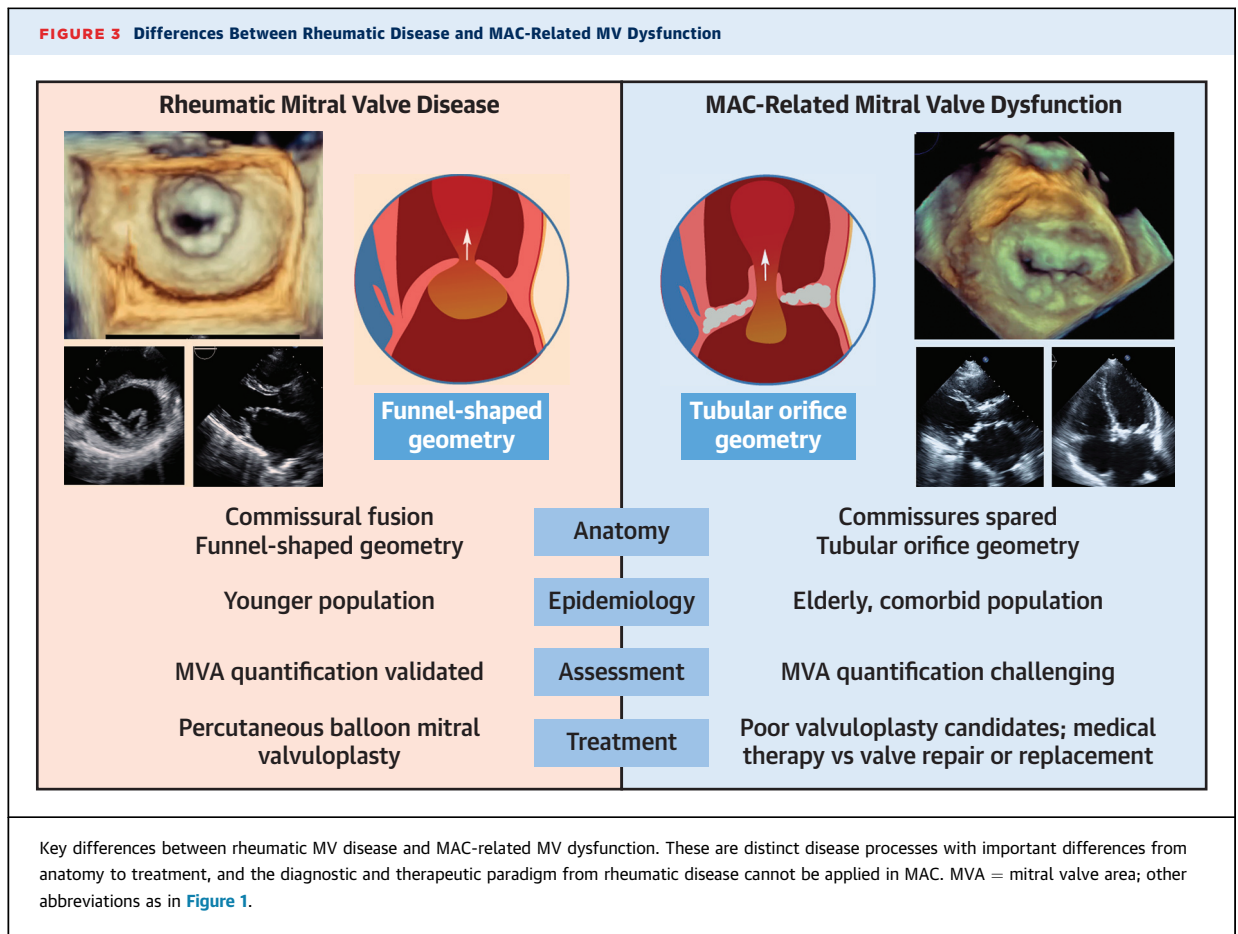
- MAC is increasingly prevalent in the elderly and associated with adverse outcomes.
- Percutaneous transcatheter mitral valve replacement (valve-in-MAC) is a promising intervention, but outcome benefit has not been established.
- Prospective studies are needed to establish criteria for assessment of MAC severity and clinical risk stratification, clarify indications for intervention, and compare management strategies.

regarded as a marker of valve dysfunction. This can be associated with mitral stenosis (MS), mitral regurgitation (MR), or both (mixed valve disease). In our assessment in patients with MAC, a cutoff value of 3 mm Hg was established, above which the TMG was pathologically elevated on the basis of non-laminar, turbulent flow on color Doppler imaging.⁵ In a large cohort of patients with MAC, such pathologic

FIGURE 1 Clinical Example of a Patient With MAC-Related Mitral Valve Dysfunction



Representative echocardiographic (A to E), fluoroscopic (F), and computed tomographic (G and H) images of a 75-year-old man with mitral annular calcification (MAC)-related mitral valve (MV) dysfunction. Key findings included bulky, circumferential MAC and mixed MV dysfunction with severe stenosis and moderate regurgitation.

FIGURE 3 Differences Between Rheumatic Disease and MAC-Related MV Dysfunction

leaflets, resulting in restricted leaflet motion and impaired coaptation. Second, extension of posterior MAC underneath the posterior leaflet may push the posterior leaflet toward the atrium, distorting valvular geometry and reducing the available surface for coaptation.² Third, extra-annular chordal calcification, especially toward the commissures, may cause leaflet restriction and further impair coaptation. Finally, the presence of calcium in the annulus can disrupt mitral annular dynamics. Under normal circumstances (ie, in the absence of significant annular calcium), the mitral annulus passively flexes along the commissural axis in conjunction with LV systolic contraction, deepening the saddle shape and resulting in a greater coaptation surface without leaflet distortion.^{2,16} Normal annular motion also results in changes in annular area, which peaks during diastole and reaches a minimum shortly after left atrial contraction, and annular shape, which changes from elliptical to become more circular, both of which are believed to facilitate ventricular filling and minimize regurgitation.² Annular calcium, however, as

well as calcium that extends into the basal LV myocardium, can impair these intricate processes, likely contributing to impaired coaptation.^{8,16,17}

MECHANISMS OF STENOSIS IN MAC. Annular calcium itself can extend into and encroach upon the mitral orifice area, obstructing diastolic transmitral inflow, hence causing some degree of MS ([Figure 2](#)). This mechanism often takes the form of a “shelf” of calcium at the base of the mitral leaflets that displaces the leaflets into the valve orifice.¹⁷ Calcium extension onto the leaflets, particularly the anterior mitral leaflet, further restricts leaflet motion, resulting in more severe stenotic physiology.¹⁸ In this regard, the mechanism of inflow obstruction in MAC represents an important distinction from rheumatic MS ([Figure 3](#)). In the latter condition, commissural fusion results in a funnel-shaped valve maximally stenotic at the leaflet tips. In contrast, in MAC-related MV dysfunction, the level of obstruction is typically closer to the annular level, with leaflets forming more of a tubular shape.^{17,19} Less commonly, in some cases leaflet encroachment can result in decreased leaflet

TABLE 1 Proposed Multiparametric Grading Systems of MAC Anatomical Severity

Eleid et al ²¹			Xu et al ²²			
MAC Grade	Annulus	Extra-Annular Calcium	MAC Grade	Qualitative Echocardiographic Grading	Quantitative CT Grading	Special Features
Grade 1 (mild)	Focal noncontiguous calcification limited to <180° total annular circumference	None	Grade 1	<90° and noncontiguous	<1,000 Agatston units	None
			Grade 2	90°-<180°	1,000-<3,000 Agatston units	Calcification of subvalvular structures and leaflets by CT Involvement of one trigone
Grade 2 (moderate)	Dense continuous calcification limited to <270° total annular circumference	Posterior and/or anterior leaflet calcification may be present	Grade 3	180°-<270°	3,000-5,000 Agatston units	Extension into LVOT Mobile MAC Involvement of both trigones
Grade 3 (severe)	Dense continuous calcification extending past the commissures into anterior annulus or complete circumferential MAC (≥270° calcification arc)	Posterior and/or anterior leaflet calcification may be present Papillary muscle or ventricular myocardial calcification may be present	Grade 4	270° to circumferential	>5,000 Agatston units	Heavy extension into LVOT Infiltration into myocardium

CT = computed tomographic; LVOT = left ventricular outflow tract; MAC = mitral annular calcification.

excursion and a reduced opening angle, resulting in a level of obstruction slightly more apically displaced below the annular plane.²⁰

DIAGNOSTIC EVALUATION AND CHALLENGES

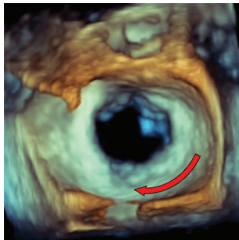
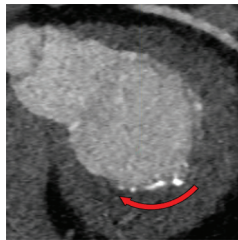

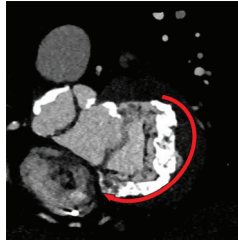

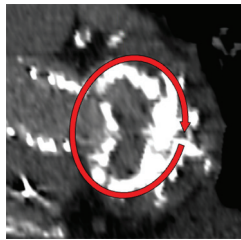
The diagnostic evaluation of MAC-related MV dysfunction centers on defining 2 key features: 1) the anatomical extent of the calcium; 2) the impact on valve function. Significant MAC is often noted incidentally on fluoroscopy as part of other cardiac procedures, but this modality provides only very limited diagnostic information and best serves as to prompt additional imaging. More comprehensive anatomical assessment can be performed using both echocardiography and CT, with the latter modality additionally allowing quantification of calcium burden using the Agatston score. CT provides a high degree of spatial resolution to definitively visualize the location and circumferential extent of the calcium, most typically done through the use of multiplanar reconstruction to create a short-axis view of the mitral annulus, in addition to determining the degree of calcium extension on the valve leaflets or into the subvalvular apparatus or the basal ventricular myocardium.²¹ Two recent scoring systems have been proposed to standardize assessment of the anatomical burden of annular calcium (Table 1, Figure 4), one focused on a qualitative assessment of calcium extent²¹ and the other additionally incorporating quantitative assessment with the Agatston score²²; both also feature an assessment of the extent of extra-annular calcium. Notwithstanding some small differences, these 2 grading systems largely overlap, and there is no

consensus as to optimal grading approach or definitions. A key limitation of this anatomical assessment, however, is the absence of information on the hemodynamic impact of the valvular lesion, and the prognostic implications of these different grading schema of MAC extent remain largely undefined, making this a key area of future research.

The role of other cross-sectional imaging modalities in the diagnostic evaluation of MAC remains limited. Dedicated positron emission tomographic protocols have been shown to image MAC disease activity (calcification and inflammation) and predict disease progression, although targeted therapies are not yet available.²³ Magnetic resonance imaging, in turn, is less well suited for imaging calcified structures and serves primarily as an adjunct assessment of MR severity.

A limited but important role for both CT and magnetic resonance imaging lies in the provision of anatomical evaluation and diagnostic clarity in cases of caseous MAC, which differs considerably from the other types of MAC. Caseous MAC refers to an inflammatory process with liquefactive necrosis of the annular calcium²¹ and is of unclear etiology and uncertain clinical significance. It appears on echocardiography as a smooth and reflective outer rim that surrounds an echolucent necrotic core and can be confused with cardiac tumors, particularly when large and mass-like.¹⁷ Caseous MAC is less often associated with significant valve dysfunction and can spontaneously regress or even disappear, presumably because of erosion or rupture of the shell with embolization of the necrotic core. In this setting, caseous MAC is thought to relate to an increased risk

FIGURE 4 Imaging Grading of Mitral Annular Calcium

	Calcium Burden	Echocardiography	Computed Tomography
Mild	<p><i>Eleid: Grade 1</i></p> <p><180° annulus</p> <p><i>Xu: Grades 1-2</i></p>		
Moderate	<p><i>Eleid: Grade 2</i></p> <p>180° to 270°</p> <p><i>Xu: Grade 3</i></p>		
Severe	<p><i>Eleid: Grade 3</i></p> <p>270° to circumferential</p> <p><i>Xu: Grade 4</i></p>		

Two recent imaging grading systems have been proposed to standardize assessment of the anatomical burden of annular calcium.^{21,22} Both scoring systems focus largely on the circumferential extent of calcium around the mitral annulus, in addition to including features such as the Agatston score and the degree of extra-annular calcium (not depicted).



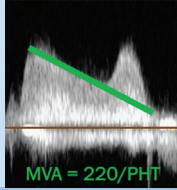
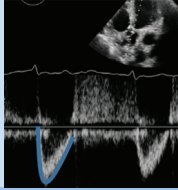
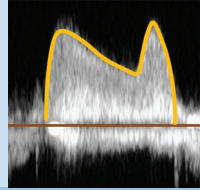
for stroke. Both CT and magnetic resonance imaging can be helpful in establishing a correct diagnosis, avoiding overtreatment and/or unnecessary surgical referral.²²

Despite significant challenges, echocardiography remains the preferred method for defining the degree and type of valvular dysfunction in patients with MAC. In patients with stenotic physiology, the echocardiographic severity assessment relies on the TMG and on calculation of MVA. However, unlike in rheumatic MS, most metrics for MVA calculation by echocardiography cannot be directly applied in significant MAC, because of imaging challenges (Figure 5), concomitant valvular abnormalities, and comorbid ventricular alterations.

Direct planimetry by 2-dimensional echocardiography, the gold standard for rheumatic MS, is not a

reliable metric for MAC-related MV dysfunction. Because of the lack of commissural fusion, the limiting orifice in MAC is typically nonplanar and located closer to the calcified annular plane rather than at the leaflet tips (Figure 3). This area is difficult to visualize, particularly in patients with significant acoustic shadowing from anterior calcium. Three-dimensional echocardiography can overcome some of these limitations and is a promising technique for MVA evaluation in patients with MAC¹⁹ but presents substantial difficulties for use in daily clinical care. The pressure half-time method, in turn, has limited validity in the setting of abnormal LV and left atrial compliance, tending to overestimate MVA in patients with decreased LV compliance,²⁴ which is common in an elderly MAC population. The proximal isovelocity surface area method for effective orifice area

FIGURE 5 Challenges of Echocardiographic Assessment in MAC-Related MV Dysfunction

	Mitral Valve Area (MVA)			Pressure Gradient	
	2D Planimetry	3D Planimetry	Pressure Half-Time (PHT)	Continuity Equation	Mean Pressure Gradient
			 MVA = 220/PHT		
Description	Direct planimetry of the valve opening orifice	Planimetry of MVA from 3D dataset	Empiric calculation extrapolated from rheumatic MS	Calculates MVA based on MV flow and LVOT stroke volume	Mean pressure gradient using continuous wave doppler
Limitations	Poor image quality in presence of MAC	TTE images often inadequate, need for TEE	Overestimates MVA in case of decreased LA/LV compliance	Unreliable in moderate or more MR or AR, irregular rhythms	Flow dependent (heart rate and rhythm, high output states)
Challenges in MAC	Orifice nonplanar, not located at leaflet tips Shadowing due to calcium	Technically difficult Time consuming Acoustic shadowing	MAC population often LVH, AS, decreased compliance	MAC is typically "mixed" VHD, with often some degree of MR; AF common	Heart rate Impact of diastolic dysfunction

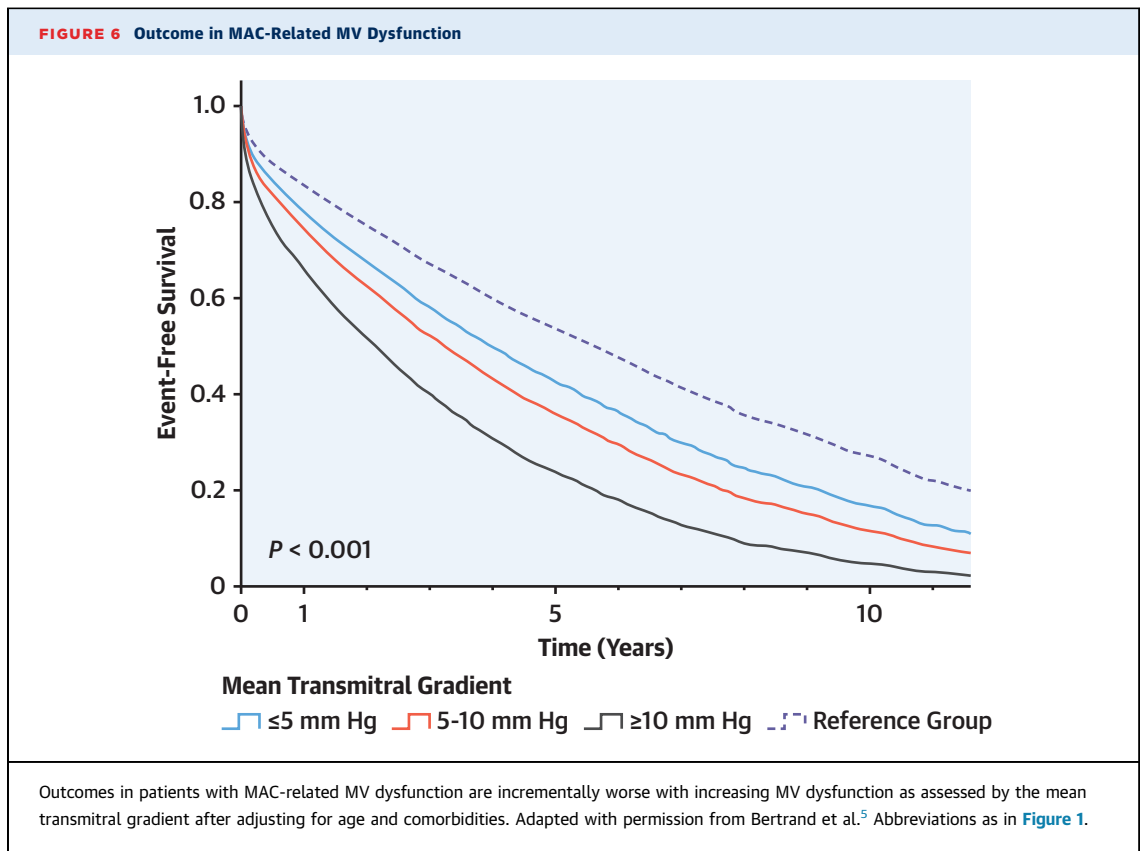
There are multiple important challenges of echocardiographic assessment of MAC-related MV dysfunction. Many metrics extrapolated from rheumatic disease have limitations in patients with significant MAC and associated comorbidities. The transmitral gradient is one metric that integrates the hemodynamic impact of both stenosis and regurgitation and has independent prognostic value in this population. 2D = 2-dimensional; 3D = 3-dimensional; AF = atrial fibrillation; AR = aortic regurgitation; AS = aortic stenosis; LVH = left ventricular hypertrophy; LVOT = left ventricular outflow tract; MR = mitral regurgitation; MS = mitral stenosis; TEE = transesophageal echocardiography; TTE = transthoracic echocardiographic; VHD = valvular heart disease; other abbreviation as in Figures 1, 2, and 3.

calculation, finally, also has limited applicability, because of the noncircular (crescent-like) inflow orifice in MAC and its inherent complexity and technical difficulty.²¹ In light of these limitations, the continuity equation is probably the best technique to calculate the valve area in MAC, bearing in mind inaccuracy in patients with significant (moderate or greater) aortic or MR or with atrial fibrillation (given need to measure LV outflow tract [LVOT] and transmitral flow in different cardiac cycles).

With MR, in turn, metrics for severity assessment are similar to those used in other etiologies. The principal challenge here is acoustic shadowing from annular calcium, which can frequently limit visualization of the regurgitant jet. Clinicians should accordingly maintain a high index of suspicion for the possibility of underappreciated MR, including careful evaluation in transthoracic echocardiographic views less affected by acoustic shadowing. For this reason,

transesophageal echocardiography (TEE) is appropriate if significant MR is suspected, and MR quantification is particularly encouraged if imaging is adequate.

Given the limitations and complexities of many diagnostic approaches and the elevated prevalence of mixed MV disease in MAC, we propose to not rely on one single echocardiographic measure of MVA but also focus upon the TMG as a metric that integrates the severity of MV dysfunction encompassing both regurgitation and stenosis. The TMG has powerful prognostic importance, independent of age, sex, and cardiovascular comorbidities, and additionally is easily acquired and does not require advanced expertise or processing capability.⁵ Well-known limitations of the TMG include its flow dependency, being affected by changes in heart rate, cardiac output, and rheologic factors such as hematocrit or hemoglobin level. Nonetheless, the prognostic value of the



TMG is robust to these limitations,⁵ although common sense dictates that extreme cases (eg, marked tachycardia, anemia, low-output heart failure) are not the best settings in which to perform this hemodynamic assessment. A “flow-corrected” or projected TMG was proposed by Kato et al²⁵ to help account for this limitation, which may yield a helpful metric in selected patients.

Finally, assessment of LV diastolic function and in particular the estimation of LV filling pressures is subject to limitations in patients with MAC, primarily because the annular calcium impairs annular velocity assessment by tissue Doppler imaging (e').²⁶ These challenges in assessing diastolic filling in the setting of significant MAC point to a particularly salient point in this population, which is the difficulty of separating valve from ventricle in teasing out the driver of symptoms and disease mechanisms.²⁷ Among patients with elevated TMG, for instance, it is challenging to parse out to what extent the abnormality is driven by MV dysfunction itself rather than by ventricular relaxation abnormalities, a challenge particularly salient given the high prevalence of comorbid heart failure with preserved ejection fraction (HFpEF) among patients with MAC-related MV dysfunction.

This has important implications on patient management, and additional mechanism-oriented research, ideally coupling echocardiographic with careful hemodynamic assessment, is required to better understand this important topic.

Integrating the diverse available forms of functional and anatomical imaging in the diagnostic evaluation and management of patients with MAC-related MV dysfunction is challenging and has been the focus of several excellent reviews.^{17,21,22,28,29} Viewed broadly, the role of different imaging modalities relates primarily to the stage of patient care, from diagnosis to assessment of MV dysfunction to evaluation and planning for potential intervention. CT is highly sensitive for detection of MAC and, as noted earlier, provides optimal resolution of the anatomical extent of the calcium, but the importance of this information is limited until the patient is being evaluated for intervention because of symptomatic, severe MV dysfunction. Hemodynamic assessment by transthoracic echocardiography, in turn, is the cornerstone of severity determination, although an integrative approach is necessary given limitations to almost all echocardiographic metrics (Figure 5). In patients with exertional symptoms out of proportion

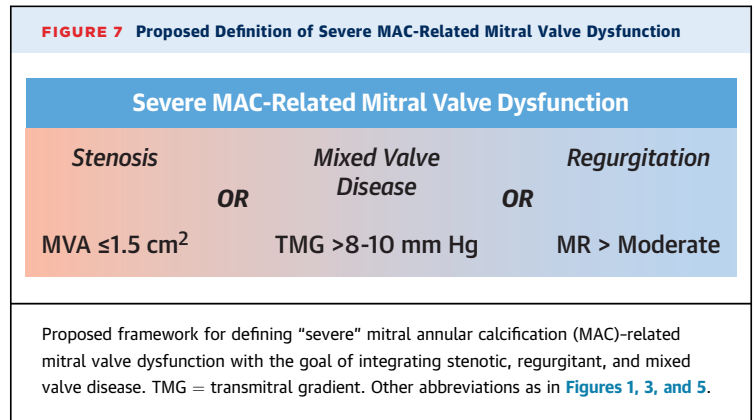
to the resting indexes of MV dysfunction, exercise echocardiography can be considered to evaluate the hemodynamic impact of the MAC-related MV dysfunction during exercise.³⁰ TEE serves a complementary role for severity assessment or clarification of mechanism, particularly in symptomatic patients in whom transthoracic echocardiographic imaging quality is limited by acoustic shadowing, which often impairs visualization of valve leaflets and complicates the quantification of regurgitant jets. TEE also plays a central role in the evaluation of candidacy for surgery or transcatheter procedures, as well as in periprocedural guidance.²⁹

Finally, in patients with severely symptomatic MAC-related MV dysfunction, cardiac CT plays a crucial role in preintervention planning. CT is central in preoperative evaluation for patients deemed to be surgical candidates, whether for traditional repair or replacement or, more recently, open (direct) implantation of transcatheter valves in the mitral position. CT is similarly essential in defining anatomical eligibility for potential transcatheter procedures, including predicting risk for adverse outcomes during these procedures (eg, device embolization)³¹ and calculating the “neo-LVOT,” the minimal LVOT area that is expected after transcatheter valve deployment.³² This “neo-LVOT” is a powerful predictor of the risk for postprocedural LVOT obstruction, a common and potentially catastrophic complication of valve-in-MAC procedures.^{28,33}

MAC-RELATED MV DYSFUNCTION AND CLINICAL OUTCOMES

Until recently, data on clinical outcomes in patients with MAC-related MV dysfunction have been limited, at least in part because of the absence of broadly accepted diagnostic criteria. Overall, though, the adverse prognosis associated with MAC-related MV dysfunction is well established. In a cohort of patients with MAC and MS reported by Pasca et al,¹³ survival rates at 1, 5, and 10 years were 78%, 47%, and 25% and were worse depending upon the severity of MV dysfunction. Similarly, a large cohort of individuals with stenotic, regurgitant, or mixed MV disease reported 1-, 5-, and 10-year survival rates of 75%, 40%, and 18%, with survival markedly impaired in the high-gradient (≥ 10 mm Hg) group (67% at 1 year, 25% at 5 years, and 11% at 10 years) (Figure 6).⁵

Within much of the spectrum of MAC-related MV dysfunction, additive MR on top of inflow obstruction appears to worsen outcome,^{5,13} as does the presence



of comorbid valve disease such as aortic stenosis and tricuspid regurgitation.¹³ Among individuals with markedly elevated TMG (≥ 10 mm Hg), however, this impact appears to be attenuated, likely because of the already adverse hemodynamic impact of the gradient elevation and the very poor prognosis in this population.⁵ Greater anatomical severity of the MAC itself, likely a marker for more advanced disease, has also been associated with more rapidly progressive valvular dysfunction¹⁵ and worse prognosis.^{3,6} Finally, elevated pulmonary artery pressures have been linked to worse outcomes controlling for the severity of MV dysfunction, with increased mortality with pulmonary pressures >50 mm Hg.³⁴

At present, there are no broadly accepted criteria for defining severity of MAC-related MV dysfunction. On the basis of currently available outcome data^{5,34} and the inclusion criteria in ongoing intervention studies (MITRAL II [Mitral Implantation of Transcatheter Valves]; NCT04408430), we propose a unifying definition of “severe” MAC-related MV dysfunction, integrating stenotic, regurgitant, or mixed disease, as MVA ≤ 1.5 cm² or more than moderate MR or TMG $>8-10$ mm Hg at a normal heart rate (Figure 7).

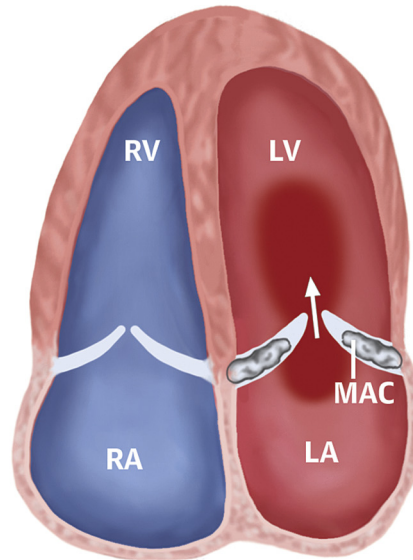
There are also well-established associations between MAC and stroke, but the extent to which these are causal or related to the MV dysfunction remains uncertain. Epidemiologic links between MAC and stroke have been described for many years,⁶ with a potential pathophysiologic connection in terms of atherosclerosis but also an increased risk for atrial fibrillation in patients with MAC.³⁵ Degenerative changes of the MAC itself can also serve as a source of embolus. A link between the valve dysfunction and incident atrial fibrillation or stroke has not been established, although there is a plausible mechanism due to increased left atrial pressures.

CENTRAL ILLUSTRATION Cardinal Features of Mitral Annular Calcification-Related Mitral Valve Dysfunction**Mitral Annular Calcification (MAC)-Related Mitral Valve Dysfunction (MVD)****Epidemiology**

- **MAC: 8%-15% of population**
- **MVD: in 8%-16% of MAC patients**
- **Often mixed stenosis and regurgitation**
- **Female predominance**
- **Associated with comorbidities**

Diagnosis

- **MAC Extent: Multimodality**
- **MVD Severity: Echocardiography**
 - Transmitral gradient (TMG)
 - MVA by continuity equation or 3D (PHT & 2D planimetry not reliable)
 - MR severity, pulmonary pressure
- **"Severe MVD": MVA $\leq 1.5\text{cm}^2$ or TMG $>8\text{-}10$ mm Hg or $>$ moderate MR**

**Prognosis & Outcomes**

- **Poor outcome in MAC (comorbidities)**
- **Incremental mortality with MVD related to MVD severity**
- **At TMG >10 mm Hg:**
 - 1 year survival $<70\%$
 - 5 year survival 25%

Management

- **Medical Therapy:**
 - Diuretics
 - Rate control
 - HFpEF therapy
 - **Valvular Intervention*:**
 - Surgery
 - Transcatheter ("Valve-in-MAC")
- *Case-by-case discussion in comprehensive Heart Valve Team*

Stenosis Mixed Disease Regurgitation

Churchill TW, et al. J Am Coll Cardiol. 2022;80(7):739-751.

Mitral valve (MV) dysfunction related to mitral annular calcification (MAC) encompasses a range of valvular pathology from stenosis to regurgitation to mixed valvular disease. Key features of MAC-related MV dysfunction including epidemiology, diagnostic approach, prognosis, and management are shown. 2D = 2-dimensional; 3D = 3-dimensional; HFpEF = heart failure with preserved ejection fraction; MAC = mitral annular calcification; MVA = mitral valve area; MVD = mitral valve dysfunction; PHT = pressure half-time; RA = right atrium; RV = right ventricle; Rx = medication; TMG = transmitral gradient; w/ = with.

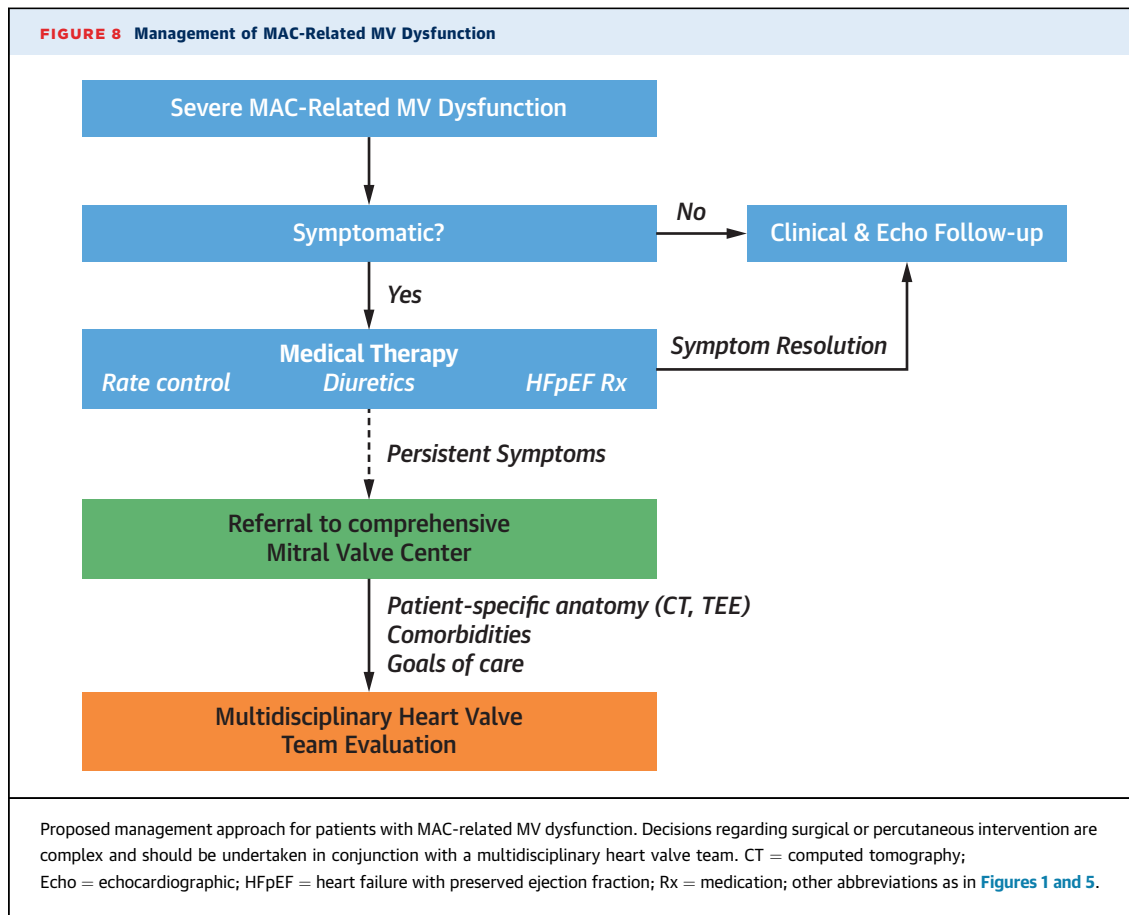
MANAGEMENT

The cornerstone of treatment of MAC-related MV dysfunction remains medical management with diuretic therapy and, if there is significant inflow obstruction, heart rate control with the goal of optimizing diastolic filling time (**Central Illustration**). Underlying HFpEF is common in this population, and therapies with established benefit in HFpEF should be considered.

Valvular interventions to directly address the valvular dysfunction, including surgery and transcatheter interventions such as valve-in-MAC and in limited circumstances edge-to-edge repair, are technically challenging and associated with a high degree

of morbidity and mortality in this population.³³ Even after a successful procedure with significant reduction in transvalvular gradient, the mean left atrial pressure may remain elevated in the setting of poor left atrial and LV compliance, as is common in an elderly HFpEF population.²⁷ Therefore, only a subset of patients will benefit from valvular intervention, and this assessment is based on integration of patient-specific anatomical considerations, comorbidity burden, and patient goals of care and should be discussed on a case-by-case basis by the multidisciplinary heart valve team.³⁶

In routine clinical practice, patients with MAC to consider for referral to a comprehensive valve center are those with severe symptoms refractory to medical



therapy, when symptoms are related to severe MAC-related valve dysfunction as based on an integrated clinical and imaging assessment ([Figure 8](#)). Detailed discussion of the full spectrum of procedural options for patients with MAC-related MV dysfunction is beyond the scope of this review, and the current state of both surgical³⁷ and percutaneous³⁸ approaches^{37,39} as well as the wide range of emerging devices⁴⁰ have been summarized previously.

FUTURE DIRECTIONS

Decades of research has established that MAC is associated with significant cardiovascular comorbidity, while more recent efforts have expanded our understanding of the degree to which MAC-associated MV dysfunction is itself an important driver of adverse outcomes. Looking ahead, a key path of future research will be to better define which patients are likely to benefit from the emerging array of valvular interventions. This will require a greater ability to dissect the contribution of valvular dysfunction from the underlying comorbidity burden and ventricular abnormalities, as well as prospective

randomized outcomes trials. The ongoing MITRAL II pivotal trial plans to recruit 110 patients at high operative risk with severely symptomatic MAC-related MV dysfunction (defined as severe MAC with MVA ≤ 1.5 cm² and/or more than moderate MR) for transseptal valve-in-MAC implantation. The trial is not randomized but will include a registry of 100 patients with untreated MAC managed conservatively. Along the same lines, an additional area of focus must be on evaluation of MAC-related MV dysfunction earlier in the disease course than most patients typically present to clinical attention presently. An improved understanding of prognostic markers and disease activity might allow more prompt diagnosis and, possibly, either modification of disease course or earlier intervention while the risk profile of doing so remains viable.

CONCLUSIONS

MAC-related MV dysfunction is increasing in prevalence as the population ages and is associated with worse prognosis on top of already significant morbidities. The diagnostic assessment of valve

dysfunction severity is often challenging because of mixed valvular pathology, in which case the pressure gradient can be useful for prognostication. Valvular interventions to address severe MAC-related MV dysfunction demand careful discussion by the multidisciplinary heart valve team, on the basis of dedicated anatomical imaging and patient goals of care. Further research is needed to establish metrics for risk stratification and evidence-based indications for intervention in this challenging population.

FUNDING SUPPORT AND AUTHOR DISCLOSURES

This study was supported in part by a grant from the Ellison Foundation and by National Institutes of Health grant R01 HL141917 (Drs Levine and Hung). The authors have reported that they have no relationships relevant to the contents of this paper to disclose.

ADDRESS FOR CORRESPONDENCE: Dr Philippe B. Bertrand, Ziekenhuis Oost-Limburg, Schiepse Bos 6, Genk, Belgium. E-mail: philippe.bertrand@zol.be. Twitter: @Ph_Bertrand, @TimChurchillMD.

REFERENCES

- Abramowitz Y, Jilalawi H, Chakravarty T, Mack MJ, Makkar RR. Mitral annulus calcification. *J Am Coll Cardiol*. 2015;66:1934–1941.
- Silbiger JJ. Anatomy, mechanics, and pathophysiology of the mitral annulus. *Am Heart J*. 2012;164:163–176.
- Fox CS, Vasan RS, Parise H, et al. Mitral annular calcification predicts cardiovascular morbidity and mortality. *Circulation*. 2003;107:1492–1496.
- Barasch E, Gottdiener JS, Larsen EK, Chaves PH, Newman AB, Manolio TA. Clinical significance of calcification of the fibrous skeleton of the heart and aortosclerosis in community dwelling elderly. The Cardiovascular Health Study (CHS). *Am Heart J*. 2006;151:39–47.
- Bertrand PB, Churchill TW, Yucel E, et al. Prognostic importance of the transmitral pressure gradient in mitral annular calcification with associated mitral valve dysfunction. *Eur Heart J*. 2020;41(45):4321–4328.
- Benjamin EJ, Plehn JF, D'Agostino RB, et al. Mitral annular calcification and the risk of stroke in an elderly cohort. *N Engl J Med*. 1992;327:374–379.
- Elmariah S, Budoff MJ, Delaney JA, et al. Risk factors associated with the incidence and progression of mitral annulus calcification: the Multi-Ethnic Study of Atherosclerosis. *Am Heart J*. 2013;166:904–912.
- Sud K, Agarwal S, Parashar A, et al. Degenerative mitral stenosis: unmet need for percutaneous interventions. *Circulation*. 2016;133:1594–1604.
- Labovitz AJ, Nelson JG, Windhorst DM, Kennedy HL, Williams GA. Frequency of mitral valve dysfunction from mitral annular calcium as detected by Doppler echocardiography. *Am J Cardiol*. 1985;55:133–137.
- Kato N, Guerrero M, Scott CG, et al. The prevalence and natural history of mitral annulus calcification. *Eur Heart J*. 2020;41(suppl 2):ehaa946, 2010.
- Bertrand PB, Mihos CG, Yucel E. Mitral annular calcification and calcific mitral stenosis: therapeutic challenges and considerations. *Curr Treat Options Cardiovasc Med*. 2019;21:19.
- Iwataki M, Takeuchi M, Otani K, et al. Calcific extension towards the mitral valve causes non-rheumatic mitral stenosis in degenerative aortic stenosis: real-time 3D transoesophageal echocardiography study. *Open Heart*. 2014;1:e000136.
- Pasca I, Dang P, Tyagi G, Pai RG. Survival in patients with degenerative mitral stenosis: results from a large retrospective cohort study. *J Am Soc Echocardiogr*. 2016;29:461–469.
- Uchimuro T, Fukui T, Shimizu A, Takanashi S. Mitral valve surgery in patients with severe mitral annular calcification. *Ann Thorac Surg*. 2016;101:889–895.
- Tsutsui RS, Banerjee K, Kapadia S, Thomas JD, Popovic ZB. Natural history of mitral stenosis in patients with mitral annular calcification. *J Am Coll Cardiol Img*. 2019;12:1105–1107.
- Pressman GS, Movva R, Topilsky Y, et al. Mitral annular dynamics in mitral annular calcification: a three-dimensional imaging study. *J Am Soc Echocardiogr*. 2015;28:786–794.
- Silbiger JJ. Mitral annular calcification and calcific mitral stenosis: role of echocardiography in hemodynamic assessment and management. *J Am Soc Echocardiogr*. 2021;34:923–931.
- Muddassir SM, Pressman GS. Mitral annular calcification as a cause of mitral valve gradients. *Int J Cardiol*. 2007;123:58–62.
- Chu JW, Levine RA, Chua S, et al. Assessing mitral valve area and orifice geometry in calcific mitral stenosis: a new solution by real-time three-dimensional echocardiography. *J Am Soc Echocardiogr*. 2008;21:1006–1009.
- Movva R, Murthy K, Romero-Corral A, Seetha Rammohan HR, Fumo P, Pressman GS. Calcification of the mitral valve and annulus: systematic evaluation of effects on valve anatomy and function. *J Am Soc Echocardiogr*. 2013;26:1135–1142.
- Eleid MF, Foley TA, Said SM, Pislaru SV, Rihal CS. Severe mitral annular calcification: multimodality imaging for therapeutic strategies and interventions. *J Am Coll Cardiol Img*. 2016;9:1318–1337.
- Xu B, Kocyigit D, Wang TKM, et al. Mitral annular calcification and valvular dysfunction: multimodality imaging evaluation, grading, and management. *Eur Heart J Cardiovasc Imaging*. 2022;23(3):e111–e122.
- Massera D, Trivieri MG, Andrews JPM, et al. Disease activity in mitral annular calcification. *Circ Cardiovasc Imaging*. 2019;12:e008513.
- Karp K, Teien D, Bjerle P, Eriksson P. Reassessment of valve area determinations in mitral stenosis by the pressure half-time method: impact of left ventricular stiffness and peak diastolic pressure difference. *J Am Coll Cardiol*. 1989;13:594–599.
- Kato N, Pislaru SV, Padang R, et al. A novel assessment using projected transmitral gradient improves diagnostic yield of Doppler hemodynamics in rheumatic and calcific mitral stenosis. *J Am Coll Cardiol Img*. 2021;14:559–570.
- Abudiyab MM, Chebroul LH, Schutt RC, Nagueh SF, Zoghbi WA. Doppler echocardiography for the estimation of LV filling pressure in patients with mitral annular calcification. *J Am Coll Cardiol Img*. 2017;10:1411–1420.
- Reddy YNV, Murgu JP, Nishimura RA. Complexity of defining severe “stenosis” from mitral annular calcification. *Circulation*. 2019;140:523–525.
- Little SH, Bapat V, Blanke P, Guerrero M, Rajagopal V, Siegel R. Imaging guidance for transcatheter mitral valve intervention on prosthetic valves, rings, and annular calcification. *J Am Coll Cardiol Img*. 2021;14:22–40.
- Mackensen GB, Lee JC, Wang DD, et al. Role of echocardiography in transcatheter mitral valve replacement in native mitral valves and mitral rings. *J Am Soc Echocardiogr*. 2018;31:475–490.
- Lancellotti P, Pellikka PA, Budts W, et al. The clinical use of stress echocardiography in non-ischaemic heart disease: recommendations from the European Association of Cardiovascular Imaging and the American Society of Echocardiography. *J Am Soc Echocardiogr*. 2017;30:101–138.
- Guerrero M, Wang DD, Pursnani A, et al. A cardiac computed tomography-based score to categorize mitral annular calcification severity and predict valve embolization. *J Am Coll Cardiol Img*. 2020;13:1945–1957.
- Reid A, Ben Zekry S, Turaga M, et al. Neo-LVOT and transcatheter mitral valve replacement: expert recommendations. *J Am Coll Cardiol Img*. 2021;14:854–866.
- Guerrero M, Dvir D, Himbert D, et al. Transcatheter mitral valve replacement in native mitral valve disease with severe mitral annular calcification: results from the first multicenter global registry. *J Am Coll Cardiol Intv*. 2016;9:1361–1371.

34. Kato N, Padang R, Scott CG, Guerrero M, Pislaru SV, Pellikka PA. The natural history of severe calcific mitral stenosis. *J Am Coll Cardiol*. 2020;75:3048-3057.
35. O'Neal WT, Efrid JT, Nazarian S, et al. Mitral annular calcification progression and the risk of atrial fibrillation: results from MESA. *Eur Heart J Cardiovasc Imaging*. 2018;19:279-284.
36. Writing Committee Members, Otto CM, Nishimura RA, et al. 2020 ACC/AHA guideline for the management of patients with valvular heart disease: a report of the American College of Cardiology/American Heart Association Joint Committee on Clinical Practice Guidelines. *J Am Coll Cardiol*. 2021;77:e25-e197.
37. Bedeir K, Kaneko T, Aranki S. Current and evolving strategies in the management of severe mitral annular calcification. *J Thorac Cardiovasc Surg*. 2019;157:555-566.
38. Alperi A, Granada JF, Bernier M, Dagenais F, Rodes-Cabau J. Current status and future prospects of transcatheter mitral valve replacement: JACC state-of-the-art review. *J Am Coll Cardiol*. 2021;77:3058-3078.
39. Urena M, Vahanian A, Brochet E, Ducrocq G, lung B, Himbert D. Current indications for transcatheter mitral valve replacement using transcatheter aortic valves: valve-in-valve, valve-in-ring, and valve-in-mitral annulus calcification. *Circulation*. 2021;143:178-196.
40. Regueiro A, Granada JF, Dagenais F, Rodes-Cabau J. Transcatheter mitral valve replacement: insights from early clinical experience and future challenges. *J Am Coll Cardiol*. 2017;69:2175-2192.

KEY WORDS MAC-related mitral valve dysfunction, mitral annular calcification, mitral regurgitation, mitral stenosis, transcatheter mitral valve replacement