


Cite this article as: Yilmaz A, Van Genechten S, Claessens J, Packlé L, Maessen J, Kaya A. A totally endoscopic approach for aortic valve surgery. Eur J Cardiothorac Surg 2022; doi:10.1093/ejcts/ezac467.

A totally endoscopic approach for aortic valve surgery

Alaaddin Yilmaz ^{a,*}, Silke Van Genechten^{a,†}, Jade Claessens^{a,b}, Loren Packlé^a, Jos Maessen^c
and Abdullah Kaya^{a,b}

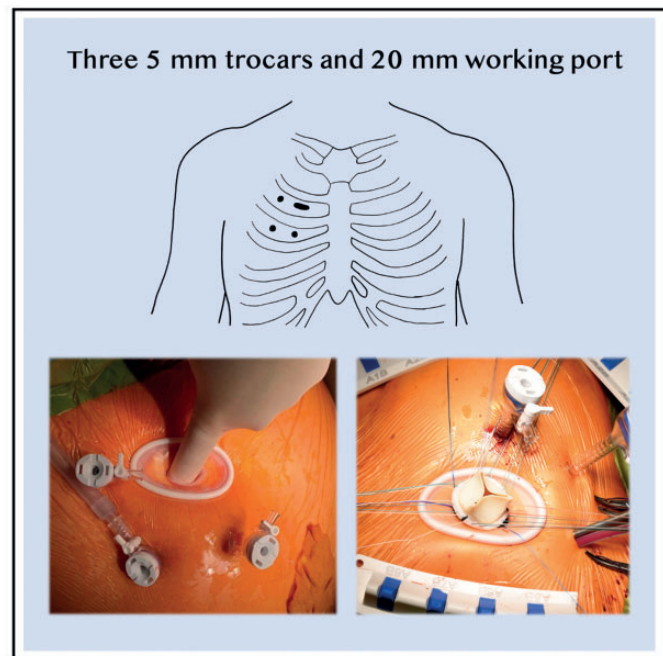
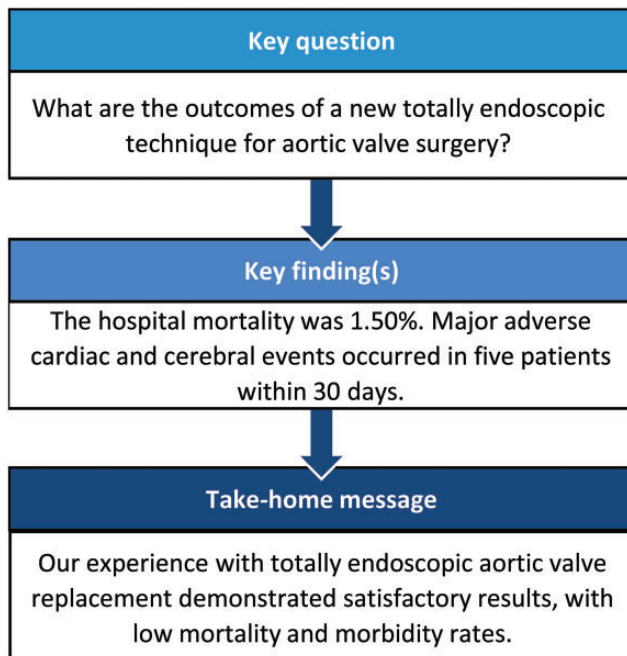
^a Department of Cardiothoracic Surgery, Jessa Hospital, Stadsomvaart 11, 3500 Hasselt, Belgium

^b UHasselt - Hasselt University, Faculty of Medicine and Life Sciences - LCRC, Agoralaan, 3590 Diepenbeek, Belgium

^c Department of Cardiothoracic Surgery, Heart and Vascular Centre, Maastricht University Medical Centre, P. Debyelaan 25, 6229 HX Maastricht, The Netherlands

* Corresponding Author.; Stadsomvaart 11, 3500 Hasselt/Belgium, Tel: +3211337104; e-mail: alaaddin.yilmaz@jessazh.be (A.Yilmaz).

Received 16 March 2022; received in revised form 8 June 2022; accepted 26 September 2022



Abstract

OBJECTIVES: Our goal was to describe a new approach for totally endoscopic aortic valve replacement.

METHODS: From October 2017 through December 2020, a total of 266 consecutive patients underwent totally endoscopic aortic valve replacement. Reoperations and combinations were excluded.

RESULTS: A total of 266 patients with a median age of 72 (64, 79) years underwent totally endoscopic aortic valve replacement; of these, 250 (93.98%) patients were designated to undergo surgery because of aortic valve stenosis. The median follow-up index was 0.69 (0.30, 0.90). Major adverse cardiac and cerebrovascular events occurred in 4 (1.50%) patients within 30 days. Overall hospital mortality was 1.50%. Twenty additional deaths (7.52%) occurred during the 3-year follow-up period. An early thoracoscopic revision was needed in 7 patients due to signs of bleeding or cardiac tamponade. Fourteen patients required a permanent pacemaker implant.

[†]The first two authors contributed equally to this study.

CONCLUSIONS: Retrospective analysis of our early experience with totally endoscopic aortic valve replacement in 266 consecutive patients demonstrated satisfactory results, with low mortality and acceptable morbidity rates.

Keywords: endoscopic • valvular surgery • aortic valve

ABBREVIATIONS

AVR	aortic valve replacement
CPB	cardiopulmonary bypass
CT	computed tomography
MACCE	major adverse cardiac and cerebrovascular events
MiECC	minimally invasive extracorporeal circulation
RALT	right anterolateral minithoracotomy
TEAVR	totally endoscopic aortic valve replacement
TEE	transesophageal echocardiography
TTE	transthoracic echocardiography

INTRODUCTION

Minimally invasive cardiac surgery is evolving progressively. Cosgrove *et al.* described the first minimally invasive aortic valve replacement (AVR) via a ministernotomy [1]. Nowadays, ministernotomy is the preferred surgical approach in many cardiac centres for isolated aortic valve pathology. The idea of a non-full sternotomy approach resulted in new minimally invasive techniques for AVR like the right anterolateral minithoracotomy and right anterior minithoracotomy [2–4]. Current European guidelines advocate a transcatheter aortic valve implant for patients older than 75 years of age or low-risk patients [5]. However, evidence for the long-term durability and the application in different anatomical situations in younger patients is sparse.

Further efforts resulted in the first totally endoscopic approach for AVR (TEAVR) reported by Vola *et al.* in 2014 [6]. Despite the acceptable initial clinical results, this technique did not evolve as expected due to limited indications and longer clamping and cardiopulmonary bypass (CPB) times [6]. Since then, only several sporadic reports or small cohorts of endoscopic AVR have been reported [7–9].

In our centre, the Jessa Hospital, Hasselt, Belgium, a non-university tertiary institution, elective AVR has been performed through ministernotomy since 2005. Thanks to the knowledge and skills built up in totally endoscopic mitral valve surgery and endoscopic bypass surgery, the first steps to TEAVR were set [10]. This report describes our initial experience with TEAVR in the first 266 patients.

PATIENTS AND METHODS

Ethical statement

This retrospective cohort study was approved by the local ethics committee of the Jessa Hospital Belgium (20.88-carchir20.01) on 8 September 2020. No written informed consent was needed due to the retrospective nature of the study.

Patients

From October 2017 through December 2020, an unselected group who had consecutive surgical AVR was included in this

study. These were all patients operated on by the lead surgeon (A.Y). In his absence, 20 urgent ministernotomies were performed. Previous cardiac surgery, ministernotomy, sutureless valve implantation or combination operations were excluded.

Procedure

All procedures are performed with the patient under general anaesthesia. The patients are placed in a supine position and receive a single-lumen endotracheal tube, a central venous catheter, a radial artery catheter, a peripheral intravenous line and external defibrillating pads. Near-infrared oxygenation monitoring pads are placed at the patient's forehead, and a transoesophageal echocardiography (TEE) probe is inserted.

The first 5-mm air-sealed trocar is introduced approximately 2 cm below the anterior axillary line in the third intercostal space and used for the 0-degree endoscope (5 mm, Karl Storz, Tuttlingen, Germany) (Fig. 1). This initial trocar is introduced during a short period of apnoea followed by CO₂-insufflation using the trocar's side port, creating a pneumothorax of 6–8 mmHg to facilitate an adequate working space and avoid selective lung ventilation.

A working port is created by a 15- to 20-mm skin incision through the second intercostal space, large enough for the width of an index finger (Fig. 1). The pectoral muscle is divided in line with the muscle fibres, and an extra small soft tissue retractor (Shanghai International Holding Corporation GmbH, Hamburg, Germany) is placed.

Subsequently, heparin is administered after exposing the common femoral artery and vein, followed by cannulation using the Seldinger method under TEE guidance. CPB with retrograde perfusion is achieved using a minimally invasive extracorporeal circulation (MiECC) system [the mini-Inspire JESSA MiECC (Sorin S.p.A., Mirandola, Italy) [11]. Ventilation is stopped after full MiECC flow.

Two additional 5-mm ports are inserted. One port in the third intercostal space is placed directly caudal to the larger access port and one in the second intercostal space at the anterior

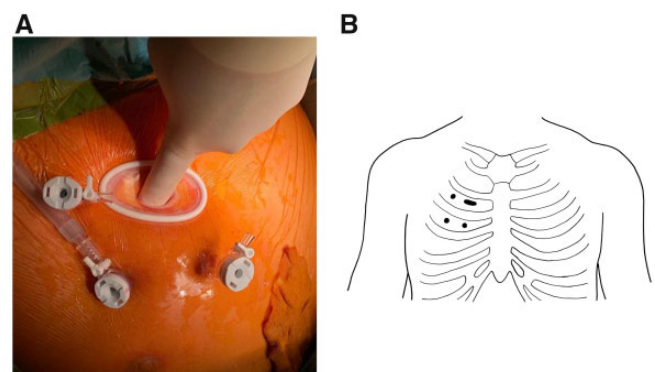


Figure 1: Operating field after installing all ports for totally endoscopic aortic valve replacement (A) and schematic drawing (B) of the trocar placement and 15- to 20-mm utility port.

axillary line, lateral to the larger access port, as illustrated in Fig. 1. From this point on, the procedure is continued totally thoracoscopically using the endoscope and the screen. The pericardium is opened laterally in a horizontal fashion at least 2 cm from the phrenic nerve to get maximum exposure to the ascending aorta. Three transthoracic pericardial traction sutures are placed. A left ventricular venting catheter (16 Fr Medtronic, Minneapolis, MN, USA) is inserted in the right superior pulmonary vein via the lateral 5-mm access point in the second intercostal space. Through this same incision, transthoracic aortic cross-clamping is obtained (Chitwood aortic clamp, GEISTER Medizintechnik GmbH, Tuttlingen, Germany), immediately followed by injection of an antegrade single shot of cold (8°C) mixed cardioplegia (blood: crystalloid 3:1, Fresenius Kabi, Schelle, Belgium) using a 14G aortic root vent (Argon Secalon-TTM, Plano, TX, USA) inserted directly in the aorta through the large access port.

After cardioplegic arrest, a transverse aortotomy is realized at the point of the cardioplegia needle, followed by 2 traction sutures. Next, complete excision of the diseased aortic valvular leaflets and the annular decalcification is performed primarily to size the aortic annulus through the large utility port with conventional sizers. Approximately 12 pledged sutures (Ethibond 2-0, Johnson & Johnson, Somerville, NJ, USA) are placed in an inverse manner in the aortic annulus, which is subsequently put through the sewing ring of the extracorporeal prosthetic valve. The prosthetic valve is then gently parachuted transversely through the working port to its annular position without the holder and secured using the Cor-Knot system (LSI Solutions, Victor, NY, USA) (Fig. 2). After determining the function of the prosthetic valve and checking the free coronary ostia, the ascending aorta is closed using a double-layered suture Prolene 4-0. Epicardial ventricular pacing wires are positioned on the right ventricle before removing the aortic cross-clamp. De-airing is achieved by the left ventricular venting catheter, which was removed only in the absence of free air on TEE. Once the patient is haemodynamically stable and TEE confirmation shows a good valve function without paravalvular leakage, weaning from CPB is initiated. In all cases,

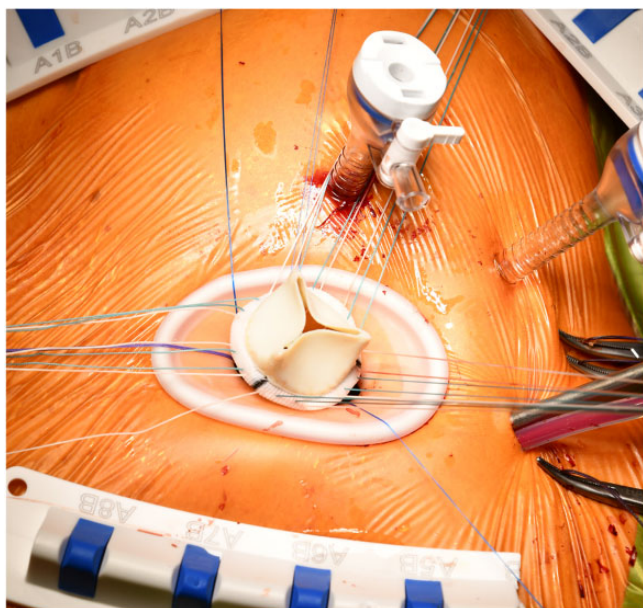


Figure 2: Introduction of a sutured valve through the 15- to 20-mm utility port.

the pericardium is approximated using Vicryl 2-0 sutures; a chest tube (Blake drain 19 Fr, Johnson & Johnson, Somerville, NJ, USA) is introduced through a trocar incision into the right pleural space. All patients are transferred to the intensive care unit postoperatively.

Outcomes

The primary objectives are the occurrence of major adverse cardiac and cerebrovascular events (MACCE) and death at 30 days, 1 year and 3 years. MACCE includes cardiac death, myocardial infarction, stroke and prosthetic degeneration. Prosthetic degeneration is defined as “intrinsic permanent changes of the prosthetic valve (i.e. calcification, leaflet fibrosis, tear or flail) leading to degeneration and/or haemodynamic dysfunction” [12]. Additionally, perioperative bleeding is defined as the amount (mL) of blood collected during the operation via suction, whereas postoperative bleeding is measured for 24 h through the thorax drains. Moreover, hospital and intensive care unit lengths of stay and complications, including surgical revisions, neurologic complications, new-onset atrial fibrillation and pacemaker implants, are secondary end points.

Data analysis

This retrospective review was performed on the data of all consecutive patients who underwent TEAVR. Data are expressed as frequencies (%), numbers (n) and median with interquartile range [p25, p75]. The survival was assessed using a Kaplan-Meier analysis for the all-cause mortality and a cumulative incidence function for MACCE. All data were analysed based on an intention-to-treat principle using the R Core Team (2021).

RESULTS

Patient demographics

A functional bicuspid aortic valve pathology was present in 61 patients (22.93%). Dyspnoea was the most common symptom (56.77%); 28.20% of the patients experienced no symptoms. The median EuroSCORE II was 1.68 [1.07,2.52] %, corresponding to low perioperative risk. Pertinent preoperative patient characteristics are given in Table 1.

Early results

TEAVR was successful in all cases except in 1 patient who needed conversion to a partial upper sternotomy. Predominantly, a biological aortic valve prosthesis (99.62%) was implanted with a valve size of 25 mm (min 21, max 29 mm). All of the implanted valves were sutured valves. The median aortic cross-clamping and CPB times were 61.0 [54.0,71.8] and 91.0 [80.0,105.0] min, respectively. The operating room time was 139.0 [122.0,161.0] min. When comparing the operating room time of the first and last 10 patients [146 (136.5,162.5) and 146.5 (133.8,161.2)], no significant difference could be detected ($P=0.91$). There was no need for a second CPB run. Other intraoperative data are presented in Table 2.

The median intensive care unit stay was 27.00 [22.00, 51.75] h, with a ventilation time of 4.00 [3.00, 6.40] h. Postoperative blood

Table 1: Preoperative patient characteristics (n = 266)

Variables	Median [IQR] or n (%)
Age (years)	72.00 [64.00, 79.00]
Male patients	168 (63.16)
BMI (kg/m ²)	27.08 [23.93, 30.08]
NYHA	
I	87 (32.71)
II	144 (54.14)
III	32 (12.03)
IV	3 (1.13)
LVEF (%)	
Good	222 (83.46)
Moderate	41 (15.41)
Poor	2 (0.75)
Very poor	1 (0.38)
EuroSCORE II (%)	1.68 [1.07, 2.52]
Hypertension	154 (57.89)
Diabetes mellitus	52 (19.55)
Hyperlipidaemia	175 (65.79)
Smoking history	
- Active	65 (24.44)
- Stop	35 (13.16)
COPD	22 (8.27)
Neurologic history	17 (6.39)
Peripheral vascular disease	9 (3.38)
Impaired renal function	18 (6.77)
Atrial fibrillation	39 (14.66)
Indication	
- AS	250 (93.98)
- AR	7 (2.63)
- AS + AR	8 (3.01)
- AS + endocarditis	1 (0.38)
Endocarditis	6 (2.26)
Bicuspid valve	61 (22.93)
Pulmonary hypertension	
- Moderate (31-55 mmHg)	27 (10.15)
- Severe (>55 mmHg)	4 (1.50)
TTE	
- Peak aortic valve gradient (mmHg)	72.0 [60.0, 86.8]
- Mean aortic valve gradient (mmHg)	46.00 [39.0, 58.0]
- Aortic valve area (cm ²)	0.8 [0.6, 0.9]

AS/AR: aortic valve stenosis/aortic valve regurgitation; BMI: body mass index; COPD: chronic obstructive pulmonary disease; EuroSCORE II: European System for Cardiac Operative Risk Evaluation; LVEF: left ventricular ejection fraction; NYHA: New York Heart Association; TTE: transthoracic echocardiography.

loss was limited to 187.50 [100.00, 338.80] ml over 24 h. A thoracoscopic re-exploration within 48 h was performed in 5 patients (1.88%) due to signs of perpetual bleeding. In 4 cases, no active bleeding was found. Also, 2 patients, 1 of which was taking novel oral anticoagulants, required revision surgery because of a tamponade. One patient developed late bleeding 1 week postoperatively, for which thoracoscopic drainage was needed.

Postoperative neurologic symptoms were observed in 14 patients (5.27%), 5 of whom were diagnosed by computed tomography (CT) or magnetic resonance imaging as a stroke. The symptoms were temporary in 1 patient, 1 died and 3 did not fully recuperate.

Additionally, 14 (5.26%) patients developed a complete atrioventricular block requiring a pacemaker to be implanted during the hospital stay. At discharge, in-hospital TTE showed mild paravalvular leakage in 1 patient. The median hospital stay was 5 [4,7] days. Pertinent postoperative outcomes are given in Table 3.

Table 2: Intraoperative outcomes (n = 266)

Variables	Median [IQR] or n (%)
CPB time (min)	91.00 [80.00, 105.00]
AoXC time (min)	61.00 [54.00, 71.80]
OR time (min)	139.00 [122.00, 161.00]
Conversion to ministernotomy	1 (0.38)
Arterial cannulation	
- Femoral artery	262 (98.50)
- Subclavian artery	6 (2.26)
Valve size (mm)	25
Mechanical (Carbomedics, LivaNova)	1 (0.38)
Bioprosthesis	
- Epic (St. Jude Medical)	178 (66.92)
- Triecta (St. Jude Medical)	69 (25.94)
- Avalor (Medtronic)	4 (1.50)
- Magna ease (Edwards Lifesciences)	9 (3.38)
- Other	5 (1.88)
Blood loss (ml)	300.00 [200.00, 500.00]
Need for blood transfusion	40 (15.04)
Inotropic agent	48 (18.05)

AoXC: aortic cross-clamp; CPB: cardiopulmonary bypass; OR: operating room.

Follow-up results

The median follow-up index was 0.69 [0.30,0.90] for a median follow-up of 679.0 [271.8,1073.8] days. Four cases of endocarditis were recorded during the follow-up period, for which 2 patients needed a reoperation (Table 4). In 2 patients, a reoperation was necessary due to tamponade and a fenestration. Early prosthetic degeneration was detected in 1 patient for which a reoperation was required.

The referring cardiologist performed a follow-up TTE of the implanted valve when a clinical indication was found. More than 50% of all patients (57.52%) received a TTE, 2 (0.75%) of which showed a mild paravalvular leakage but no structural valve deterioration (Table 4).

Major adverse cardiac and cerebrovascular events

MACCE occurred in 4 patients within 30 days (Fig. 3A). One patient died of cardiac-related issues, and 3 had a stroke. Three more patients developed MACCE over the course of a year (Fig. 3C). One suffered a cardiac-related death, whereas 2 had a stroke. During the 3-year follow-up period, 6 other patients had MACCE (Fig. 3E). One patient died of cardiac causes, and five individuals had strokes. No significant difference was noted when comparing the occurrence of MACCE at 1 year between the first and last 10 patients (0 vs 0).

All-cause mortality

Four in-hospital deaths occurred. No additional patients died within 30 days (Fig. 3B). Seven other patients died 1 year after their procedure (Fig. 3D). Fifteen more individuals died during the 3-year follow-up period (Fig. 3F). The survival rate at 30 days, 1 year and 3 years was 98.4%, 95.1% and 84.9%, respectively. No significant difference in the number of deaths at 1 year was observed in the first and last 10 patients (0 vs 0).

Table 3: Postoperative Outcomes (n = 266)

Variables	Median [IQR] or n (%)
Ventilation time (h)	4.00 [3.00, 6.40]
Ventilation <6 h	215 (80.83)
Bleeding in 24 h (ml)	187.50 [100.00, 338.80]
Need for blood transfusion	38 (14.29)
ICU LOS (h)	27 [22.00, 51.80]
Hospital LOS (days)	5 [4, 7]
Pacemaker (in hospital)	14 (5.26)
Early revision (<48 h)	
- Bleeding	5 (1.88)
- Tamponade	2 (0.75)
Late revision (>48 h)	
- Bleeding	1 (0.38)
- Tamponade	0 (0)
- Other	1 (0.38)
Neurologic	
- CVA	4 (1.50)
- TIA	1 (0.38)
- Epilepsy	3 (1.13)
New atrial fibrillation	71 (26.69)
Electrical reversion	19 (7.14)
LVEF (%)	
- Good	196 (73.68)
- Moderate	43 (16.17)
- Poor	4 (1.50)
- Very poor	0 (0)
Pulmonary hypertension	
- Moderate (31-55 mmHg)	46 (17.29)
- Severe (>55 mmHg)	0 (0)
TTE	
- Peak aortic valve gradient (mmHg)	20.00 [14.00, 26.30]
- Mean aortic valve gradient (mmHg)	11.25 [8.00, 14.30]
- Aortic valve area (cm ²)	1.82 [1.60, 2.20]
- Paravalvular leak	1 (0.38)

CVA: cerebrovascular accident; ICU: intensive care unit; IQR: interquartile range; LOS: length of stay; LVEF: left ventricular ejection fraction; TIA: transient ischaemic attack; TTE: transthoracic echocardiography.

Table 4: Follow-up (n = 262)

Variables	Median [IQR] or n (%)
Reoperation	6 (2.26)
Endocarditis	4 (1.50)
TTE	153 (57.52)
- Peak aortic valve gradient (mmHg)	19.00 [13.80, 23.00]
- Mean aortic valve gradient (mmHg)	12.00 [10.00, 13.30]
- Aortic valve area (cm ²)	2.10 [1.60, 2.20]
- Paravalvular leak	2 (0.75)

TTE: transthoracic echocardiography.

DISCUSSION

Our experience with the first 266 patients treated with TEAVR at our hospital showed good results regarding our primary outcomes. The 30-day mortality was 1.50%. At the 1-year mark, 7 other patients had passed away. Moreover, during the 3-year follow-up, 15 more patients died.

In 1.50%, 3.01% and 5.26% of patients, a MACCE occurred at 30 days, 1 year and 3 years, respectively. When comparing the

first and last 10 patients, there was no significant difference in 1-year MACCE and the number of deaths. Previous research regarding endoscopic surgery has shown a significant learning curve. Operating, aortic clamping and CPB times were longer due to a lack of experience and a lack of instruments [13, 14]. Tokoro *et al.* described operating, clamping and CPB times of 188 [56], 90 [34] and 130 [43] min, respectively [8]. Although all of the implanted valves in our series were sutured valves, which need more time to implant than sutureless valves, long aortic cross-clamping and CPB times were not seen in our first series. In our experience, the operating, clamping and CPB times were acceptable compared to those for a standard AVR by sternotomy and other endoscopic techniques [6, 8, 15]. We expect that the clamping and CPB times will be further reduced more with the use of sutureless bioprosthetic valves.

Moreover, postoperative blood loss was low, with a median of 187.50 [100.00, 338.80] ml, and 38 (14.29%) patients needed a blood transfusion. A higher postoperative blood loss of 295.0 [325.0] ml was reported by Tokoro *et al.* [8].

Nine patients (3.38%) had revision operations, which is less than half of the revisions after a median sternotomy, partial upper sternotomy and anterolateral minithoracotomy (7.3%, 6.7% and 12%, respectively) [16]. A reason for the revision might be inadequate functioning of the small (19 Fr) Blake drain, mispositioning or clot formation. A more thorough inspection of the port incisions a few minutes after protamine administration might help diminish the cases needing revisions.

New neurologic symptoms are similar to those reported in previous studies [17, 18]. Three patients had an epileptic insult, 2 of which were treated with antiepileptic agents. Moreover, strokes occurred in 5 (1.88%) patients. Stroke can occur due to general cerebral ischaemia resulting from lower cerebral perfusion pressures, lower than the patient's cut-off pressure. Retrospectively, no periods of very low pressures could be found on near-infrared spectroscopy. Additionally, stroke can be caused by emboli originating from aortic manipulation with dislocations of calcium or atheromatous plaques during an operation on the aortic valve. Another cause might be the retrograde perfusion technique [19]. However, this situation was not observed in a previous study by Stessel *et al.* [20]. CO₂ insufflation in the operative field and de-airing the left ventricle before closing the aortotomy are thus considered essential steps to diminish the occurrence of perioperative strokes. CO₂ inflation must remain at a low continuous flow level to avoid an overload of high flow air travelling to and reaching the pulmonary venous system. In such cases, emboli can be formed when ventilation is started at the end of the operation, and trapped air bubbles are demobilized. In patients enduring hemiparesis, we postulate that air embolization occurred when starting the ventilation after removing the left ventricular venting catheter. After these cases, the left ventricular vent was removed after filling the ventricle combined with ventilation until all macroscopic air bubbles disappeared. Another de-airing option might be the Valsalva manoeuvre or saline injection through the left vent or insertion of an aortic root cannula, as performed in conventional AVR surgery [21].

In-hospital pacemaker implantation was required in 14 patients (5.26%) due to a complete atrioventricular block. As seen in bicuspid valves, the extensiveness of the calcification might form another reason for an increased risk for pacemaker implantation. Almost 23% of our patients who were operated on had functional bicuspid valves. A thorough decalcification or stitches placed too deep at the perimembranous area might be

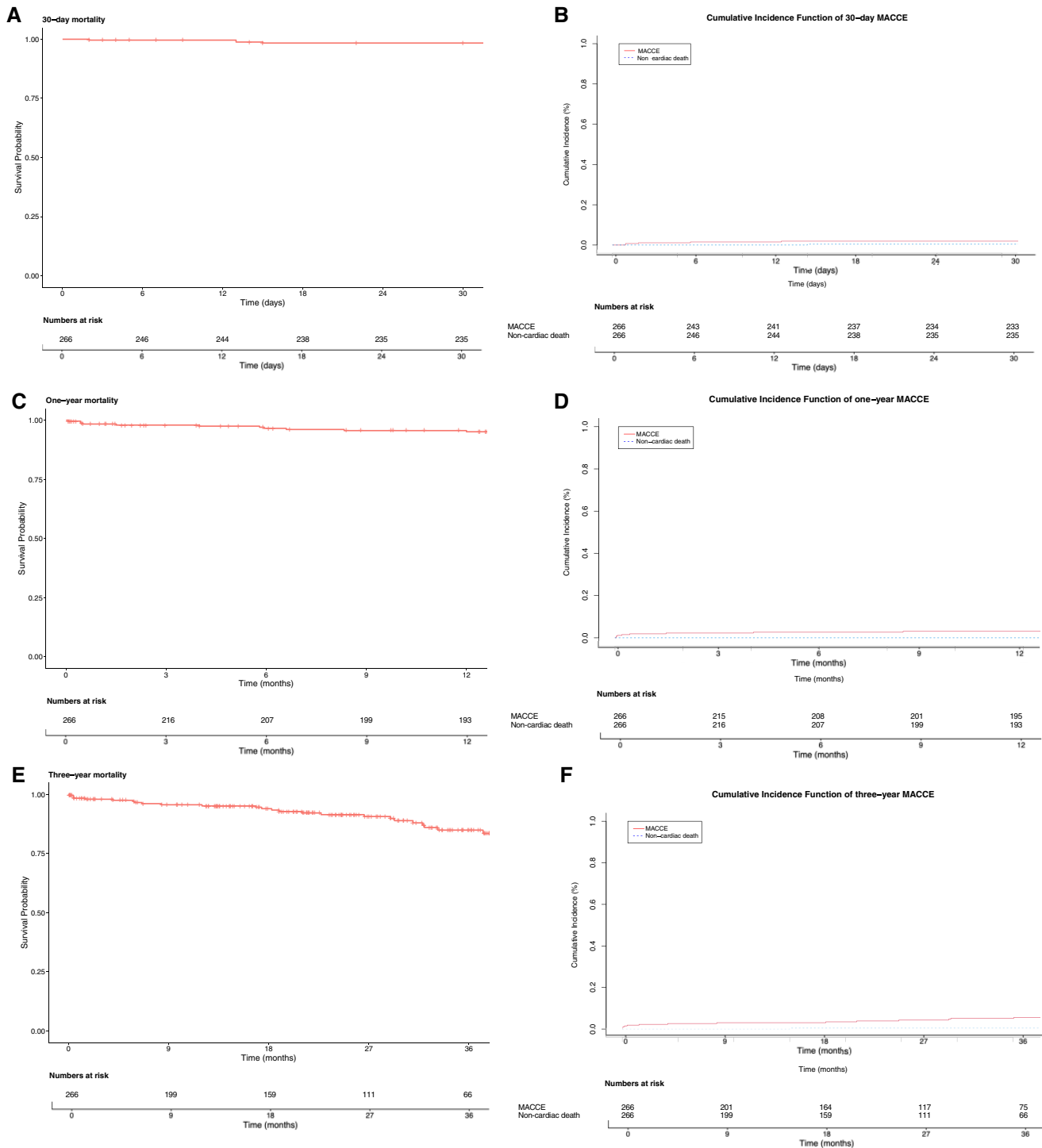


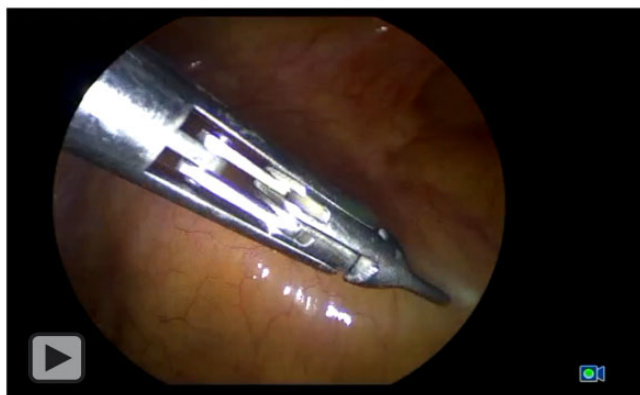Figure 3: Estimated survival of the all-cause mortality (Kaplan–Meier) and major adverse cardiac and cerebrovascular events (MACCE) (cumulative incidence function) after 30 days (**A, B**), 1 year (**C, D**) and 3 years (**E, F**).

another cause. Our reported rates can be considered acceptable when comparing our pacemaker rate (5.26%) to that of conventional AVR, where 2–7% of cases require permanent pacemaker implants [22, 23]. Moreover, the threshold of our hospital for pacemaker implants is relatively low. Compared to the results of transcatheter pacemaker implants in low-risk patients (PARTNER 3 trial), in whom pacemakers were required in 6.6% of patients, our findings are put more into perspective [24]. Furthermore, the

hospital stay was 5 [4.0, 7.0] days, in line with the 7 [2] days described by Tokoro *et al.* [8].

The difference between this technique and that of Pitsis *et al.* is the size of the working port and trocars, which are half the size in our series. Accordingly, the invasiveness of the procedure is further reduced, and the recovery is expedited [9].

An essential aspect of this experience with TEAVR is that it comprises all consecutive patients operated on by the lead



Video 1: A totally endoscopic approach for aortic valve surgery.

surgeon. We did not encounter a right anterolateral minithoracotomy or right anterior minithoracotomy, thanks to our experience with endoscopic procedures. No extra imaging such as computed tomography (CT) of the thorax was necessary to evaluate the accessibility of or indication for minimally invasive surgery as designated by Glauber *et al.* [23].

Preoperative CT scanning can lead to changes in choices concerning cannulation sites, aortic cross-clamp strategies, cardio-protection and even cancellation of surgery [25]. In contrast, when entering the chest cavity with our totally endoscopic approach, the optimal endoscopic angulation can be tailored directly to the patient's anatomy, shifts in anatomy due to single lung ventilation and position on the table. Suboptimal endoscope trocar placement can even be slightly adjusted due to the use of a 30° endoscope. Although our approach is relatively forgiving after the initial incision, we believe that global adaptation of such a technically demanding endoscopic approach relies on preoperative imaging to aid less-experienced minimally invasive operators. Once one has passed the initial learning curve, further refinement in minimizing operative strategy should include an evaluation of whether routinely preoperative CT scanning offers significant advantages to justify its radiation dose and the nephrotoxic effects of the contrast agent.

Because there are no significant incisions except the stab or minimal incisions for the trocars to reach the aorta, the use of ECC is the only real invasive factor. The disadvantages of the ECC, known for conventional systems, are minimized using our MiECC system [11, 26]. It is similar to a myocardial extracorporeal membrane oxygenation system consisting of a closed small tubing system with active draining using the oxygenator [11].

Tips and tricks

The transition from any approach under direct vision to TEAVR is a major technical change due to the transition from a 3-dimensional approach with tactile feedback to a 2-dimensional procedure without such feedback. The addition of 3-dimensional endoscopes might facilitate widespread adaptation in the cardio-surgical community to a similar extent similar to that in laparoscopic surgery [27]. Although endoscopic surgery for mitral valve repair is identical to our current technique, approaching the aortic valve poses significant challenges due to its different anatomic localization and much smaller access space and manoeuvre possibilities. The placement of the annular stitches is considered

technically demanding and could be the focus of training in a simulation model comparable to currently available simulators for mitral valve surgery [28]. Cardiac surgery residents are still primarily taught to become acquainted with technically challenging open procedures using standard instruments. The step towards a minimally invasive approach requires a different skill set. In comparison, colonic surgeons transiting from open to laparoscopic colorectal surgery took 5 to 10 years before attaining sufficient self-reported proficiency [29]. In contrast, during TEAVR, the anatomic working space is generally more confined, the heart axis may vary significantly and the right hemidiaphragm is often elevated (especially in patients who are obese), all contributing to a more technically demanding procedure. Besides these exposure-related difficulties, tissue quality in the elderly population and heavily calcified (bicuspid) valves can further complicate our proposed approach. Preplanning using CT is essential when starting a TEAVR program, but extensive experience in video-assisted thoracoscopic surgery is essential since TEAVR requires significant dexterity and dedication. We thus propose that surgeons aspiring to perform these procedures ideally begin training to learn these complex endoscopic procedures early in their residency programs and/or follow a dedicated fellowship in a specialty centre. Such a fellowship might be necessary not only to be taught TEAVR in the appropriate fashion but also to become acquainted with perioperative complications and how to manage them in the minimally invasive environment.

Limitations

This study has several limitations. It is retrospective in nature, which induces selection bias. Another limitation of this study is that most patients were followed up in other hospitals, so not all follow-up data were available. Moreover, all patients were operated on by a single surgeon, limiting the external validity of this trial. A multicentre study is necessary to prove the reproducibility of this technique.

CONCLUSION

TEAVR is a feasible technique, easily implemented in any cardio-thoracic centre without large financial investments or the need for instruments, except for an endoscopic tower system already present in all centres. Compared to robotically assisted surgery, this technique is less expensive but technically more challenging, and there is room for improvement. The development of new endoscopic instruments and surgical devices could further improve the results of this technique. Additionally, fast-track cardiac surgery, in which perioperative anaesthetic management intends to extubate the patients within 1–6 h postoperatively, could benefit patient outcomes by reducing postoperative pain and accelerating recovery.

In conclusion, a retrospective analysis of our initial experience with TEAVR in 266 consecutive patients demonstrated satisfactory results, with low mortality and acceptable morbidity rates.

Funding statement

A research grant (Grant SURG-I21-031) from Edwards Lifesciences was received to perform this study.

Conflicts of interest

Alaaddin Yilmaz, Silke Van Genechten, Jade Claessens and Abdullah Kaya have received a research grant from Edwards Lifesciences to perform this study. Loren Packlé and Jos Maessen have no conflict of interest regarding this research.

Data availability statement

The data from this article will be shared on reasonable request to the corresponding author.

Author contributions statement

Alaaddin Yilmaz: design and implementation of the research; provided critical feedback and helped shape the research, analyses, and manuscript; **Silke Van Genechten:** design and implementation of the research; took the lead in writing the manuscript; provided critical feedback and helped shape the research, analysis, and manuscript; **Jade Claessens:** collected the data; performed statistical analyses; provided critical feedback and helped shape the research, analysis, and manuscript; **Loren Packlé:** collected the data; performed statistical analyses; provided critical feedback and helped shape the research, analysis, and manuscript; **Jos Maessen:** provided critical feedback and helped shape the research, analyses, and manuscript; **Abdullah Kaya:** design and implementation of the research; provided critical feedback and helped shape the research, analysis, and manuscript.

REFERENCES

- [1] Cosgrove DM, 3rd, Sabik JF. Minimally invasive approach for aortic valve operations. *Ann Thorac Surg* 1996;62:596-7.
- [2] Van Praet KM, van Kampen A, Kofler M, Richter G, Sündermann SH, Meyer A *et al.* Minimally invasive surgical aortic valve replacement: the RALT approach. *J Card Surg* 2020;35:2341-6.
- [3] Meyer A, van Kampen A, Kiefer P, Sündermann S, Van Praet KM, Borger MA *et al.* Minithoracotomy versus full sternotomy for isolated aortic valve replacement: propensity matched data from two centers. *J Card Surg* 2021;36:97-104.
- [4] Bonacchi M, Dokollari A, Parise O, Sani G, Prifti E, Bisleri G *et al.* Ministernotomy compared with right anterior minithoracotomy for aortic valve surgery. *J Thorac Cardiovasc Surg* 2021; Apr 23: S0022-5223(21)00728-5.
- [5] Vahanian A, Beyersdorf F, Praz F, Milojevic M, Baldus S, Bauersachs J *et al.* Corrigendum to. 2021 ESC/EACTS Guidelines for the management of valvular heart disease: developed by the Task Force for the management of valvular heart disease of the European Society of Cardiology (ESC) and the European Association for Cardio-Thoracic Surgery (EACTS). *European Heart Journal* 2022;43:2022.
- [6] Vola M, Fuzellier JF, Chavent B, Duprey A. First human totally endoscopic aortic valve replacement: an early report. *J Thorac Cardiovasc Surg* 2014;147:1091-3.
- [7] Cresce GD, Sella M, Hinna Danesi T, Favaro A, Salvador L. Minimally Invasive Endoscopic Aortic Valve Replacement: operative Results. *Semin Thorac Cardiovasc Surg* 2020;32:416-23.
- [8] Tokoro M, Sawaki S, Ozeki T, Orii M, Usui A, Ito T. Totally endoscopic aortic valve replacement via an anterolateral approach using a standard prosthesis. *Interact CardioVasc Thorac Surg* 2020;30:424-30.
- [9] Pitsis A, Boudoulas H, Boudoulas KD. Operative steps of totally endoscopic aortic valve replacement. *Interact CardioVasc Thorac Surg* 2020; 31:424.
- [10] Yilmaz A, Robic B, Starinieri P, Polus F, Stinkens R, Stessel B. A new viewpoint on endoscopic CABG: technique description and clinical experience. *J Cardiol* 2020;75:614-20.
- [11] Starinieri P, Declercq PE, Robic B, Yilmaz A, Van Tornout M, Dubois J *et al.* A comparison between minimised extracorporeal circuits and conventional extracorporeal circuits in patients undergoing aortic valve surgery: is 'minimally invasive extracorporeal circulation' just low prime or closed loop perfusion? *Perfusion* 2017;32:403-8.
- [12] Capodanno D, Petronio AS, Prendergast B, Eltchaninoff H, Vahanian A, Modine T *et al.* Standardised definitions of structural deterioration and valve failure in assessing long-term durability of transcatheter and surgical aortic bioprosthetic valves: a consensus statement from the European Association of Percutaneous Cardiovascular Interventions (EAPCI) endorsed by the European Society of Cardiology (ESC) and the European Association for Cardio-Thoracic Surgery (EACTS). *Eur Heart J* 2017;38:3382-90.
- [13] Vo AT, Nguyen DH, Van Hoang S, Le KM, Nguyen TT, Nguyen VL *et al.* Learning curve in minimally invasive mitral valve surgery: a single-center experience. *J Cardiothorac Surg* 2019;14:213.
- [14] Masuda T, Nakamura Y, Ito Y, Kuroda M, Nishijima S, Okuzono Y *et al.* The learning curve of minimally invasive aortic valve replacement for aortic valve stenosis. *Gen Thorac Cardiovasc Surg* 2020;68:565-70.
- [15] Fujita B, Ensminger S, Bauer T, Möllmann H, Beckmann A, Bekeredjian R, for the GARY Executive Board *et al.* Trends in practice and outcomes from 2011 to 2015 for surgical aortic valve replacement: an update from the German Aortic Valve Registry on 42 776 patients. *European Journal of Cardio-Thoracic Surgery* 2018;53:552-9.
- [16] Semsroth S, Matteucci Gothe R, Raith YR, de Brabandere K, Hanspeter E, Kilo J *et al.* Comparison of Two Minimally Invasive Techniques and Median Sternotomy in Aortic Valve Replacement. *Ann Thorac Surg* 2017;104:877-83.
- [17] Bucarius J, Gummert JF, Borger MA, Walther T, Doll N, Onnasch JF *et al.* Stroke after cardiac surgery: a risk factor analysis of 16,184 consecutive adult patients. *Ann Thorac Surg* 2003;75:472-8.
- [18] Gaudio M, Rahouma M, Di Mauro M, Yanagawa B, Abouarab A, Demetres M *et al.* Early Versus Delayed Stroke After Cardiac Surgery: a Systematic Review and Meta-Analysis. *J Am Heart Assoc* 2019;8: e012447.
- [19] Modi P, Chitwood WR, Jr. Retrograde femoral arterial perfusion and stroke risk during minimally invasive mitral valve surgery: is there cause for concern? *Ann Cardiothorac Surg* 2013;2:E1.
- [20] Stessel B, Nijs K, Pelckmans C, Vandenbrande J, Ory JP, Yilmaz A *et al.* Neurological outcome after minimally invasive coronary artery bypass surgery (NOMICs): an observational prospective cohort study. *PLoS One* 2020;15:e0242519.
- [21] Orihashi K, Ueda T. "De-airing" in open heart surgery: report from the CVSAP nation-wide survey and literature review. *Gen Thorac Cardiovasc Surg* 2019;67:823-34.
- [22] Young Lee M, Chilakamarri Yeshwant S, Chava S, Lawrence Lustgarten D. Mechanisms of Heart Block after Transcatheter Aortic Valve Replacement - Cardiac Anatomy, Clinical Predictors and Mechanical Factors that Contribute to Permanent Pacemaker Implantation. *Arrhythm Electrophysiol Rev* 2015;4:81-5.
- [23] Glauber M, Ferrarini M, Miceli A. Minimally invasive aortic valve surgery: state of the art and future directions. *Ann Cardiothorac Surg* 2015;4: 26-32.
- [24] Mack MJ, Leon MB, Thourani VH, Makkar R, Kodali SK, Russo M *et al.* Transcatheter Aortic-Valve Replacement with a Balloon-Expandable Valve in Low-Risk Patients. *N Engl J Med* 2019;380:1695-705.
- [25] den Harder AM, de Heer LM, Meijer RC, Das M, Krestin GP, Maessen JG *et al.* Effect of computed tomography before cardiac surgery on surgical strategy, mortality and stroke. *Eur J Radiol* 2016;85:744-50.
- [26] Yilmaz A, Rehman A, Sonker U, Kloppenburg GT. Minimal access aortic valve replacement using a minimal extracorporeal circulatory system. *Ann Thorac Surg* 2009;87:720-5.
- [27] Fergo C, Burcharth J, Pommergaard H-C, Kildebro N, Rosenberg J. Three-dimensional laparoscopy vs 2-dimensional laparoscopy with high-definition technology for abdominal surgery: a systematic review. *Am J Surg* 2017;213:159-70.
- [28] Sardari Nia P, Heuts S, Daemen JHT, Olsthoorn JR, Chitwood WR, Maessen JG. The EACTS simulation-based training course for endoscopic mitral valve repair: an air-pilot training concept in action. *Interactive Cardiovascular and Thoracic Surgery* 2020;30:691-8.
- [29] Parker JM, Feldmann TF, Cologne KG. Advances in Laparoscopic Colorectal Surgery. *Surg Clin North Am* 2017;97:547-60.