



Digital mucous cysts of the finger without osteoarthritis: optimizing outcome of long needle trajectory aspiration and injection

Bert VANMIERLO^{1,2}, Bruno VANDEKERCKHOVE^{1,6}, Hannah DE HOUWER^{3,4}, Arne DECRAMER¹, Kjell VAN ROYEN^{5,6}, Jean GOUBAU^{6,7}

¹Department of Orthopaedics and Traumatology, AZ Delta, Roeselare, Belgium; ²Department of Cardio and Organ Systems, Hasselt University, Hasselt, Belgium; ³Department of Orthopaedics and Traumatology, AZ Sint-Jan AV Brugge-Oostende, Campus Brugge, Brugge, Belgium; ⁴Department of Orthopaedics, University Hospitals Leuven, Leuven, Belgium; ⁵Department of Orthopaedics and Traumatology, AZ Damiaan, Oostende, Belgium; ⁶Department of Orthopaedics and Traumatology, University Hospital Brussels, Brussel, Belgium; ⁷Department of Orthopaedics and Traumatology, AZ Maria-Middelares, Gent, Belgium.

Correspondence at: Bert Vanmierlo, Department of Orthopaedics and Traumatology, AZ Delta, Deltalaan 1, B-8800 Roeselare, Belgium, Tel: +3250694487, +32485172662, Email: Vanmierlo.bert@gmail.com; bert.vanmierlo@azdelta.be

Digital mucous cysts are common, benign and highly recurrent tumors of the distal interphalangeal joints of the fingers and often associated with osteoarthritis. Multiple treatment modalities have been described, but still no consensus is stated. In the absence of degenerative changes, we promote a novel non-surgical approach. The aim of this study was to examine all patients with digital mucous cysts without underlying osteoarthritis, undergoing this injection technique and to assess outcome and complications of this procedure. This was a single center study (2018-2019) of 17 patients who received a long needle trajectory aspiration and injection for treatment of digital mucous cysts. Exclusion criteria were prior surgical treatment, post-traumatic cyst formation and the presence of radiographic distal interphalangeal joint osteophytosis. A total of 15 patients were found eligible for inclusion. The patient reports were retrospectively analyzed with a follow-up of 6 months. The primary study outcome was resolution of the cyst; secondary outcomes were complications of the procedure. Twelve (80%) resolved completely and three (20%) had limited local recurrence at 6 months. No complications were reported. None of the patients with limited recurrence desired further treatment. We believe that this technique offers a non-invasive, low-cost treatment option for digital mucous cysts, particularly in the subset of patients with ample evidence of degenerative articular changes in the distal interphalangeal joint. The described technique can be performed in an office-based setting and avoids typical surgical as well as aspiration-associated complications.

Keywords: Mucous cysts, osteoarthritis, distal interphalangeal joint, injection, steroid.

INTRODUCTION

Digital mucous cysts (DMCs) are common, benign tumors of the fingers and toes. Typically, DMCs are located on the dorso-lateral aspect of the distal interphalangeal (DIP) joints or proximal nailfold and emerge as translucent tumors. Clinical presentation involves local pain or tenderness, decreased DIP motion, nail deformity or spontaneous rupture¹. DMCs are more frequently seen in women, particularly between the 6th and the 8th decade²⁻⁴. They were first described in 1883 by Hyde as 'synovial lesions of the skin' and, numerous attempts have been performed to characterize their clinical, histological and radiographical features ever since^{5,6}. Common synonyms are myxoid cysts, synovial cysts, mucous cysts and myxomatous cutaneous cysts. The exact mechanism of DMCs formation is not completely understood, but it is believed they result from

degenerative changes in the fibrous capsule of the joint or synovial tissue⁷. From a histological point of view, two types of DMCs have been suggested. The first type is associated with degenerative changes of the joint and the presence of osteophytes⁸. The second type is caused by fibroblasts related mucin overproduction⁵. Although the presence of a connection between the joint and cyst has been debated, dye injections into the joint could clearly illustrate the presence of this communication between joint space and cyst^{5,9}. Multiple treatment modalities have been described. Frequently performed non-surgical techniques are puncture, aspiration, and injection with a steroid or hyaluronidase, sclerotherapy, cryotherapy, infrared coagulation and laser treatment¹⁰. Surgical procedures include excision of the cyst, osteophyte debridement, overlying skin resection followed by skin grafting or local flap coverage¹¹. The importance of dorsal capsular debridement and osteophyte

excision are often considered the key to success in DMC surgery^{12,13}. However, not all authors adopt this assumption. Lawrence et al. obtained good outcomes in surgical management of DMCs without resecting overlying skin, nor osteophytes². Furthermore, not all patients with DMCs demonstrate degenerative articular changes in the DIP joint. A recent study demonstrates the presence of osteophytes in no more than 15.8% of patients presenting with DMCs¹⁴. Considering possible complications of surgery, such as joint stiffness, nail deformity, bleeding or infection, minimal invasive treatments are still being explored⁵. Since varying cure rates are objectified in non-surgical as well as surgical techniques, there is no agreement upon the best treatment of DMCs. The aim of this study was to carry out a retrospective analysis of all patients with DMCs without underlying osteoarthritis, undergoing this injection technique and to assess outcome and complications of this procedure.

MATERIALS AND METHODS

Institutional review board permission was obtained prior to the study. A total of 17 patients presented with a DMC of a long finger and were treated by long needle trajectory aspiration and injection technique. The technical optimization consists of aspiration of the cyst and subsequent injection with methyl-prednisolone after tumescent infiltration of the digit with lidocaine with adrenaline. The aspiration is performed through a remote puncture hole at the level of the proximal interphalangeal (PIP) joint and a long needle trajectory to reduce local complications. Inclusion criteria were: progressive cyst swelling with tendency to rupture, nail deformity, hypersensitivity and painful stiffening of the joint. None of the patients showed radiographic evidence of DIP joint osteoarthritis on X-ray evaluation. Exclusion criteria were prior surgical treatment, post-traumatic cyst formation and the presence of radiographic DIP joint osteophytosis. Of the 17 patients initially identified, 2 patients were excluded (one had prior surgery, another one had an underlying foreign body). A follow-up consultation took place in our outpatient clinic after six weeks and six months. Outcome measurements include clinical inspection for recurrence and registration of complications.

The patient is positioned in a supine position with the affected hand comfortably placed in a pronated position beside the body. A small pillow supports the hand and wrist and allows a slightly flexed finger position. This facilitates local anesthesia, cyst puncture and infiltration.

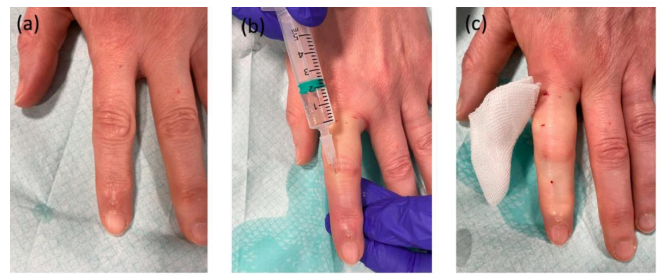


Figure 1 — (a) DMC at the DIP joint of the index finger. (b) Local anesthesia as described by Lalonde and Martin²¹. (c) Vasoconstriction, 20 minutes after administration of the local anesthetic.

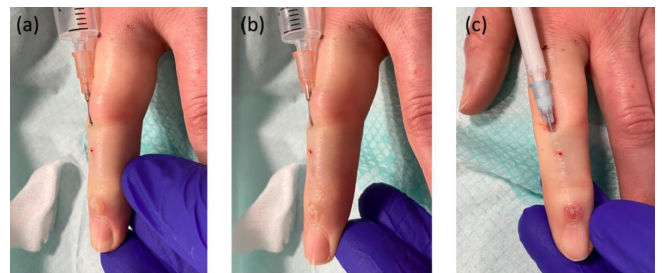


Figure 2 — (a) Antegrade puncture of the cyst through a puncture hole at the PIP joint. (b) Notice the collapse of the cyst when applying negative pressure with the syringe. (c) Injection of the cyst with cortisone, using the same needle trajectory.

Local field anesthesia is applied to the dorsum of the finger: tumescent infiltration of lidocaine plus epinephrine 1% (Xylocaine® 1% adrenaline 1:200.000, AstraZeneca, Cambridge, UK) is started at the level of the PIP joint, using small boluses and slowly advancing from proximal to distal. (Figure 1(a) and (b)).

A 20-minute interval is used to allow for optimal vasoconstrictive effect of the epinephrine (Figure 1(c)). The skin is perforated at the level of the PIP joint with a 5 ml syringe with an 18 Gauge (G) needle. The needle is then advanced in an antegrade direction until perforation of the cyst is achieved. The content of the cyst is aspirated using negative pressure (Figure 2(a)). A 21 Gauge (G) needle might be preferred as well. The larger caliber and the slightly shorter size of the latter allow for easier aspiration of the mucoid content of the cyst. A theoretical disadvantage is the increased risk for bruising and hematoma in the subcutaneous trajectory due to the larger caliber. Epinephrine-induced vasoconstriction prevents the cyst from filling with blood after removal of the needle (Figure 2(b)). Subsequently, a syringe with methylprednisolone (Depo-Medrol 40mg/ml, Pfizer, New York City, NY, USA) on a fresh 21G needle is advanced into the collapsed cyst, and 0.1ml is injected (Figure 2(c)).

A custom-made thermoplastic dorsal DIP splint is worn continuously for 2 weeks and during nighttime for another month. Since the origin of the DMC is probably located in the DIP joint, short immobilization of the joint aims to have a decrease the underlying synovitis.

RESULTS

The average age was 61 years old (range 48-71). After six weeks, twelve out of fifteen patients showed complete resolution of the cyst: a cure rate of 80% was obtained. Three patients experienced a limited local recurrence. At the six-month follow-up consultation, no changes occurred. No complications were registered at both follow-up moments: no patients mentioned pain or discomfort related to the treatment, and no skin disruption, infection or local wound problems occurred. No joint stiffness was registered. Even the three patients with a limited local recurrence were satisfied and did not seek further treatment of their DMC.

DISCUSSION

In our experience, the long needle trajectory aspiration and injection technique as described in this manuscript, offers a wide range of advantages. Like most other non-surgical treatment modalities, the technique is non-invasive, can be performed in an office-based setting and avoids surgical complications, such as joint stiffness, infection, and residual pain. Moreover, the technique is performed without burning any bridges and; a surgical procedure can still be performed in case of recurrence. Hence, some technique-specific advantages are worth mentioning. Because of the use of epinephrine, the cyst does not refill with blood after aspiration or during injection. We believe that using a longer needle trajectory through the subcutaneous tissue decreases the risk of chronic fistulation, local skin disruption and infection, since the skin is not perforated at, or around the level of the cyst. Furthermore, the application of a local anesthetic as described above, provides the advantage of hydro-dissection, and reduces the risk for hematoma and bruising. No complications were observed in our series and the recurrence rate was comparable to other non-surgical treatment modalities described in literature. According to a recent review, a surgical approach of digital mucoid cysts leads to a cure rate of 95%, compared to 77% in sclerotherapy, the highest rate in the conservative management group¹¹. A success rate of 61% after corticosteroid injection was reported in this review. Throughout literature, the

recurrence rate after corticosteroid injection ranges from 36 to 100%^{3,12,15,16}. The variability of the clinical outcome is likely the result of the variety of injection techniques that were described and the duration of the follow-up.

Upon the pathogenesis of DMCs, many hypotheses have been postulated. Degeneration of the DIP joint or the tendon sheath have been suggested as the initiators of this pathological process¹⁷. A strong association of DMCs with the presence of osteoarthritic changes of the DIP joint has been reported by several authors¹⁸⁻²⁰. Nevertheless, the relation between osteoarthritis and the occurrence of DMCs is questioned by more recent studies. Kim et al. reported radiographic evidence of osteophytes or joint degeneration in no more than 15.8% of the DMCs in middle-aged patients¹¹. In a series of Sechi et al. 53.3% of the patients were lacking osteoarthritis, and this subgroup had shown the best outcome for steroid injection therapy¹⁰. We agree upon the statement that this important subset of patients with bothersome DMCs and without radiological evidence of osteophytes, might benefit most from a non-surgical approach. Nevertheless, our patient group is small and there is no control group for comparison. Performing a randomized controlled trial comparing a surgical with a non-surgical approach in this particular subset of patients would be valuable. On the other hand, more elaborate research needs to be performed examining the relationship between the development of DMCs and the radiographic presence of osteophytes and underlying synovitis.

CONCLUSION

The long needle trajectory aspiration and injection is a safe, non-invasive, low-cost treatment option for digital mucous cysts, particularly in the subset of patients with ample evidence of degenerative articular changes in the distal interphalangeal joint. The described technique can be performed in an office-based setting and avoids typical surgical complications.

REFERENCES

1. Zuber TJ. Office management of digital mucous cysts. *American family physician*. 2001; 64(12): 1987-1990.
2. Lawrence C. Skin Excision and Osteophyte Removal Is Not Required in the Surgical Treatment of Digital Myxoid Cysts. *Arch Dermatol*. 2005;141(12):1560-1564.
3. Fritz GR, Stern PJ, Dickey M. Complications following mucous cyst excision. *J Hand Surgery*. 1997;22(2):222-225.
4. Sonnex TS. Digital myxoid cysts: a review. *Cutis*. 1986;37:89-94.
5. Miller PK, Roenigk RK, Amadio, PC. Focal mucinosis (myxoid cyst). Surgical therapy. *The Journal of dermatologic surgery and oncology*. 1992;18(8):716-719.

6. Hernández-Lugo AM, Domínguez-Cherit J, Vega-Memije, ME. Digital mucoid cyst: the ganglion type. *International journal of dermatology*. 1999; 38(7):533-535.
7. Crawford RJ, Gupta A, Risitano G, Burke FD. Mucous cyst of the distal interphalangeal joint: treatment by simple excision or excision and rotation flap. *Journal of hand surgery*. 1991;15(1):113-114.
8. Zook EG. Ganglions of the distal interphalangeal joint. In: Krull EA, Zook EG, Baran R, Haneke E, editors. *Nail surgery: a text and atlas*. Lippincott Williams & Wilkins, New York, NY. 2001;209-212.
9. De Berker DA, Lawrence CM. Treatment of myxoid cysts. *Dermatologic surgery: official publication for American Society for Dermatologic Surgery*. 2001;27(3):296-299.
10. Li K, Barankin B. Digital mucous cysts. *Journal of cutaneous medicine and surgery*. 2010;14(5):199-206.
11. Jabbour S, Kechichian E, Haber R, Tomb R, Nasr M. Management of digital mucous cysts: a systematic review and treatment algorithm. *International journal of dermatology*. 2017;56(7):701-708.
12. Rizzo M, Beckenbaugh RD. Treatment of mucous cysts of the fingers: review of 134 cases with minimum 2-year follow-up evaluation. *The Journal of hand surgery*. 2003;28(3):519-524.
13. Roulet S, Marteau E, Bacle G, Laulan J. Surgical treatment of mucous cysts by subcutaneous excision and osteophyte resection: Results in 68 cases at a mean 6.63 years' follow-up. *Chirurgie de la main*. 2015;34(4):197-200.
14. Kim EJ, Huh JW, Park HJ. Digital Mucous Cyst: A Clinical-Surgical Study. *Annals of dermatology*. 2017;29(1):69-73.
15. Pellacani G, Alessandrini A, Mandel VD, Martella A. Onychoscopy with red light for vascular pattern identification: a study of 33 patients. *Journal of the European Academy of Dermatology and Venereology*. 2019;33(12):2355-2361.
16. Sechi A, Starace M, Alessandrini A, Caposiena Caro RD, Piraccini BM. Digital Myxoid Cysts: Correlation of Initial and Long-Term Response to Steroid Injections. *Dermatologic surgery: official publication for American Society for Dermatologic Surgery*. 2021;47(5):e146-e152.
17. Drapé JL, Idy-Peretti I, Goettmann S, Salon A. MR imaging of digital mucoid cysts. *Radiology*. 2016;200(2):531-536.
18. Gaitini D. Introduction to Color Doppler Ultrasound of the Skin. In: Wortsman X, editor. *Dermatologic Ultrasound with Clinical and Histologic Correlations*. Springer, New York, NY. 2013;3-14, 21.
19. Lin YC, Wu YH, Scher RK. Nail Changes and Association of Osteoarthritis in Digital Myxoid Cyst. *Dermatol Surg*. 2008;34(3):364-369.
20. Wortsman X, Jemec G, Villani A. Ultrasound and Other Imaging Methods. In: Baran, de Berker, editors. *Baran and Dawber's Diseases of the Nails and their Management*, 5th Edition. Hoboken, NJ. 2018;162-164.
21. Lalonde D, Martin A. Epinephrine in local anesthesia in finger and hand surgery: the case for wide-awake anesthesia. *The Journal of the American Academy of Orthopaedic Surgeons*. 2013;21(8):443-447.