

# Modern Management of Unilateral Vocal Fold Paralysis: How We Do It

Olivier Peetermans<sup>1,2</sup> , Emilie Lavrysen<sup>1,2</sup> , Kristof Deben<sup>3</sup> , Sebastien Janssens de Varebeke<sup>3</sup> , Olivier Vanderveken<sup>1,2</sup> ,  
Gauthier Desuter<sup>2</sup> 

<sup>1</sup>Departments of Otorhinolaryngology and Head and Neck Surgery, University of Antwerp Faculty of Medicine and Health Sciences, Wilrijk, Belgium

<sup>2</sup>Department of Otorhinolaryngology and Head and Neck Surgery, Antwerp University Hospital, Edegem, Belgium

<sup>3</sup>Department of Otorhinolaryngology and Head and Neck Surgery, Jessa Hospital, Hasselt, Belgium

**Cite this article as:** Peetermans O, Lavrysen E, Deben K, Janssens de Varebeke S, Vanderveken O, Desuter G. Modern management of unilateral vocal fold paralysis: how we do it. B-ENT. 2023;19(4):267-273.

## ABSTRACT

The aim of this paper was to provide a concise review of modern standards in the management of unilateral vocal fold paralysis (UVFP). This article can be used as a proposal for unilateral vocal fold paralysis treatment and as a possible indication for referral to a tertiary laryngology center. Unilateral vocal fold paralysis is a common condition, mainly caused by iatrogenic, neoplastic, or idiopathic causes. The initial treatment consists of vocal therapy with or without injection laryngoplasty. If voice impairment persists, a permanent reconstruction is usually proposed, mainly consisting of an adduction thyroplasty with or without arytenoid adduction or, to a lesser extent, laryngeal reinnervation, according to the patient's wishes.

**Keywords:** Vocal cord paralysis, laryngoplasty, thyroplasty, laryngeal reinnervation, recurrent laryngeal nerve injuries

## Introduction

Unilateral vocal fold paralysis (UVFP) is defined by the European Laryngological Society as partially or fully impaired unilateral vocal cord movement due to injury to its efferent motor input at any point along the neuromuscular pathway from the central nervous system to the intrinsic laryngeal muscles.<sup>1</sup> Unilateral vocal fold paralysis is not synonymous with "vocal fold immobility," which also includes mechanical fixation of the cricoarytenoid joint due to trauma, inflammatory disease, or neoplastic involvement. The main cause of UVFP is injury to the vagus nerve (X) or its terminal branch, the recurrent laryngeal nerve (RLN), due to neoplastic, traumatic, iatrogenic, or idiopathic causes.<sup>2</sup> Unilateral vocal fold paralysis is a relatively common condition, with a postoperative incidence after thyroidectomy, for instance, of 14%, most of them being transient.<sup>3</sup> Treatment options include vocal therapy, injection laryngoplasty, adduction thyroplasty with or without arytenoid adduction, and laryngeal reinnervation.

This article summarizes modern standards in the management of UVFP. This article can be used as a suggestion for UVFP

management and as a possible tertiary laryngology center referral strategy. The management options for bilateral vocal fold palsy and vocal fold immobility due to mechanical fixation of the cricoarytenoid joint will not be discussed in this article.

## Anatomy and Neurophysiology

It is imperative to understand the neuroanatomy of the larynx (Figure 1).<sup>4</sup> The vagus nerve arises from the brainstem and descends into the neck within the carotid sheath, after exiting through the jugular foramen of the skull base. The vagus nerve gives off 2 main branches innervating the larynx: the superior laryngeal nerve (SLN) and the RLN. The SLN provides sensation above the glottis and innervates the cricothyroid muscle which provides tension and elongation of the vocal folds, modulating the pitch. The RLN descends further into the mediastinum and has a characteristic loop around the subclavian artery on the right side and the aortic arch on the left side, before ascending back up into the neck, traveling lateral to the trachea and esophagus and entering the larynx posterior to the cricothyroid joint. This rather long trajectory makes this nerve prone to injury. The RLN provides sensations below the glottis and

Emilie Lavrysen shared first co-author.

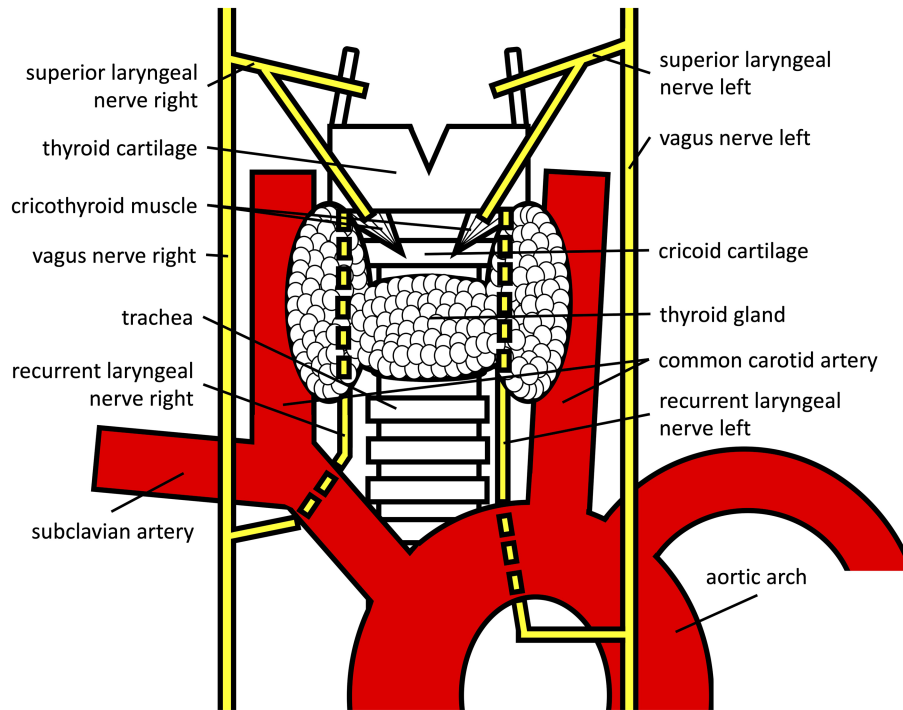
**Corresponding Author:** Olivier Peetermans, e-mail: olivierpeetermans@hotmail.com

**Received:** January 4, 2023 **Accepted:** July 3, 2023 **Publication Date:** August 7, 2023

Available online at [www.b-ent.be](http://www.b-ent.be)



CC BY 4.0: Copyright@Author(s), "Content of this journal is licensed under a Creative Commons Attribution 4.0 International License."



**Figure 1.** Anatomy of the larynx and recurrent laryngeal nerves.

innervates all remaining intrinsic laryngeal muscles, including the posterior cricoarytenoid, lateral cricoarytenoid, interarytenoid, thyroarytenoid, and aryepiglottic muscle. The posterior cricoarytenoid muscle is the sole abductor muscle of the vocal folds, whereas the other muscles all produce adduction. The main trunk of the RLN consists of 4 times more adductor motor fibers compared to abductor motor fibers, and both groups of motor fibers are randomly distributed throughout the RLN.<sup>5</sup>

Depending on the severity of RLN injury, its function may recover over the following 9 months.<sup>6</sup> Reported recovery rates of vocal fold motion vary significantly in the literature, ranging from 5% to 83%.<sup>7,8</sup> In cases of neuropraxia and mild axonotmesis, full recovery is to be expected with the recovery of vocal fold mobility and the production of normal voice. However,

more severe RLN injury including severe axonotmesis and neurotmesis will lead to either favorable aberrant reinnervation with an improved voice or unfavorable/failed reinnervation with a poor voice.<sup>9</sup> Laryngeal synkinesis indicates aberrant cross-reinnervation between the adductor and abductor RLN fibers, which may have a positive effect on voice and breathing (favorable synkinesis) or a negative effect (unfavorable synkinesis). Crumley<sup>10</sup> has proposed a functional classification of the types of laryngeal synkinesis, with the first type being favorable and the other 3 types being unfavorable: type I laryngeal synkinesis with satisfactory voice and breathing function due to a poorly mobile or immobile vocal cord in median/near-median position, type II laryngeal synkinesis with spasmodic vocal folds and unsatisfactory voice and/or breathing, type III laryngeal synkinesis with hyperadducted vocal folds and breathing compromise, type IV laryngeal synkinesis with hyperabducted vocal folds, poor voice, and aspiration risk.

In patients with UVFP without spontaneous recovery, the final position of the paralyzed vocal fold ranges from median to lateral position and determines the degree of glottal insufficiency. This final position is influenced by the degree of RLN reinnervation, laryngeal synkinesis, possible aberrant reinnervation by adjacent nerves such as autonomic nerve fibers, and/or fibrosis of the denervated laryngeal muscles.<sup>11</sup> If spontaneous reinnervation of the denervated intrinsic laryngeal muscles does not occur, either by RLN motor fiber reinnervation or by aberrant reinnervation adjacent nerve fibers, this will eventually lead to amyotrophy which further attributes to glottal insufficiency by increasing the horizontal and vertical laryngeal asymmetry.

## Evaluation

The position of the paralyzed vocal fold and thus the degree of the glottal gap evidently relates to the severity of the laryngeal dysfunction, with the main symptoms being dysphonia,

## Main Points

- Voice impairment is not a disease, and therefore, the patient should be involved in the decision-making process.
- Unilateral vocal fold paralysis (UVFP) management depends on the resultant disability experienced by the patient, the time after the onset of UVFP, the prognosis of the underlying cause, and the age and expectations of the patient.
- If there is an unsatisfactory voice improvement 3 months after the onset of UVFP, early injection laryngoplasty must be proposed to reduce the need for permanent intervention at the probabilistic term of natural recovery.
- If voice impairment persists 9 months after the onset of UVFP, an adduction thyroplasty is usually proposed, with or without arytenoid adduction.
- Laryngeal reinnervation is an alternative to adduction thyroplasty, which may be proposed according to the patient's wishes.

**Table 1. Causes of UVFP<sup>2</sup>**

Iatrogenic (surgery)	Thyroid and parathyroid gland, esophagus, thymus, lung, heart, cervical spine, skull base, neck dissection, paraganglioma, mediastinoscopy, carotid endarterectomy
Neoplastic	Lung, esophagus, breast, thyroid, metastatic lymph nodes, skull base
Central	Stroke, brainstem lesions, intracranial malformations
Traumatic	Intubation, penetrating and blunt neck trauma, birth trauma, central line
Cardiovascular	Cardiac tamponade, cor pulmonale, rheumatic heart disease
Radiation-induced	Head and neck cancer
Inflammation	Pneumoconiosis, pulmonary tuberculosis, deep neck infection, Lyme disease
Idiopathic	Believed to be of viral/vascular etiology

UVFP, unilateral vocal fold paralysis.

breathiness, dysphagia, aspiration, dyspnea, and weak cough.<sup>12</sup> Appropriate workup should start with a careful medical history, with special attention to previous surgery and intubations, trauma, and cancer history. An indirect fiberlaryngoscopy with stroboscopy should be performed, to confirm the diagnosis of UVFP, to evaluate the degree of the glottal gap, and to rule out other causes of dysphonia such as vocal fold lesions. It is useful to have the patient perform a repetitive “ee-sniff” maneuver, to alternate between maximal adduction and abduction. Some residual adduction may be present in UVFP, due to the dual innervation from both the ipsilateral and contralateral RLN of the interarytenoid muscle. If the symptoms in patients with UVFP started immediately following a surgical procedure at the level of the neck or thorax, imaging is not warranted. In other cases, computed tomography of the neck and chest is mandatory due to the high likelihood of malignancy, to evaluate the entire course of the vagus nerve and RLN. The most common causes of UVFP are iatrogenic, neoplastic, central, and traumatic.<sup>2</sup> Other less common causes are cardiovascular, radiation-induced, and inflammation. No cause can be identified in 10%–40% of patients in whom a viral or vascular etiology is hypothesized.<sup>2</sup> Additional examinations, such as brain imaging, may be considered based on the patient’s history and physical examination. The differential diagnosis of UVFP is provided in Table 1.

In-office indirect fiberlaryngoscopy alone may be inadequate to differentiate between UVFP and mechanical fixation of the cricoarytenoid joint. However, this distinction is very important, especially when laryngeal reinnervation is considered. During these instances, further workup is indicated, consisting of direct laryngoscopy and/or laryngeal electromyography (LEMG). Direct laryngoscopy is performed under deep sedation, with inspection of the interarytenoid region and cricoarytenoid joint palpation to rule out posterior glottic stenosis, arytenoid subluxation, cricoarytenoid joint ankylosis, and tumoral infiltration. LEMG can also be performed, at least 2 weeks after the onset of the voice complaints. Abnormal LEMG findings, such as fibrillations, positive sharp waves, decreased motor recruitment, and synkinesis, indicate UVFP. On the other hand, normal LEMG findings such as normal motor unit recruitment, indicate a non-neurological cause.<sup>13,14</sup>

### Management of Unilateral Vocal Fold Paralysis

The management of UVFP can be defined as “personalized care.” It will depend on the resultant disability experienced by

the patient, the time after the onset of UVFP, the prognosis of the underlying cause, and the age and expectations of the patient. As a matter of fact, specific treatment of UVFP’s etiology remains primordial (cancer treatment, ...).

This paper will only address the management of UVFP, not the treatment of the underlying etiology. It should be noted that voice impairment is not a disease. Therefore, as a physician, we have an advisory role, and the patient should be involved in the decision-making process. In addition, patients should be evaluated for aspiration, and precautions should be initiated in the minority of cases if required. Guidance on the management of UVFP is summarized in the flowchart (Figure 2). It is noted that there is no evidence of a beneficial effect of steroids.

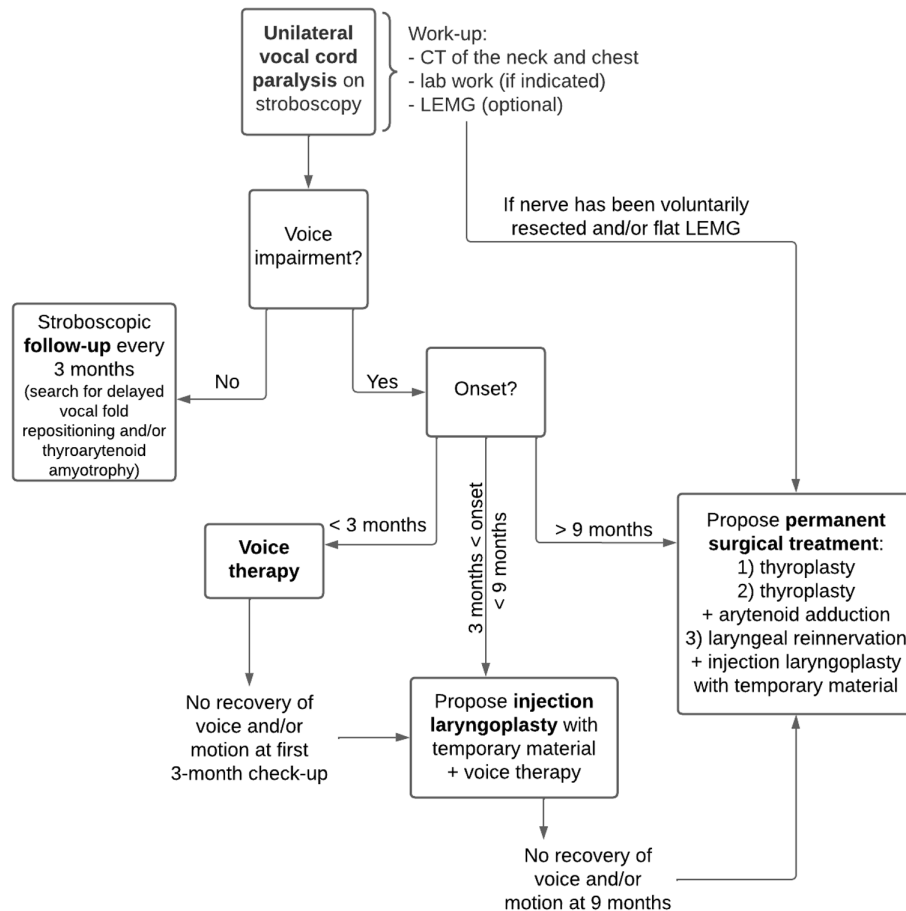
#### No Impairment

If the patient does not experience any symptoms due to adequate contralateral vocal fold compensation, a wait-and-see policy is advised. The patient should be informed about the UVFP diagnosis. We recommend doing a 3-monthly checkup during the first year, repeating the stroboscopic examination each time, to detect any delayed unfavorable vocal fold repositioning, maladaptive compensatory mechanisms, and/or thyroarytenoid amyotrophy with the creation of a subsequent glottal insufficiency. If delayed symptoms should occur, different treatment options should be considered (see later).

#### Voice Impairment and Potential for Spontaneous Recovery

The degree of nerve damage (neuropraxia—axonotmesis—neurotmesis) is usually unknown, except in some iatrogenic cases where full transection of the nerve has been visualized intraoperatively. This will ideally require immediate reconstruction (see later). It can take up to 9 months for spontaneous recovery to occur, and therefore only temporary and non-invasive treatment options are considered during these first 9 months.<sup>6</sup>

If patients experience voice impairment during the first 3 months after the onset of UVFP, voice therapy is the gold standard. The sessions are led by a trained speech and language pathologist and consist of direct voice therapy which focuses on the voice production itself, indirect voice therapy which focuses on education and vocal hygiene, and swallow therapy which focuses on swallow strength training and safety maneuvers. There is clear evidence that direct voice



**Figure 2.** Flowchart giving guidance on the management of UVFP. CT, computed tomography; LEMG, laryngeal electromyography; UVFP, unilateral vocal fold paralysis.

therapy, irrespective of the exact technique, facilitates adequate contralateral vocal fold compensation with a reduction of the glottal gap.<sup>15</sup> Of patients with UVFP treated conservatively, one-fifth to one-third will eventually develop a normal/near-normal voice despite the absence of vocal fold motion recovery.<sup>8,16</sup> We reevaluate 3 months after starting the vocal training, and if there is an unsatisfactory improvement, we propose an injection laryngoplasty with temporary material and continuation of voice therapy. If a symptomatic UVFP patient presents to our clinic, between 3 and 9 months after onset, we propose an injection laryngoplasty with temporary material from the beginning in combination with the initiation of vocal therapy.

Injection laryngoplasty is a minimally invasive procedure and can be performed transoral or percutaneous, under local or general anesthesia. If sufficient glottic closure can be achieved, injection laryngoplasty provides an immediate better voice. Moreover, it has been shown by functional neuro-imagery, that early injection can trigger a specific brainstem-mediated neuroplasticity leading to vocal fold motion recovery.<sup>17</sup> In other words, injection laryngoplasty not only provides immediate restoration of the glottic vault and a better voice but also allows a proprioceptive “boost” offering possible long-term reinnervation benefits. This could explain why an injection with a temporary material could offer long-lasting benefits largely exceeding the lifespan of the injectable.

The most used injection materials for injection laryngoplasty are hyaluronic acid, bovine gelatin, collagen-based products, autologous fat, calcium hydroxylapatite, and calcium phosphate, of which there is insufficient evidence to establish the superiority of one material over the other.<sup>18</sup> The main difference between the different materials is the time before complete resorption, ranging from a few months (short-acting materials) to a few years (long-acting materials).<sup>19</sup> In our center, we mainly use hyaluronic acid (Restylane, Hylaform) since it is a short-acting material that lasts around 6 months. A short-acting material is preferred in UVFP patients with the potential for spontaneous recovery since there are concerns that long-acting materials may adversely affect voice quality if spontaneous recovery is taking place.<sup>20</sup> If necessary, a subsequent definitive surgical procedure may be performed after 6 months without the presence of residual material (see later). Furthermore, hyaluronic acid has a proven safety profile and is easy to use with local anesthesia, posing the least amount of discomfort to the patient.<sup>20,21</sup> The complication rate of hyaluronic acid injection laryngoplasty is low, with most complications being mild such as inflammation and/or edema, which can be managed with antibiotics and steroids.<sup>22</sup> Several studies have shown that early injection laryngoplasty does not affect the reinnervation capacity of the RLN and could even reduce the need for permanent medialization thyroplasty after the 9-month waiting period.<sup>20,23</sup> Patient selection and an open discussion are paramount in the choice of approach. Office-based

injection laryngoplasty is feasible in a great deal of the UVFP patient population and should be considered first since it does not require general anesthesia and can provide real-time auditory feedback. However, in children or anxious patients, general anesthesia might be the most suitable choice for injection laryngoplasty through direct laryngoscopy.

### Voice Impairment and No Potential for Spontaneous Recovery

If voice impairment persists 9 months after the onset of UVFP, definitive surgical procedures should be considered, since spontaneous recovery after this time period is rare.<sup>6</sup> Exceptions to this rule exist: short life expectancy (patient is unable to wait for spontaneous improvement), some iatrogenic cases where the nerve has been sacrificed, and unfavorable LEMG findings. The definitive surgical procedures include medialization thyroplasty with or without arytenoid adduction and laryngeal reinnervation, each having its advantages and disadvantages (Table 2). Voice therapy is often continued postoperatively, to help patients become accustomed to their new voice.

### Thyroplasty With or Without Arytenoid Adduction

Thyroplasty comprises laryngeal framework surgery in which the main goal is the medialization of the paralyzed vocal fold. The most frequently used thyroplasty technique was coined by Isshiki<sup>24,25</sup> in 1974 and consists of the creation of a lateral window on the thyroid cartilage for the insertion of a prosthetic to adduct the paralyzed vocal fold. It is usually performed under local anesthesia and requires an external transverse incision to expose the mid-thyroid ala. Three different prosthetics can be used, titanium, Gore-tex, or silicone. When the paralyzed vocal fold is fixed in a lateral position, additional arytenoid adduction can be simultaneously performed, by suturing the muscular process of the arytenoid to the anterior part of the thyroid cartilage. By doing so, the function of the lateral cricoarytenoid muscle and the lateral thyroarytenoid muscle are simulated,

further improving the glottal insufficiency. For a demonstration movie, we refer the reader to.<sup>26</sup>

Thyroplasty offers an immediate significant voice improvement, reaching a normal to near-normal voice. Many laryngologists have raised concerns about the permanency of these results since this is a static procedure that may not prevent vocal fold atrophy over time.<sup>27</sup> However, 2 studies evaluated long-term voice results and did not show any voice deterioration over time.<sup>28,29</sup>

### Laryngeal Reinnervation

Laryngeal reinnervation is an alternative definitive surgical procedure, which restores the neural connections to the denervated laryngeal muscles. Non-selective reinnervation involves neurotomy between the main trunk of the RLN and the ansa hypoglossi, leading to the simultaneous reinnervation of both the adductor and abductor laryngeal muscles, thereby creating laryngeal synkinesis. Due to this reason, this procedure does not restore vocal fold mobility.<sup>30</sup> However, vocal fold volume and tone will be preserved, and the reinnervated vocal cords usually move to a median/near-median position due to the predominance of the laryngeal adductor muscles (favorable laryngeal synkinesis).<sup>31</sup> Complete muscle atrophy is a contraindication for reinnervation procedures in general. In UVFP, complete muscle atrophy does not always develop, presumably due to minimal (aberrant) spontaneous reinnervation.<sup>32</sup> Therefore, delayed reconstruction, even several years after UVFP onset, is often useful. A preoperative LEMG is necessary to confirm the absence of complete muscle atrophy in order to proceed to laryngeal reinnervation surgery. The main advantages include the restoration of both geometric and viscoelastic vocal fold symmetry and the possibility of performing this in children. The main disadvantages are the need for general anesthesia, and the fact that it takes up to 6 months after reinnervation has taken place. To overcome this disadvantage, an injection

**Table 2. Comparison Between 2 Definitive Surgical Procedures for UVFP**

	Thyroplasty	Laryngeal reinnervation
Complexity	Tedious because performed under sedation	Microsurgical skills
Surgical time	± 70 minutes (without arytenoid procedure)	± 120 minutes
Time to effectiveness	7 days, after withdrawal of local edema	After 6 months. Postoperative deterioration of the voice due to the shut-down of residual innervation only partially compensated with injection laryngoplasty
Type of anesthesia	Local anesthesia most of the times	General anesthesia, needs a combined injection procedure
Cost	Cost of implant, not reimbursed	Expensive surgery but reimbursed, price of the injectable
Voice rest	2 days	2 days (because of the concomitant injection laryngoplasty)
Vocal outcome	(Near-)normal voice	(Near-)normal voice
Children	Not allowed	Allowed
Other	Additional arytenoid adduction, mostly if use of Goretex or vertical discrepancy between both vocal folds	Simultaneous injection laryngoplasty is mandatory to compensate residual innervation shut-down
Complications	Hemorrhage, hematoma, wound infection, extrusion, abscess	Hemorrhage, hematoma, wound infection, failure of reinnervation

UVFP, unilateral vocal fold paralysis.



laryngoplasty with temporary material must be performed during the same procedure.

The ansa cervicalis-to-RLN reinnervation is a well-established laryngeal reinnervation technique due to its close anatomic proximity to the larynx, similar diameter to the RLN, and negligible donor morbidity. This abandoned technique was reintroduced and updated by Crumley.<sup>33</sup> Ansa cervicalis innervates most of the strap muscles and has a constant resting activity which reaches a maximum during phonation.<sup>34</sup> In 95%-98% of cases, a normal to near-normal voice can be achieved after 4 to 6 months.<sup>35-37</sup> If failure of reinnervation or insufficient voice improvement occurs, a subsequent alternative procedure such as medialization thyroplasty is still possible, due to the structural preservation of the larynx.

### Children

The same treatment protocol can be applied in children, with some minor considerations. The most frequent causes of UVFP in newborns are idiopathic, iatrogenic (patent ductus arteriosus clipping, ...), and due to birth trauma.<sup>38</sup> Intracranial malformations and neoplastic causes need to be excluded in idiopathic cases. Unilateral vocal fold paralysis in newborns may have more severe symptoms, necessitating respiratory and feeding support. Spontaneous recovery may sometimes take up to 2 years.<sup>38</sup> Early injection laryngoplasty with temporary material under general anesthesia is useful in infants. However, repeated injections in infants are avoided due to the risk of fibrosis within the yet non-differentiated multi-layer histological organization of their lamina propria. In older children, speech therapy and definitive surgical treatment may be considered. Thyroplasty in prepubescent children is not a definitive option since it requires revisions to accommodate their growing laryngeal anatomy.<sup>39,40</sup> Furthermore, it is challenging to achieve the optimal size and position of the implant since the procedure cannot be performed under local anesthesia with intraoperative voice evaluation. Laryngeal reinnervation is preferable to thyroplasty since it preserves the growing laryngeal structures and does not require the cooperativity of the child for optimal results.<sup>40,41</sup> Laryngeal reinnervation significantly improves both voice and swallowing outcomes in children as young as 2 years.<sup>40,42</sup> Therefore, laryngeal reinnervation, even long-term after the onset of vocal fold paralysis, is proposed as the first-line surgical treatment by some authors.<sup>39,40</sup>

### Conclusion

In conclusion, UVFP is a common condition that every otolaryngologist will encounter. If no obvious iatrogenic cause can be identified, neoplasia should always be ruled out. Personalized care should be offered, taking into account the resultant disability experienced by the patient, the time after the onset of UVFP, the prognosis of the underlying cause, and the age and expectations of the patient. In a good proportion of patients with UVFP, voice recovery will occur with conservative treatment, regardless of whether the vocal motion returns. If there is an unsatisfactory voice improvement after 3 months, early injection laryngoplasty must be proposed to reduce the need for permanent intervention at the probabilistic term of natural recovery. If voice impairment persists, an adduction thyroplasty is usually proposed, with or without arytenoid adduction.

Laryngeal reinnervation can also be proposed according to the patient's wishes.

**Peer-review:** Externally peer-reviewed.

**Author Contributions:** Concept – O.P., E.L., K.D., S.J., G.D.; Design – O.P., E.L., K.D., S.J., G.D.; Supervision – K.D., J.D., G.D.; Materials – O.P., E.L.; Data Collection and/or Processing – O.P., E.L.; Analysis and/or Interpretation – O.P., E.L., K.D., S.J.; Literature Search – O.P., E.L.; Writing – O.P., E.L., G.D.; Critical Review – K.D., J.D., O.V., G.D.

**Declaration of Interests:** The authors have no conflict of interest to declare.

**Funding:** The authors declared that this study has received no financial support.

### References

- Rosen CA, Mau T, Remacle M, et al. Nomenclature proposal to describe vocal fold motion impairment. *Eur Arch Otorhinolaryngol.* 2016;273(8):1995-1999. [\[CrossRef\]](#)
- Wang HW, Lu CC, Chao PZ, Lee FP. Causes of vocal fold paralysis. *Ear Nose Throat J.* 2022;101(7):NP294-NP298. [\[CrossRef\]](#)
- Joliat GR, Guarnero V, Demartines N, Schweizer V, Matter M. Recurrent laryngeal nerve injury after thyroid and parathyroid surgery: incidence and postoperative evolution assessment. *Med (Baltim).* 2017;96(17):e6674. [\[CrossRef\]](#)
- Dankbaar JW, Pameijer FA. Vocal cord paralysis: anatomy, imaging and pathology. *Insights Imaging.* 2014;5(6):743-751. [\[CrossRef\]](#)
- Zeale DL, Billante CR. Neurophysiology of vocal fold paralysis. *Otolaryngol Clin North Am.* 2004;37(1):1-23. [\[CrossRef\]](#)
- Mau T, Pan HM, Childs LF. The natural history of recoverable vocal fold paralysis: implications for kinetics of reinnervation. *Laryngoscope.* 2017;127(11):2585-2590. [\[CrossRef\]](#)
- Sulica L. The natural history of idiopathic unilateral vocal fold paralysis: evidence and problems. *Laryngoscope.* 2008;118(7):1303-1307. [\[CrossRef\]](#)
- Yung KC, Likhterov I, Courey MS. Effect of temporary vocal fold injection medialization on the rate of permanent medialization laryngoplasty in unilateral vocal fold paralysis patients. *Laryngoscope.* 2011;121(10):2191-2194. [\[CrossRef\]](#)
- Kamble N, Shukla D, Bhat D. Peripheral nerve injuries: electrophysiology for the neurosurgeon. *Neurol India.* 2019;67(6):1419-1422. [\[CrossRef\]](#)
- Crumley RL. Laryngeal synkinesis revisited. *Ann Otol Rhinol Laryngol.* 2000;109(4):365-371. [\[CrossRef\]](#)
- Schwarz K, Cielo CA, Steffen N, Jotz GP, Becker J. Voice and vocal fold position in men with unilateral vocal fold paralysis. *Braz J Otorhinolaryngol.* 2011;77(6):761-767. [\[CrossRef\]](#)
- Kuhn MA, Bloom G, Myssiorek D. Patient perspectives on dysphonia after thyroidectomy for thyroid cancer. *J Voice.* 2013;27(1):111-114. [\[CrossRef\]](#)
- Kneisz L, Volk GF, Mayr W, Leonhard M, Pototschnig C, Schneider-Stickler B. Objectivation of laryngeal electromyography (LEMG) data: turn number vs. qualitative analysis. *Eur Arch Otorhinolaryngol.* 2020;277(5):1409-1415. [\[CrossRef\]](#)
- Lin RJ, Smith LJ, Munin MC, Sridharan S, Rosen CA. Innervation status in chronic vocal fold paralysis and implications for laryngeal reinnervation. *Laryngoscope.* 2018;128(7):1628-1633. [\[CrossRef\]](#)
- Alegria R, Vaz Freitas S, Manso MC. Efficacy of speech language therapy intervention in unilateral vocal fold paralysis – a systematic review and a meta-analysis of visual-perceptual outcome measures. *Logoped Phoniatr Vocol.* 2021;46(2):86-98. [\[CrossRef\]](#)
- Young VN, Smith LJ, Rosen C. Voice outcome following acute unilateral vocal fold paralysis. *Ann Otol Rhinol Laryngol.* 2013;122(3):197-204. [\[CrossRef\]](#)

17. Dedry M, Dricot L, Van Parys V, et al. Brain adaptation following various unilateral vocal fold paralysis treatments: a magnetic resonance imaging based longitudinal case series. *Front Neurosci*. 2022;16(16):947390. [\[CrossRef\]](#)
18. Lakhani R, Fishman JM, Bleach N, Costello D, Birchall M. Alternative injectable materials for vocal fold medialisation in unilateral vocal fold paralysis. *Cochrane Database Syst Rev*. 2012;10:CD009239. [\[CrossRef\]](#)
19. Yun JM, Jung KW, Hong SD, So YK. Duration of effect and associated factors of injection laryngoplasty. *J Voice*. 2022. [\[CrossRef\]](#)
20. Švejdová A, Dršata J, Mejzlík J, et al. Injection laryngoplasty with hyaluronic acid for glottal insufficiency in unilateral vocal fold paralysis: a systematic review of the literature. *Eur Arch Otorhinolaryngol*. 2022;279(11):5071-5079. [\[CrossRef\]](#)
21. Halderman AA, Bryson PC, Benninger MS, Chota R. Safety and length of benefit of restylane for office-based injection medialization – a retrospective review of one institution's experience. *J Voice*. 2014;28(5):631-635. [\[CrossRef\]](#)
22. Courey MS, Naunheim MR. Injection laryngoplasty for management of neurological vocal fold immobility. *Adv Otorhinolaryngol*. 2020;85:68-84. [\[CrossRef\]](#)
23. Vila PM, Bhatt NK, Paniello RC. Early-injection laryngoplasty may lower risk of thyroplasty: a systematic review and meta-analysis. *Laryngoscope*. 2018;128(4):935-940. [\[CrossRef\]](#)
24. Isshiki N. Progress in laryngeal framework surgery. *Acta Otolaryngol*. 2000;120(2):120-127. [\[CrossRef\]](#)
25. Isshiki N, Okamura H, Ishikawa T. Thyroplasty type I (lateral compression) for dysphonia due to vocal cord paralysis or atrophy. *Acta Otolaryngol*. 1975;80(5-6):465-473. [\[CrossRef\]](#)
26. Desuter G. Montgomery Medialization Thyroplasty @ Pr. G. Desuter, Brussels, Belgium, Europe [Video]. Available at: YouTube – <https://www.youtube.com/watch?v=xyf8f9YCH2U&t=4s>. Published December 14, 2015. Accessed November 30, 2022.
27. Siu J, Tam S, Fung K. A comparison of outcomes in interventions for unilateral vocal fold paralysis: a systematic review. *Laryngoscope*. 2016;126(7):1616-1624. [\[CrossRef\]](#)
28. Ryu IS, Nam SY, Han MW, Choi SH, Kim SY, Roh JL. Long-term voice outcomes after thyroplasty for unilateral vocal fold paralysis. *Arch Otolaryngol Head Neck Surg*. 2012;138(4):347-351. [\[CrossRef\]](#)
29. Desuter G, Zapater E, Van der Vorst S, et al. Very long-term voice handicap index voice outcomes after montgomery thyroplasty: a cross-sectional study. *Clin Otolaryngol*. 2018;43(4):1097-1103. [\[CrossRef\]](#)
30. Fancello V, Nouraei SAR, Heathcote KJ. Role of reinnervation in the management of recurrent laryngeal nerve injury: current state and advances. *Curr Opin Otolaryngol Head Neck Surg*. 2017;25(6):480-485. [\[CrossRef\]](#)
31. van Lith-Bijl JT, Desuter GRR. Laryngeal reinnervation: the history and where we stand now. *Adv Otorhinolaryngol*. 2020;85:98-111. [\[CrossRef\]](#)
32. Fadhil M, Havas T, Jacobson I. Timing of Ansa cervicalis-to-recurrent laryngeal nerve reinnervation: a systematic review. *J Voice*. 2022; 4. [\[CrossRef\]](#)
33. Crumley RL. Update: Ansa cervicalis to recurrent laryngeal nerve anastomosis for unilateral laryngeal paralysis. *Laryngoscope*. 1991; 101(4 Pt 1):384-387. [\[CrossRef\]](#)
34. Zheng H, Li Z, Zhou S. Electromyographic study of human extrinsic laryngeal muscles. *Zhonghua Er Bi Yan Hou Ke Za Zhi*. 1995; 30(2):108-110.
35. Isseroff TF, Pitman MJ. Optimal management of acute recurrent laryngeal nerve injury during thyroidectomy. *Curr Otorhinolaryngol Rep*. 2013;1(3):163-170. [\[CrossRef\]](#)
36. Wang W, Chen D, Chen S, et al. Laryngeal reinnervation using Ansa cervicalis for thyroid surgery-related unilateral vocal fold paralysis: a long-term outcome analysis of 237 cases. *PLoS One*. 2011;6(4): e19128. [\[CrossRef\]](#)
37. Marie JP, Hansen K, Brami P, Marronnier A, Bon-Mardion N. Nonselective reinnervation as a primary or salvage treatment of unilateral vocal fold palsy. *Laryngoscope*. 2020;130(7):1756-1763. [\[CrossRef\]](#)
38. Ryan MA, Upchurch PA, Senekki-Florent P. Neonatal vocal fold paralysis. *NeoReviews*. 2020;21(5):e308-e322. [\[CrossRef\]](#)
39. Espinosa MC, Ongkasuwan J. Recurrent laryngeal nerve reinnervation: is this the standard of care for pediatric unilateral vocal cord paralysis? *Curr Opin Otolaryngol Head Neck Surg*. 2018;26(6): 431-436. [\[CrossRef\]](#)
40. Zur KB, Carroll LM. Recurrent laryngeal nerve reinnervation in children: acoustic and endoscopic characteristics pre-intervention and post-intervention. A comparison of treatment options. *Laryngoscope*. 2015;125(suppl 11):S1-S15. [\[CrossRef\]](#)
41. Hoey AW, Hall A, Butler C, Frauenfelder C, Wyatt M. Laryngeal reinnervation for paediatric vocal cord palsy: a systematic review. *Eur Arch Otorhinolaryngol*. 2022;279(12):5771-5781. [\[CrossRef\]](#)
42. Zur KB, Carroll LM. Recurrent laryngeal nerve reinnervation for management of aspiration in a subset of children. *Int J Pediatr Otorhinolaryngol*. 2018;104:104-107. [\[CrossRef\]](#)